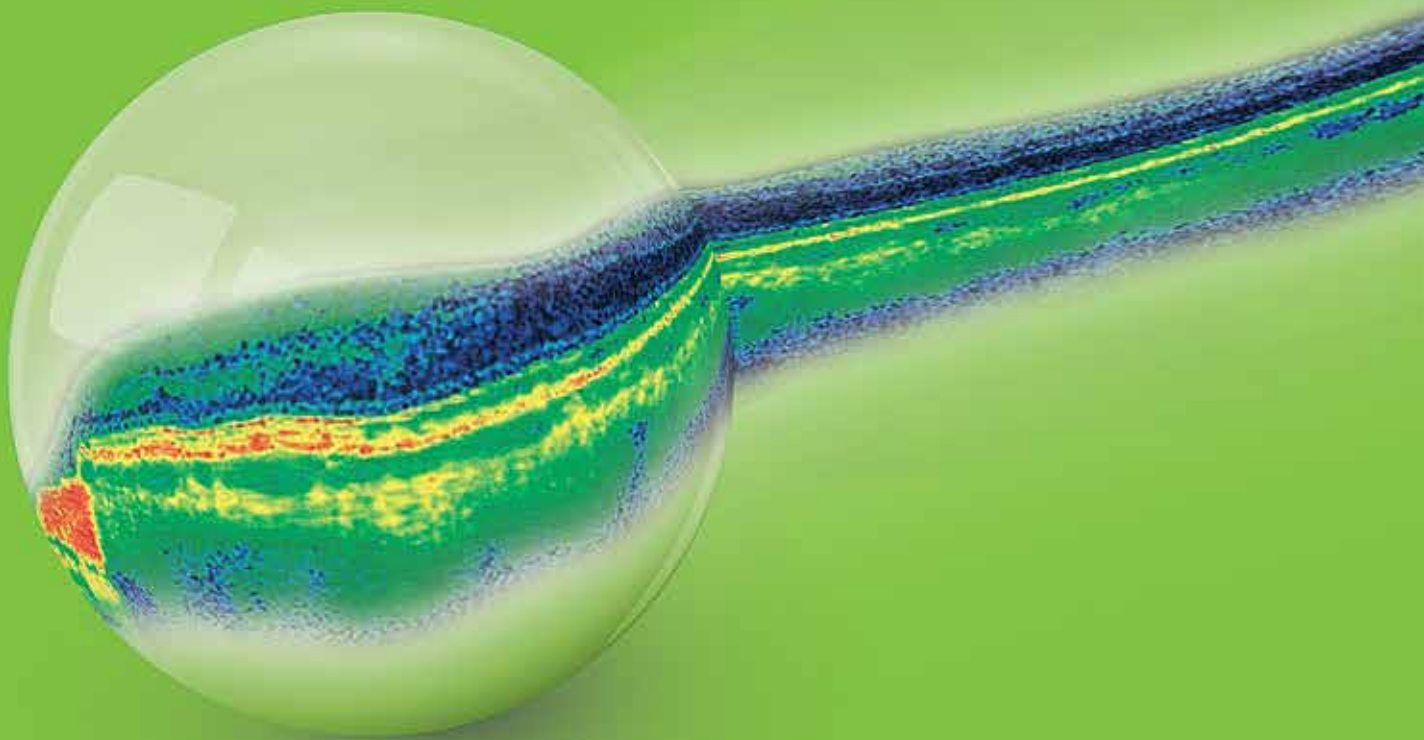


OCT & OPTIC NERVE

Pr. Jean-Philippe Nordmann

Glaucoma Centre - Hôpital des Quinze-Vingts, Paris



Edition

Published by:
Laboratoire Théa
12 rue Louis Blériot
63000 Clermont-Ferrand - France
Tel: 04 73 98 14 36

Carl Zeiss Meditec France SAS
100 route de Versailles
78160 Marly-le-Roi - France
Tel: 01 34 80 21 00

The content of this book presents the viewpoint of the author and do not necessarily reflect the opinions of Laboratoire Théa and Carl Zeiss.

Design - Production: Elwood

All rights of translation, adaptation and reproduction by any means are reserved for all countries.

Any reproduction, in whole or part, by any means whatsoever, of the pages published in this book, is prohibited and unlawful and constitutes forgery without the prior written consent of the publisher. The only reproductions allowed are, on the one hand, those strictly reserved for private use and not intended for collective use and, on the other hand, short analyses and quotations justified by the scientific or informational nature of the work into which they are incorporated (Law of 11 March 1957, art. 40 and 41, and Penal Code art. 425).

Pr. Jean-Philippe Nordmann

Centre Hospitalier National d'Ophtalmologie des Quinze-Vingts
28 rue de Charenton
75012 Paris - France

j.p.nordmann@quinze-vingts.fr

Preface

Like many complementary examinations in ophthalmology, optical coherence tomography (OCT) resulted from a collaboration between ophthalmologists and orthoptists: this book is also based on such a collaboration. I want to thank the orthoptics team of Quinze-Vingts Hospital, especially Frédérique Brion, Audrey Payeras, Cybelle Blatrix and Meddy Metref. Thanks to their efforts, I have been able to present most diseases of the optic nerve, and to compare OCT with other complementary examinations, particularly visual field assessment and photography of the optic nerve. I would also like to thank Professor Philippe Denis, President of the French Society of Ophthalmology, for his help, and in particular for providing many interesting examples.

Knowledge has no meaning unless shared, and Laboratoires Théa and Carl Zeiss have agreed to write, publish and distribute this book free of charge. I am very grateful to them.

Introduction	Page 13
Principles of OCT	Page 16
General principles	Page 18
What does OCT really show?	Page 20
Methods for analysing ocular structures with OCT	Page 22
- Optic nerve	Page 22
- Optical fibres around the papilla	Page 23
- Macular ganglion cell complex	Page 24
Sources of error with OCT	Page 26
- Signal reception errors	Page 26
- Errors related to head positioning	Page 26
- Errors related to the optics of the eye	Page 29
- Errors related to ghost images	Page 30
Presentation of results in OCT	Page 32
Cirrus™ HD-OCT (Carl Zeiss)	Page 34
- Presentation of the optic nerve head and retinal nerve fibre layer (Optic Disc Cube)	Page 34
- Presentation of the ganglion cells (macular cube)	Page 37
Optovue (RTVue)	Page 38
- Presentation of the parapapillary RNFL and the optic nerve	Page 38
- General presentation of the macular ganglion cells and parapapillary RNFL	Page 39
Glaucoma	Page 40
OCT analysis in glaucoma	Page 42
- Optic nerve	Page 42
- RNFL	Page 42
- Macular ganglion cell complex	Page 44
- Optic nerve or retinal nerve fibres: which should be examined first in glaucoma?	Page 45
- Patients with isolated optic nerve impairment	Page 46
Preperimetric glaucoma	Page 48
- Isolated impairment on OCT	Page 48
- Impairment of the RNFL and the FDT Matrix visual field	Page 50
- Impairment of the RNFL layer, macula and FDT Matrix visual field	Page 52
- Impairment of the FDT Matrix with normal OCT	Page 54

Early open-angle glaucoma	Page 56
- Depth of OCT and visual field impairment in early open-angle glaucoma	Page 58
- Predominant OCT impairment in early open-angle glaucoma	Page 60
- Primary impairment of the optic nerve without impairment of the RNFL	Page 62
- Comparison between time domain and spectral domain OCT in glaucoma with incipient open angle	Page 64
Moderate open angle glaucoma	Page 66
- Concordance of OCT findings and visual field testing	Page 66
- Predominant OCT impairment	Page 68
Advanced open angle glaucoma	Page 70
- Concordant impairment on OCT and visual field testing	Page 70
- Predominant impairment of the visual field	Page 72
- Discordance between findings on OCT and visual field testing	Page 74
Normal-pressure glaucoma	Page 76
- Isolated fascicular deficit	Page 77
- Incipient normal-pressure glaucoma	Page 78
- Moderate normal-pressure glaucoma	Page 80
Closed-angle glaucoma or sequelae of acute hypertonia	Page 82
Monitoring of open-angle glaucoma	Page 84
- Can OCT findings improve in glaucoma?	Page 87
- Comparisons between spectral domain OCT devices in glaucoma patients	Page 87
- OCT and cribriform plate analysis	Page 87
Non-glaucomatous optic neuropathies	Page 88
Multiple sclerosis	Page 91
- Acute neuropathy in MS	Page 91
- Correlations between OCT findings and visual field testing in MS	Page 92
- Location of optic neuropathy in MS	Page 93
- Important sequelae of MS neuropathy	Page 94
- Detection of subclinical MS neuropathy with OCT	Page 96
Acute optic neuropathy unrelated to MS	Page 98
Toxic optic neuropathy	Page 100
- Apparent toxic optic neuropathy without papillary impairment	Page 100
- Toxic optic neuropathy with papillary and macular impairment	Page 102
Anterior ischaemic neuropathy	Page 104
Optic neuropathy and uveopapillitis	Page 106
Papillary oedema	Page 107
- Isolated papillary oedema without retinal diffusion	Page 108

- Papillary oedema with subretinal oedema	Page 110
Optic nerve compression	Page 112
Chiasma impairment	Page 114
Amblyopia	Page 116
Perinatal impairment of the central nervous system	Page 118
Impairment of the central nervous system in adults	Page 120
Determination of the organic nature of visual impairment	Page 122
Non-ophthalmic neurodegenerative pathologies	Page 124
Atypical features of the optic nerve that can suggest optic neuropathy in OCT	Page 126
Myopia	Page 128
Papillary dysversion	Page 130
Physiological excavation	Page 132
Papillary coloboma	Page 134
Atypical features of the retina possibly suggesting optical neuropathy	Page 136
Vein occlusion sequelae	Page 138
Pigmentary retinopathy	Page 140
Conclusion	Page 143
References	Page 145

Optical Coherence Tomography (OCT) is a relatively new technique that produces images of biological tissue by measuring the reflection of light from the structure being examined. Depending on the wavelength used, the resolution is in the range of 1 to 15 μm , which is at least twice as high as can be achieved with the best conventional methods such as magnetic resonance imaging (MRI) or high-resolution ultrasonography. However, the main limitation of OCT is that it can only be used to examine structures that allow the passage of sufficient light to obtain a reflected image. The eye is clearly an ideal organ in this respect because many ocular structures, including the cornea, lens, vitreous humour, the neurosensory layer of the retina, and the anterior layers of the iris, are mainly or partially transparent. Furthermore, other highly reflective surface structures, such as the retinal pigment epithelium, can also be studied using OCT.

In 10 years, OCT has assumed a key position in diagnosis and follow-up of retinal disorders, particularly those affecting the macula. This is due to the highly informative nature of OCT images, which can provide a level of detail comparable with that of histological examination. In addition, the latest generation of OCT devices can not only reproduce this descriptive aspect, but also provide quantitative measurements of ocular structures such as the retina and its component layers.

Retinal imaging by OCT has thus emerged as a crucial technique in the investigation of glaucomatous disease, as it is now possible to quantify the thickness of the nerve fibre layer (also known as the optical fibre layer or the retinal nerve fibre layer, RNFL), which is predominantly affected in glaucoma.

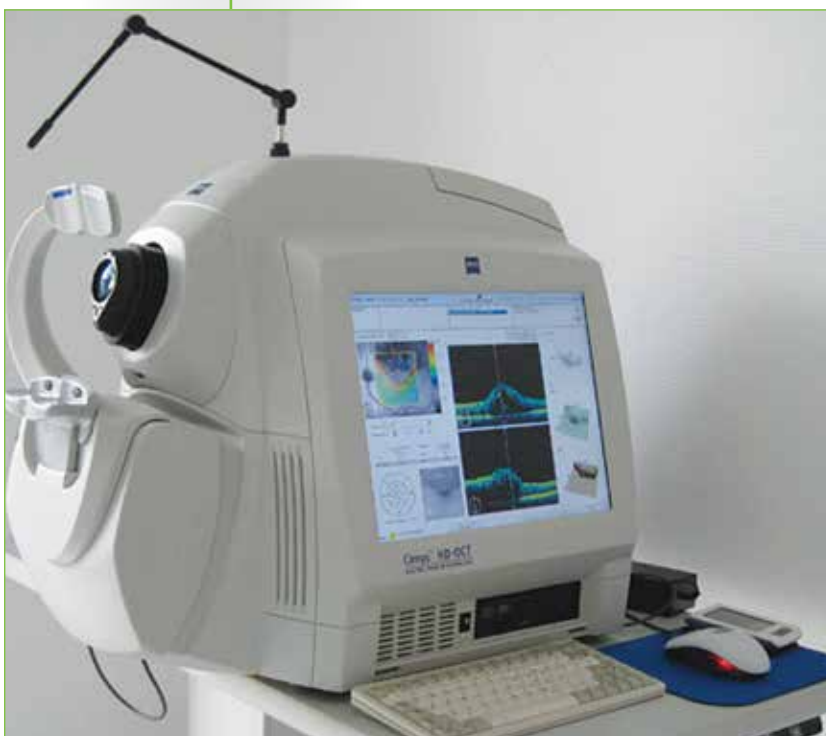This quantitative approach can also be applied to the optic nerve, allowing measurement of the area of the neuroretinal rim and cavity volume. Hence, all parts of the eye that are potentially affected in glaucoma have become accessible with OCT. By obtaining quantitative data from glaucomatous eyes, and comparing these with normal controls, the existence of glaucoma can be confirmed and the severity assessed during follow-up.

The iridocorneal angle can also be analysed, albeit less accurately because the back of the pigmented iris epithelium is inaccessible to OCT. In addition to glaucoma, OCT also appears to be useful in assessing other optic nerve diseases and, to some extent, central nervous system pathologies that affect the eye.

As with any new technology, OCT results must be interpreted with care, because data acquisition is complex and does not involve simple photography of the structures studied. It is good practice to examine the quality of the results, not only in general, but also in detail when apparently abnormal findings are obtained. Once these pitfalls have been avoided, a new field of investigation (and, above all, discussion) opens up. What is the clinical meaning of the observed pathology? How should a worsening of optical fibre pathology on OCT be interpreted if other examinations are stable? How can we explain a finding that a particular structure is no longer changing on OCT examination when clinical findings show that the glaucoma is indisputably worsening?

OCT is advancing so quickly that it is impossible to list its applications definitively: any review is certain to become obsolete quite quickly. Already indispensable for retinal analysis, OCT is now becoming essential for glaucoma and other optic neuropathies.

This monograph aims to give an update on the use of OCT in glaucoma and pathologies of the optic nerve. The first chapter covers the basic principles and interpretation of OCT and is intended to help the reader interpret OCT images. Subsequent sections cover glaucoma and other eye diseases, especially neuro-ophthalmological diseases, because these can mimic glaucoma or be a source of confusion if they are comorbid with glaucoma.



A Cirrus™ high-definition (HD)-OCT scanner (Carl Zeiss)

Figure 1

Principles of OCT

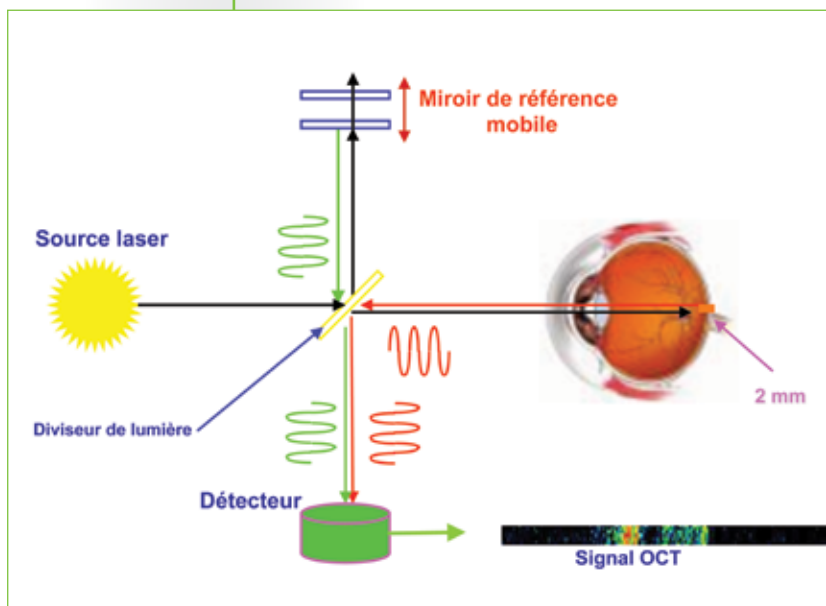
OCT works by passing a beam of laser-generated light, with a wavelength in the infrared range (approximately 840 nm), through a tissue and analysing the reflected fraction. Logically, when a beam of light passes through a structure, one part of the light will continue its path (especially if the structure is quite transparent), one part will be absorbed by the structure, one part will be reflected in all directions and the final part will be reflected towards the emission zone.

It is this last part of the light that is analysed in OCT: it corresponds to between one-billionth and one-millionth of the incident light, so it is very weak.

General principles

Sound waves propagate relatively slowly (300m/sec in air), and hence the echo time of sound waves can be recorded directly, as in ultrasonography. However, the high speed of light (300,000 km/sec) means that the time taken for incident light to be reflected back to its source is too short to measure, being approximately 30 femtoseconds (30×10^{-15} sec). OCT uses the principle of interferometry to analyse this delay. An incident wave is divided into two, one part being projected onto a plane mirror and the other onto the eye. The two waves thus created are reflected; the wave projected onto the mirror returns as a single echo, whereas the wave projected on to the eye returns as multiple echoes depending on the structures it has passed through. These waves are compared by an interferometer which measures the coherence between them (hence the term optical coherence tomography). This measurement is used to deduce the thickness of the ocular structures that the light has passed through.

A simple measurement of coherence at a given point and a given depth is called an A-scan. With time domain OCT, the mirror moves repeatedly at different depths to analyse the different layers of the retina (Figure 2).

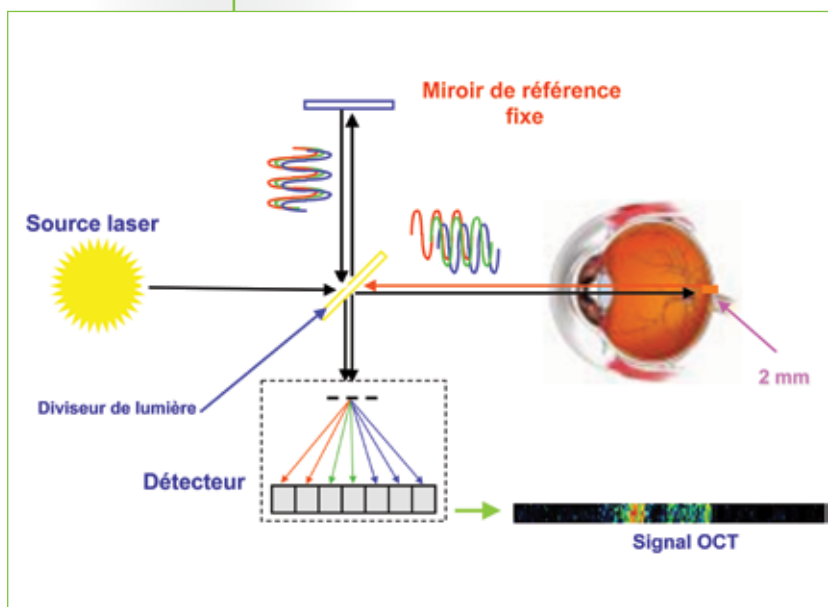


Acquisition of an A-scan: time domain OCT, in which a reference mirror moves to successively study the different depths of the retina.

Figure 2

The fastest time domain scanners can measure 17,000 A-scans per second, and these one-dimensional measurements are then combined in 2 dimensions to obtain a cross-sectional view of the retina at a given location (known as a B-scan). Time domain OCT is limited by the need for a moving mirror, because the eye has to remain relatively fixed and thus an examination cannot reasonably take more than a few seconds.

A very different technology, spectral domain OCT, dramatically improved the quality of OCT images. Instead of measuring the coherence between two waves, this approach measures the interference spectrum between the two reflected beams of broad-spectrum waves, which is analysed mathematically by Fourier transformation (Figure 3). The advantage of this “spectral/Fourier domain” technology is that rays reflected from different depths can be analysed simultaneously, rather than successively at each depth. The reference mirror therefore no longer has to move, which accelerates the process 50–100-fold.



Acquisition of an A-scan: spectral domain OCT, in which the reference mirror is fixed and the different depths of the retina are analysed at the same time.

Figure 3

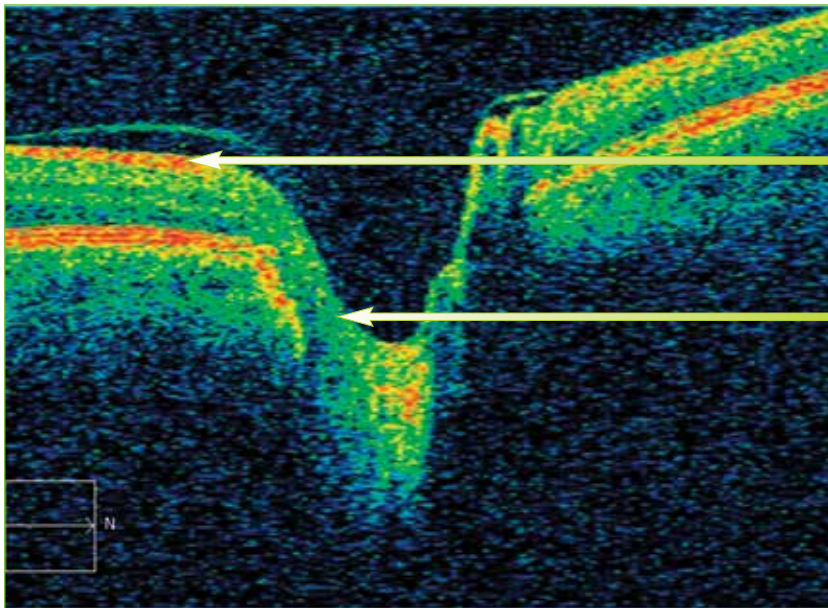
As a result, much more accurate measurements (around $2\ \mu\text{m}$) can be made during a reasonable examination time. Nevertheless, the examination is not instantaneous because, although the different depths of the retina can be studied at the same time, the laser beam still has to scan the different regions of the retina successively, and hence the quality of the results may still be affected by eye movement.

What does OCT really show?

As described above, OCT measures the reflection of light from different structures in the eye. This reflection is particularly strong when there are sharp edges between two media with different refractive indices, for example, in the cornea. Moreover, reflections are sharper when the structure under investigation is perpendicular to the incident light (rather like a reflection in a window). In general, the nature of the reflection (only a part of which is directed back towards the incident source) is determined by heterogeneous structures, such as the cell membranes, nuclei, cytoplasm, and neuronal axons, that produce small changes in the refractive index. The more reflective a structure is, the more red it appears on OCT imaging. The most reflective structures in the retina are the RNFL, the pigment epithelium and the interplexiform layers. From measurements of the reflected light, OCT measures the thickness of the structure under investigation, taking into account the return time of the incident beam and the refractive index of the structure.

In structures that contain melanin, which is a strong absorber of light, a combination of reflection and absorption results in an exponential reduction in the power of the incident beam. As a result, OCT cannot be used to study structures distal to the retinal pigment epithelium, because the outer layer is highly reflective, whereas the basal region is highly absorbent.

It is important to note that OCT images are not direct images of the retina, but rather a mathematical reconstruction that is subsequently transposed into images of the ocular fundus. This can be understood by looking at the changes in appearance of optical nerve fibres on OCT, for example, when they change direction to exit from the eye. The reflection of light from the RNFL is displayed in red, indicating that the fibres are perpendicular to the incident light, and this colour changes as the fibres change direction on moving towards the optic nerve, becoming more parallel to the incident light (Figure 4). An awareness of such changes can help in interpreting ambiguous OCT findings to determine whether or not structural changes are present.



Red areas indicate strong reflections, where the structure is perpendicular to the incident light.

Other colours indicate weaker reflections, where the structure is more parallel to the incident light.

Figure 4

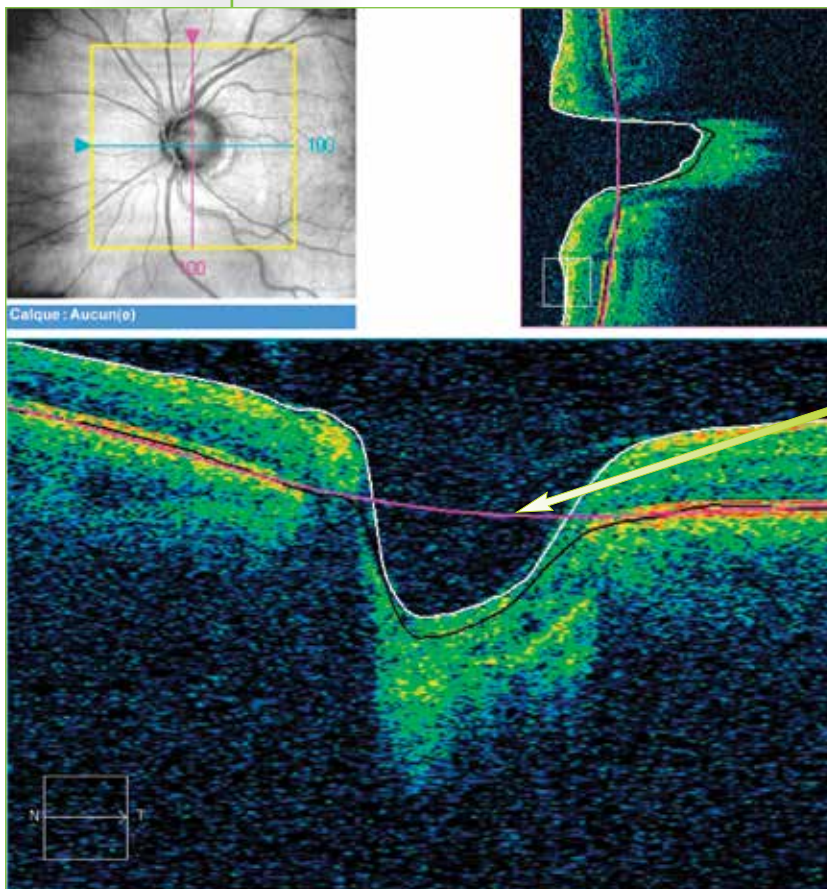
When OCT is used to analyse a layer of cells, such as the macular ganglion cell complex, it must be remembered that the measurement corresponds to the entire layer (ganglion cells, support cells, interstitial fluid, etc.) This explains why the macular ganglion cell complex does not completely disappear in patients with glaucoma, because some support cells remain even when the condition is advanced.

In this section, we shall review the use of OCT to investigate those structures that are modified in glaucoma and optic nerve pathologies: the optic nerve head, the parapapillary RNFL and the macular ganglion cell complex.

Optic nerve

The initial problem when imaging the optic nerve is how to define the contours of the optic nerve, and the start of the cavity. It is important that these are adequately defined because, when the disc is uneven, measurements may be distorted by erroneous identification of the reference plane. For OCT investigations, an arbitrary reference plane is set at 150 μm above the level of the peripapillary pigment epithelium: everything below this plane is considered to be a cavity, whether physiological or not (Figures 5 and 6). This approach allows measurement of papillary dimensions such as:

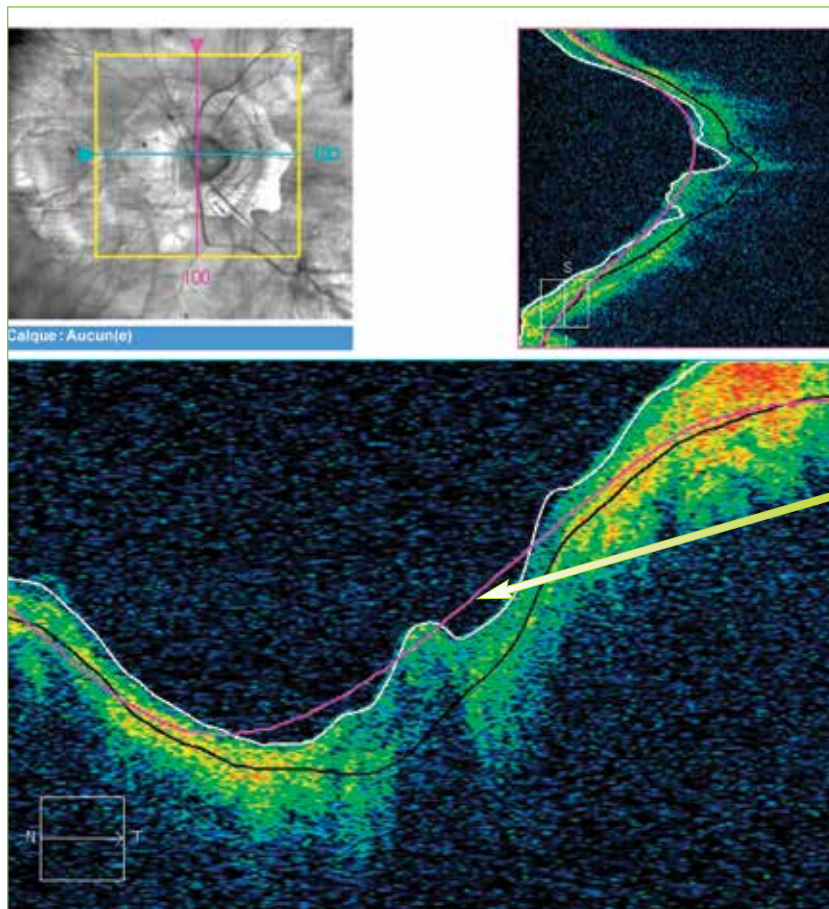
- the width and area of the neuroretinal rim at different meridians
- the size of the disc and cavity
- the cup/disc ratio.



The papillary region is even, and the pink line clearly marks the boundary between the retina and the cavity.

The normal configuration of the eye on OCT.

Figure 5



The papillary region is uneven, and the pink line does not clearly mark the boundary between the retina and the cavity.

OCT findings in an eye with severe myopia.

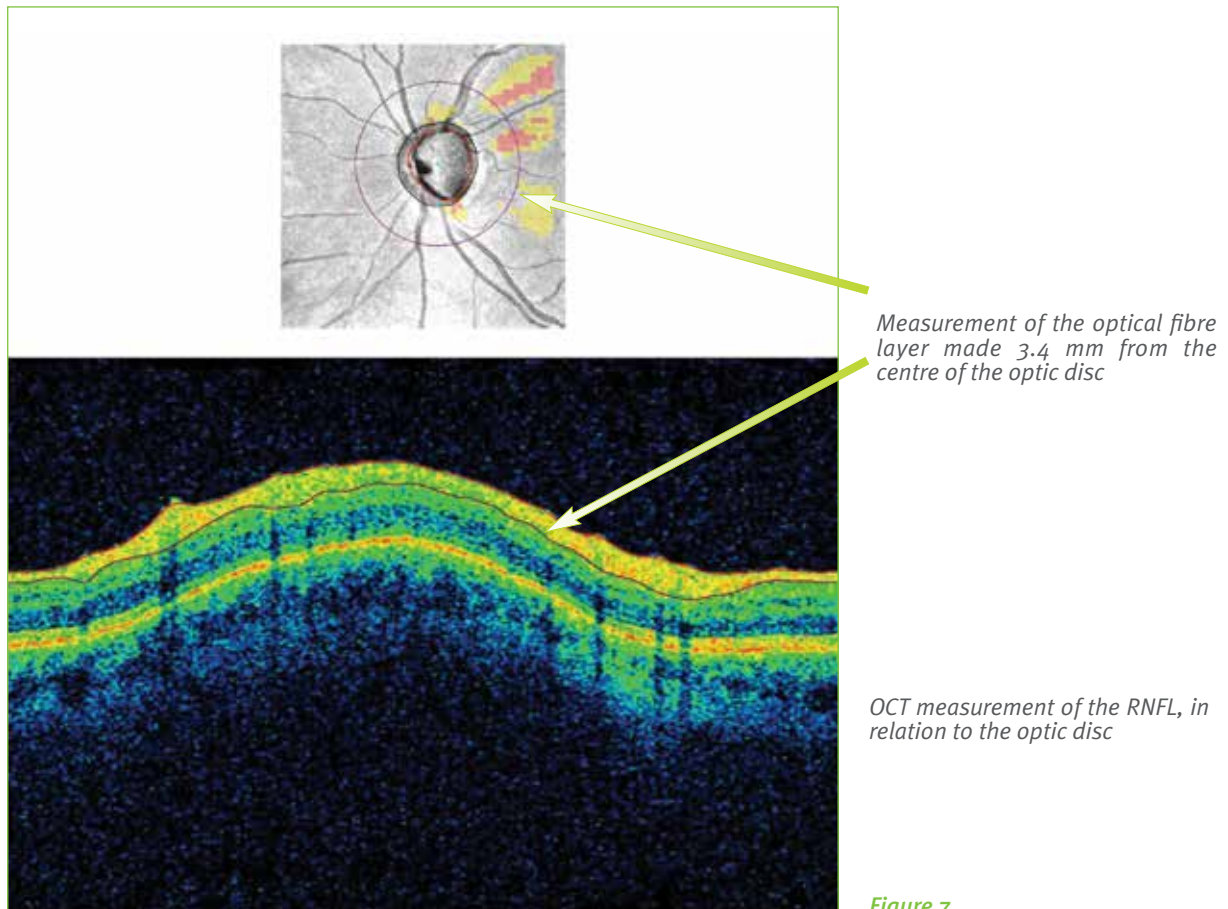
Figure 6:

Optical fibres around the papilla

OCT examination of the papillary region involves two processes:

- the two most refractive zones of the retina, the front of the RNFL and the pigment epithelium, are identified
- the point at which the reflection of the RNFL decreases sharply is determined, allowing measurement of its thickness.

The speed of the spectral domain OCT allows measurement of a cube around the optic nerve, but the zone to be imaged must be chosen with care. The thickness of the optical fibres is measured 3.4 mm from the centre of the optic disc (Figure 7). This distance was chosen because it offers the best compromise between the thickness of the RNFL and interindividual variability: the thickness of the RNFL is greatest close to the disc, and thus small changes in thickness should be readily measurable, but inter-individual variability in the location of the vessels and the shape of the disc is also greatest in this region. Conversely, measurements made further from the disc are more consistent between individuals, but the fibre layer narrows quickly and small changes become less detectable.

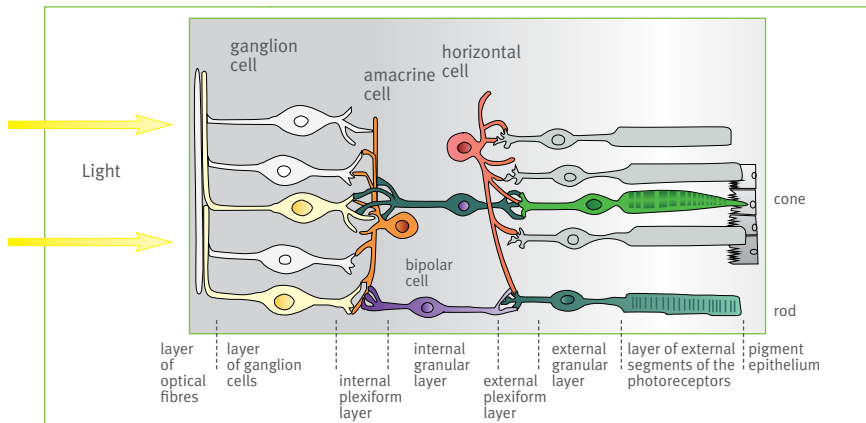


However, measurements made 3.4 mm from the centre of the disc may not reveal the first signs of disease, and hence follow-up may be sub-optimal with measurements at this point; the zones closest to the disc are likely to provide better measures of disease progression during follow-up.

Macular ganglion cell complex

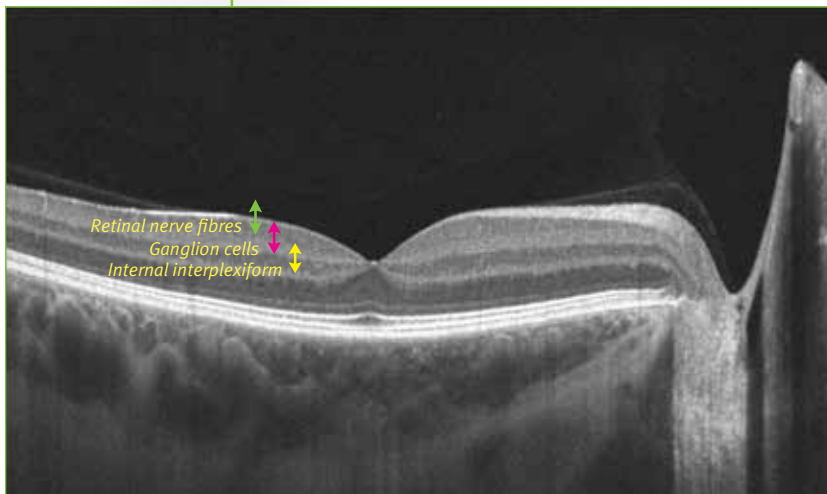
The thickness of each layer of the retina, particularly the ganglion cell layer in the macular region, can be measured using spectral domain OCT. This zone is particularly interesting because it accounts for around 30% of the entire thickness of the retina.

Conversely, the foveal region is of less interest because it contains fewer ganglion cells (Figure 8). Most OCT scanners measure across a range that includes the internal interplexiform layer, ganglion cell bodies, and ganglion cell axons passing above them (Figure 9).



Diagrammatic representation of the structure of the retina.

Figure 8



OCT image showing the three layers of the ganglion cell complex.

Figure 9

With some devices, such as the Cirrus™ HD-OCT (Carl Zeiss), the measurement can be refined to improve the location of cell damage by eliminating the ganglion cell axon layer and measuring only the internal interplexiform and ganglion cell body layers.

OCT is an objective examination, so is less prone to patient-related errors. However, it is subject to errors relating to either the imaging process or the structure of the eye.

Signal reception errors

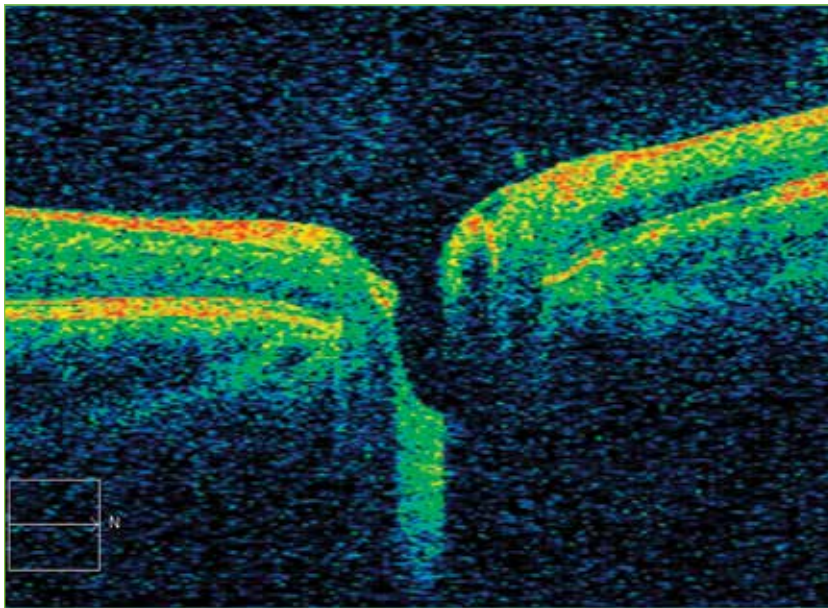
Although the quality of imaging is clearly crucial in OCT, it is not straightforward because less than one-millionth of the incident light from the laser is reflected towards the sensor. Imaging quality is expressed in terms of the signal strength, which must be greater than 6/10 with the Cirrus™ HD-OCT (Carl Zeiss) or 50 with the Optovue (RTVue). A poor signal is often responsible for underestimation of the RNFL thickness

Errors related to head positioning

As described above, the strength of the reflected light measured in OCT is dependent on small changes in the refractive index of the tissue, and the orientation of the structure under investigation relative to the incident beam. As a result, changes in the position of the head, and thus in the orientation of the axis of the eye, can lead to variable results.

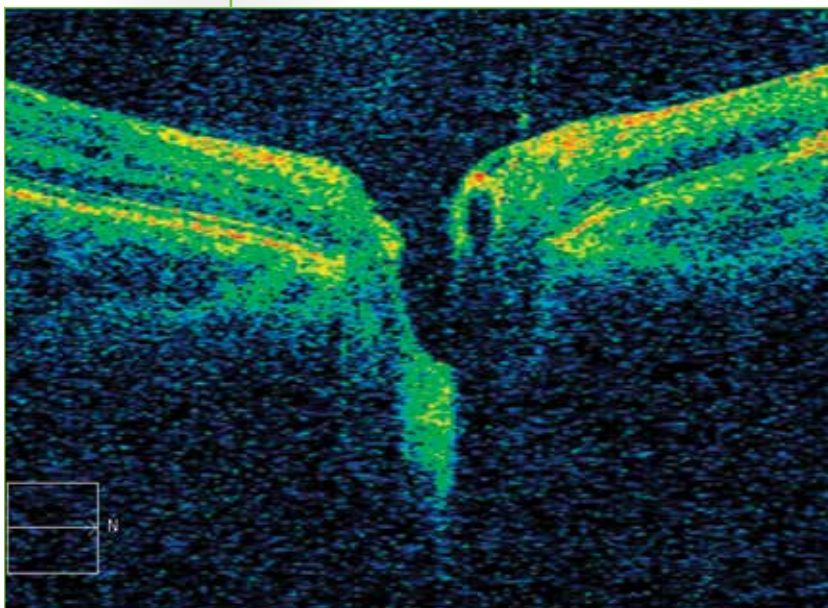
This can be seen in the example shown in Figure 10. With correct presentation, the parapapillary RNFL (in red) is thick, whereas when the depth setting is incorrect (for example, too distant, or when the head is tilted back), this layer seems to decrease steeply, and the thickness of the red layer is decreased.

However, it is important to note that such errors do not always result in inadequate signal quality, and therefore may not be easily detected.



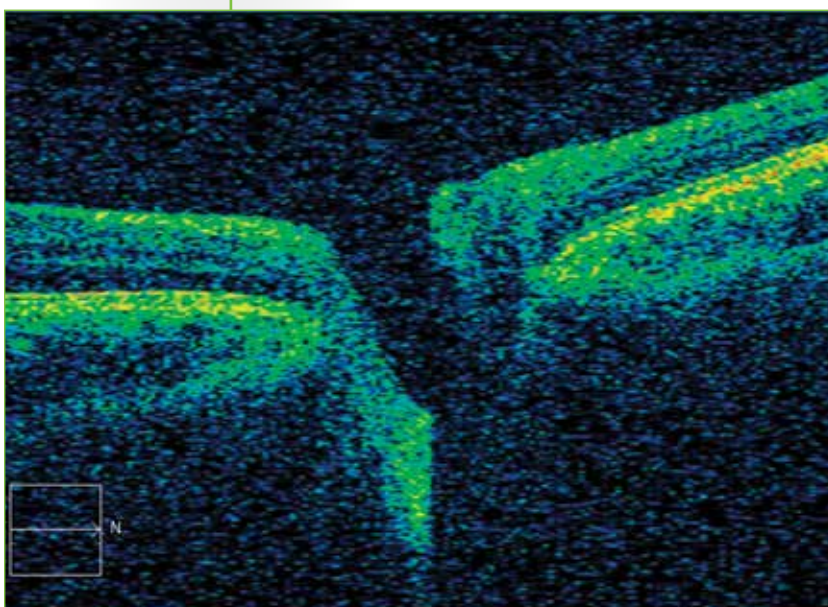
OCT image of the RNFL, with correct head positioning.

Figure 10a



OCT image from the same eye, with the head tilted back. The apparent thickness of the RNFL is reduced.

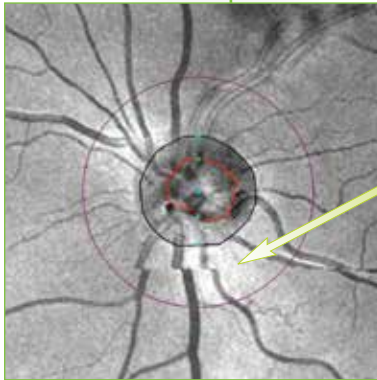
Figure 10b



OCT image from the same eye, showing poor adjustment in myopia. Again, the thickness of the RNFL is reduced.

Figure 10c

Because time domain OCT scanning takes about 1.5 s, artefacts related to eye movements may also contribute to poor quality images (Figure 11). OCT software can correct for this, or even for eye tracking during the examination, but care should nevertheless be taken to avoid such artefacts as far as possible.



Discontinuity of the image due to eye movement during examination. This can contribute to errors in the measurement of RNFL thickness.

Figure 11

Spectral domain OCT may also be subject to artefacts when the eye is incorrectly positioned (Figure 12), or when there are significant variations in retinal depth in patients with severe myopia.

The upper border of the OCT image shows an immediate reflection, and hence no weaker signals can be detected. However, if the eye is not positioned correctly, an even closer image will be detected in the mirror, which will appear completely inverted, with the outer part of the eye appearing at the top and the inner part at the bottom. In this situation, the retinal layers would also be completely inverted.

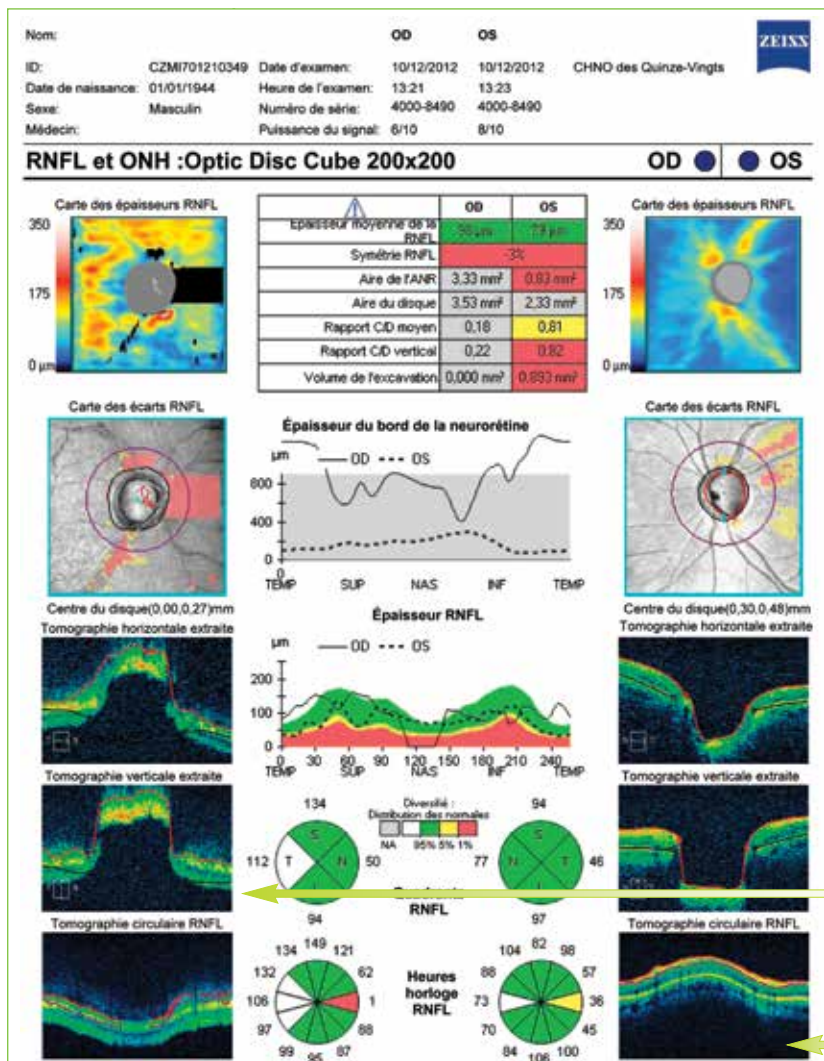


Figure 12

OCT image from a patient who was incorrectly positioned for examination of the right eye (left hand panels; long arrow). The image touches the upper part of the black frames, and all retinal structures appear inverted. The left eye is correctly positioned (right hand panels, short arrow).

Errors related to the optics of the eye

The optics of the eye may also affect the quality of OCT images. Opacification of the posterior capsule tends to reduce the apparent thickness of the RNFL¹. Conversely, the use of multifocal lenses does not affect the results at either macular or parapapillary levels². The size of the optic disc does not affect the thickness of the optical fibres unless they are very small; in this case, signs of disease may be observed irrespective of whether a genuine abnormality is present³. Conversely, myopia may reduce the apparent thickness of the optic fibre layer due to measurement errors resulting from an increased axial length. An increased axial length increases the circumference of the circle 3.4 mm from the centre of the optic nerve; as a result, the optical fibres are more dispersed than in a normal eye, leading to a reduction in apparent thickness even though there is no reduction in the number of optical fibres⁴. This phenomenon is not present to any significant degree in the macular ganglion cells, and it may therefore be preferable to measure this region in patients with severe myopia⁵.

Errors related to ghost images

OCT may not always distinguish between adjacent and highly reflective structures, such as the posterior hyaloid and the inner boundary of the retina.

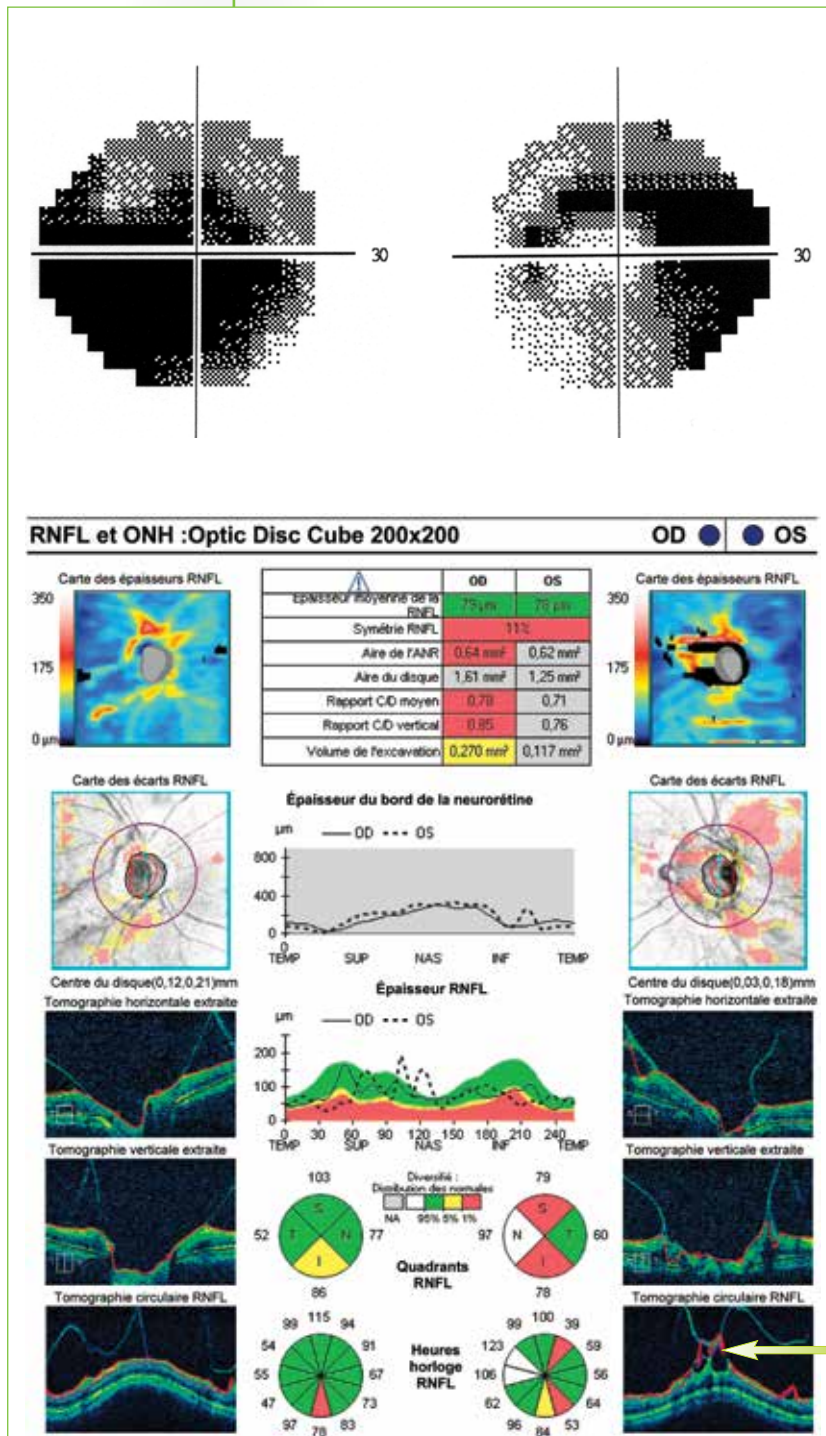


Figure 13

A further cause of potential error is that in some cases the thinning of the RNFL seen in most optic nerve pathologies is masked by structural oedema resulting from other process, such as traction phenomena (Figures 13 and 14).

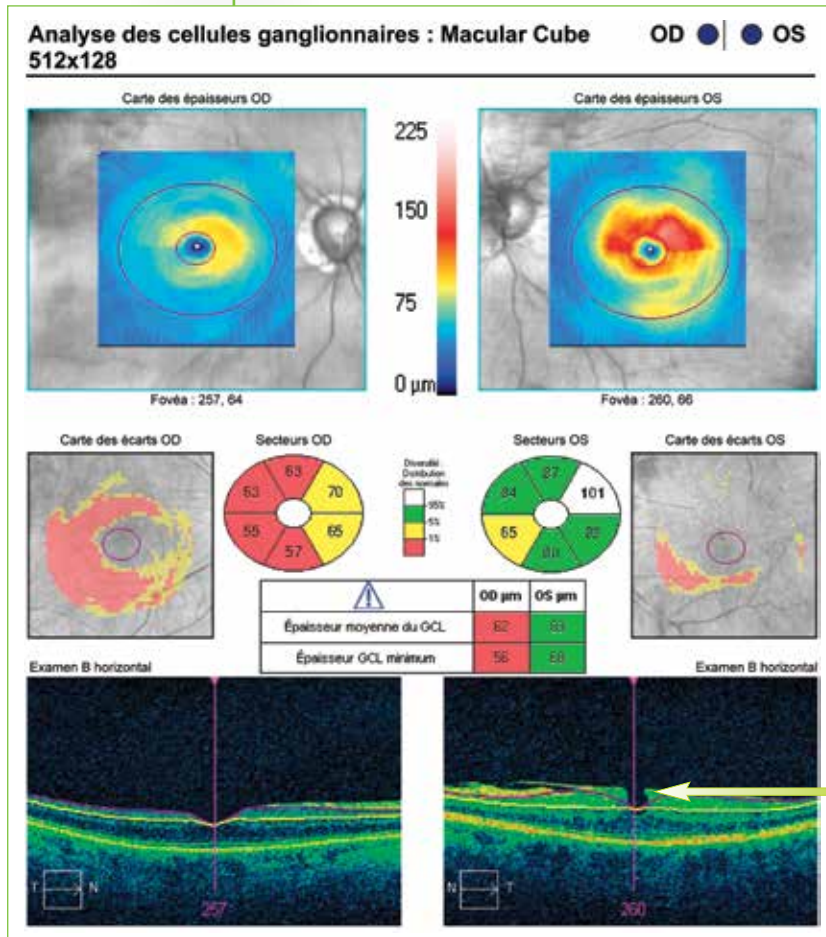


Figure 14

OCT images from a patient with bilateral glaucoma, with visual impairment skimming the central 10°. The right hand image shows damage to the ganglion cell complex (arrow), while the left hand image shows a macular hole. Traction at this level, and the resulting oedema, are masking the thinning of the RNFL, which appears to be normal.

Presentation of results in OCT

Many different OCT devices are currently available: in the United States, for example, more than 30 devices have obtained a marketing authorisation. It is therefore not possible to give a detailed review of all the available OCT devices.

In France, the most commonly used devices are the Stratus and Cirrus™ HD-OCT (Carl Zeiss), and the Optovue (RTVue), and most of the examples given in this book were obtained using these two instruments. Because the most relevant parts of the eye affected by glaucoma are the papillary and parapapillary, and the macular ganglion cell complex, OCT findings from these regions obtained with these two instruments will be reviewed in detail.

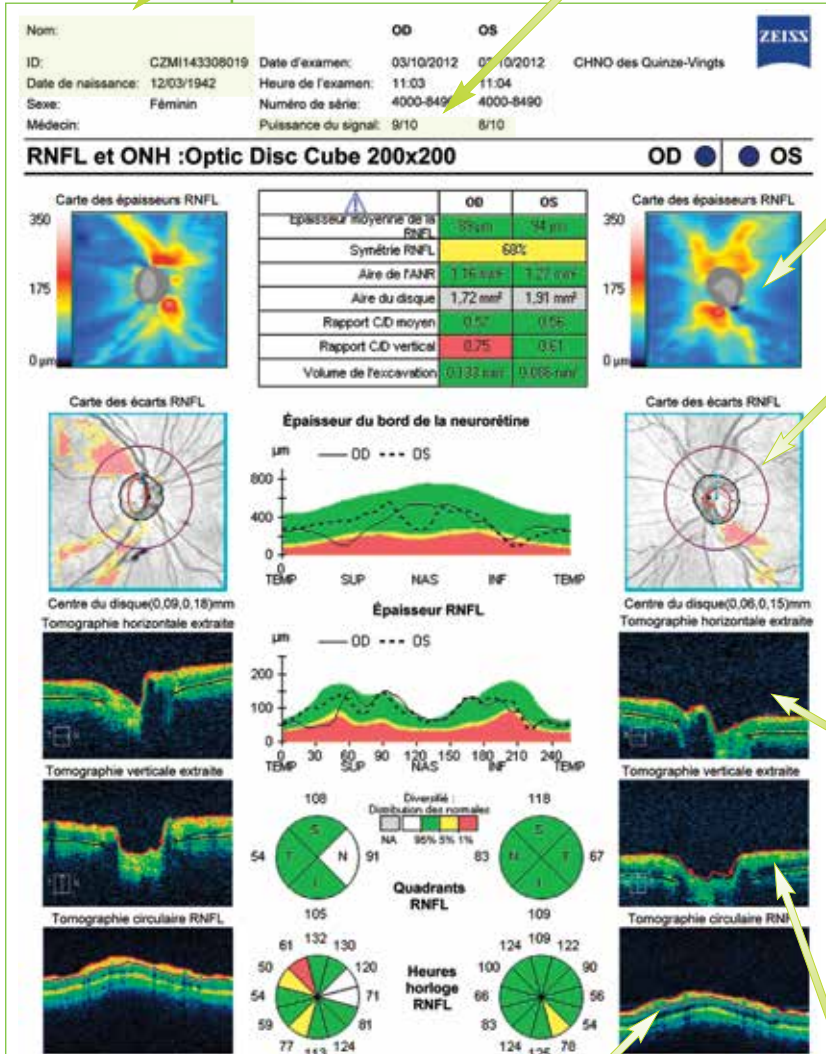
Presentation of the optic nerve head and retinal nerve fibre layer (Optic Disc Cube)

In each of the following examples (Figures 15 and 16), OCT results are presented with the right eye (OD) on the left and the left eye (OS) on the right. For statistical analyses, yellow indicates a significant anomaly at the < 5% level, and red indicates a statistical anomaly at the < 1% level. Where patterns are small and difficult to analyse, these will be enlarged on a separate page.

The values obtained are compared with those of a patient of the same age with an optic disc of the same size. The size limits of the optic disc range from 1.3 mm² to 2.5 mm²; outside these limits, all measured parameters are shown in grey, because they are not compared to a standard. For each value, this number appears on a white background if it is 5% of the best values, and on a green background for 90% of cases.

Patient's full name. The patient's date of birth is important because the results are compared with age-dependent standards.

Signal strength: an indication that the results have been correctly acquired. Values higher than 6/10 are required. However, even if the signal is strong, the results may be inaccurate if the eye is incorrectly positioned.



Thickness of the optical fibre layer. Warmer colours indicate thicker layers. A "clock hands" appearance, centred on the disc, is normal.

Image of the ocular fundus in which the statistical values of anomalies in the optical fibre are coloured (yellow: $p < 0.05$; red: $p < 0.01$). The optic disc is indicated, as well as the zone 3.4 mm from the centre of the disc where the thickness of parapapillary nerve fibres is measured. It is important that this circle is not located in a zone of peripapillary atrophy, because the reflectance of the pigment epithelium would be evaluated incorrectly and the results potentially distorted.

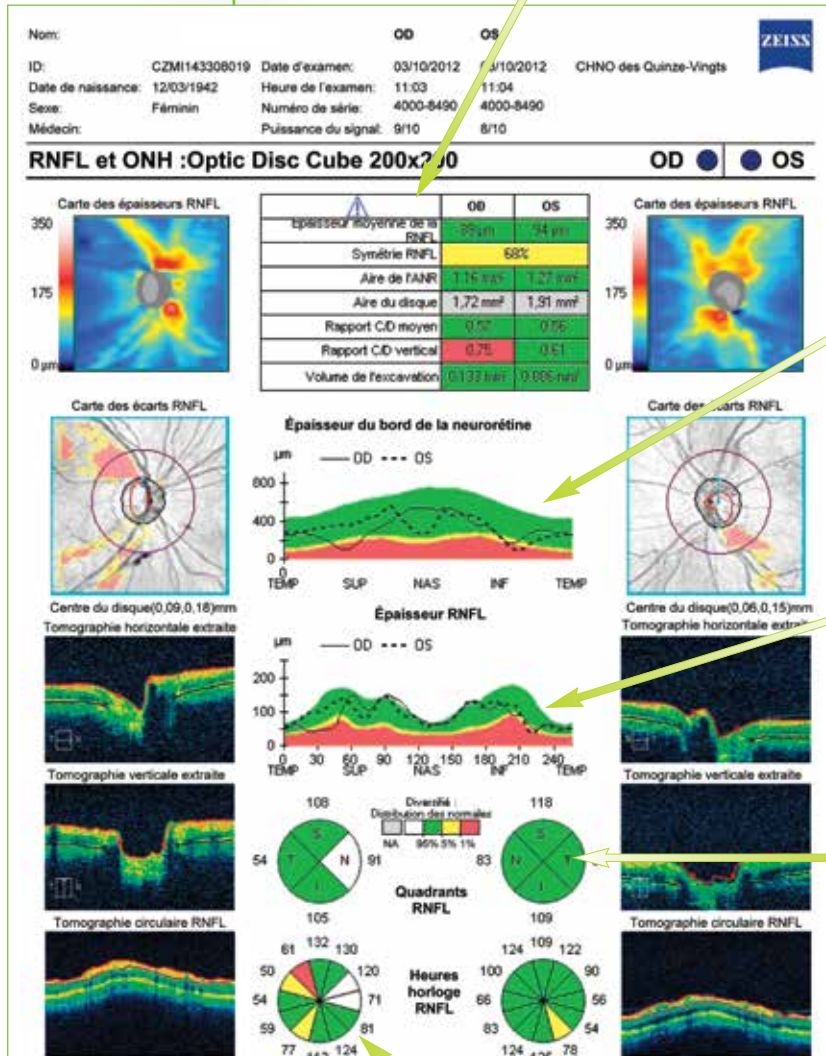
Horizontal section of the posterior pole. It is important to ensure that the retina does not touch the upper part of the square, as this would distort the results. The reflectance of the different layers are shown, as well as the boundaries of the retina and Bruch's membrane. Two small dots indicate a zone 150 µm above Bruch's membrane that defines the start of the cavity.

Position of the retina 3.4 mm from the optical centre, corresponding to the region where the retinal nerve fibres are studied.

Vertical section of the posterior pole. Imaged elements are identical to the horizontal section.

Figure 15

Average thickness of the optical fibre layer (RNFL);
 Symmetry of this layer between the 2 eyes (RNFL Symmetry);
 Area of the neuroretinal rim;
 Area of the optic disc;
 Mean cup/disc ratio;
 Mean vertical cup/disc ratio;
 Cavity volume.



Regional thickness of the neuroretinal rim (TEMP: temporal; SUP: superior; NAS: nasal; INF: inferior). The right eye is shown as a continuous line, the left eye as a dotted line; normal zones are indicated in green, and abnormal zones in yellow and then red. This colour coding makes it easy to locate a notch.

Regional thickness of the optical fibre layer 3.4 mm from the centre of the optic nerve. The right eye is shown as a continuous line, the left eye as a dotted line; normal zones indicated in green, abnormal zones in yellow and then red.

Representation of optical fibre thickness for each eye in sections 6 hr wide. In glaucoma, the most affected zones are the upper and lower zones.

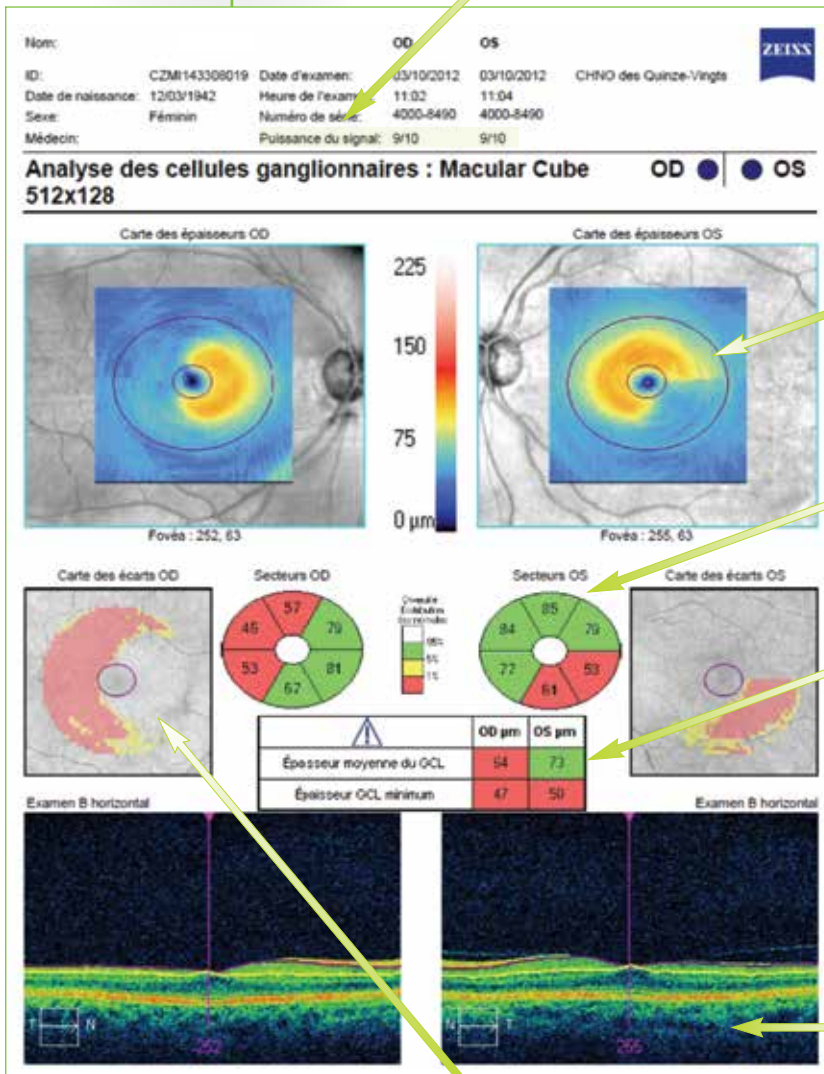
Representations, of optical fibre thickness in each eye, in sections 2 hr wide. In glaucoma, the most affected areas are located at 7 hr for the right eye and 5 hr for the left eye.

Figure 16

Presentation of the ganglion cells (macular cube)

Figure 17 shows typical OCT findings for the ganglion cell layer, with the right eye (OD) on the left and the left eye (OS) on the right. For each value, the number appears on a white background if it is within 5% of the best values, and on a green background for 90% of cases. Yellow indicates an anomaly at the < 5% level, and red indicates an anomaly at the < 1% level.

Signal strength indicates whether the results have been correctly acquired: values should be higher than 6/10. However, even if the signal is strong, the results may be inaccurate if the eye is incorrectly positioned.



Thickness of the RNFL. The thicker this layer is, the warmer the colour. A "clock hands" appearance, centred on the disc, is normal.

Presentation of the macular sector, excluding the fovea, showing the average thickness in each zone.

Mean and minimum values for the thickness of the ganglion cell/internal interplexiform layer, excluding the ganglion cell fibre layer. The minimum value corresponds to the thinnest 1° sector.

Horizontal scan of the macular passing through the fovea.

Statistical values of anomalies in this layer. Yellow: $p < 0.05$; red: $p < 0.01$

Figure 17

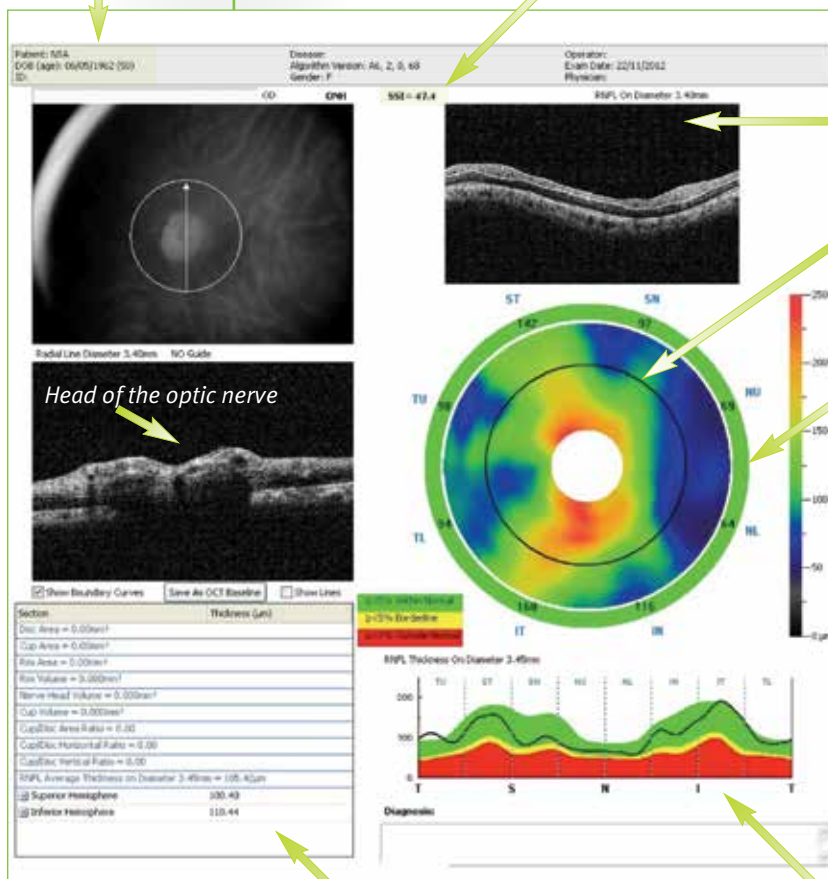
OCT imaging of the ganglion cell layer (macular cube).

Presentation of the parapapillary RNFL and the optic nerve

Figure 18 shows the results of an OCT examination of the parapapillary RNFL and optic nerve, performed using the Optovue scanner. The figure presents findings in a single eye, showing the overall results for the optic nerve head and the parapapillary region, with statistical analysis.

Image of the ocular fundus; the circle indicates the zone where the RNFL is measured.

SSI: Signal Strength Intensity. This should be greater than 50.



RNFL analysis 3.4 mm from the optical centre.

Regional RNFL thickness: the warmer the colour, the greater the thickness.

Regional thickness of the RNFL, with statistical values: normal zones are green, abnormal zones are yellow and then red.

Parameters of the optic nerve head.

Regional thickness of the RNFL (T: temporal; S: superior; N: lower nasal; I: inferior) 3.4 mm from the centre of the optic nerve.

Figure 18

Presentation of OCT findings (Optovue) in the parapapillary RNFL and optic nerve.

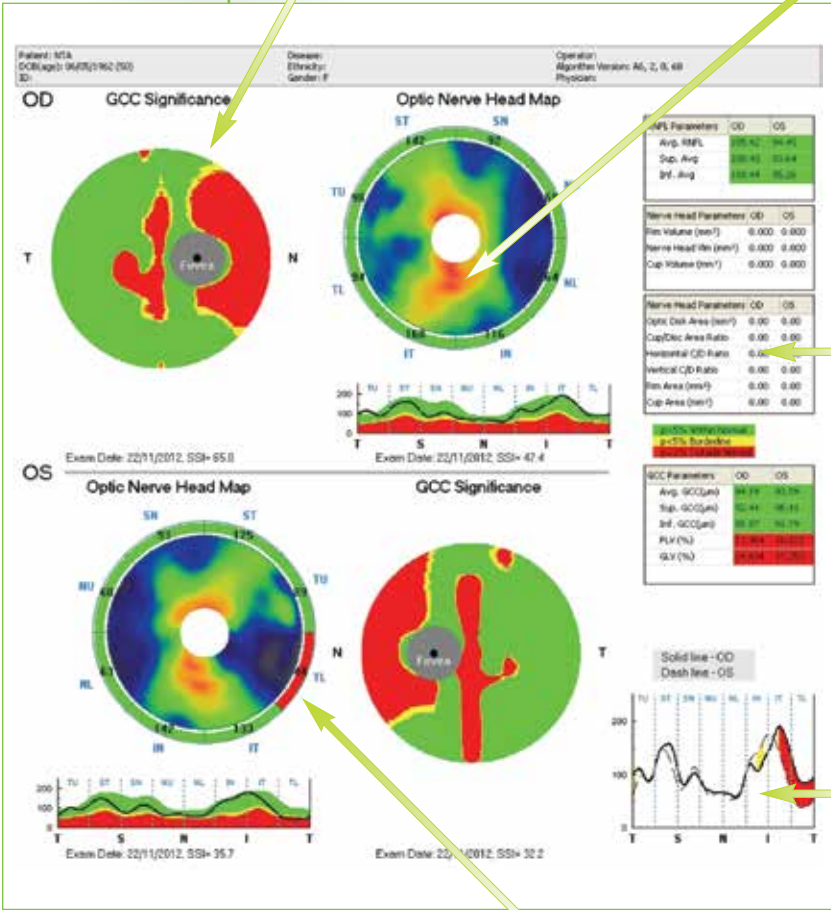
General presentation of the macular ganglion cells and parapapillary RNFL

OCT findings can be summarized in a single page, without showing the actual OCT images (Figure 19). This presentation includes most of the elements shown in the previous figures, including:

- RNFL thickness
- statistical analysis of RNFL thickness
- ganglion cell complex
- optic nerve head parameters.

Statistical representation of the macular ganglion cell complex (optical fibre axons, ganglion cells and internal interplexiform layer).

Thickness of the RNFL in the different regions: the warmer the colour, the greater the thickness.



Optic nerve head parameters

Interocular differences in parapapillary RNFL thickness

Regional thickness of the RNFL, with statistical values: normal zones are green, abnormal zones are yellow and then red.

Figure 19
General presentation of OCT (Optovue) findings in the macular ganglion cells and parapapillary RNFL.

Glaucoma

Glaucoma is a slowly progressive optic neuropathy that is usually associated with ocular hypertension. Progressive deformation of the optic nerve head resulting from hypertension leads to cavity formation and destruction of the retinal nerve fibres passing through the cribriform lamina. This neuropathy in turn leads to visual field impairment. The progressive nature of glaucoma suggests it should be theoretically possible to detect structural changes in the retina and optic nerve before the condition becomes clinically apparent with visual field impairment ⁶. Prior to the introduction of OCT, however, this could not be confirmed with the available techniques.

With the new generation of spectral domain OCT devices, structural changes in the eye can often be detected before the onset of visual impairment. However, in some cases, this may not be the case: visual impairment may become apparent before any structural impairment can be detected. The reason for this is that each eye has between 800,000 and 1.2 million optical fibres, and so in many cases significant structural damage can be tolerated without visual impairment. Conversely, in an eye with a smaller number of fibres, visual impairment may become apparent more quickly.

Optic nerve

At the optic nerve head, OCT measurements show successive changes in:

- the vertical thickness of the neuroretinal rim,
- the overall area of this rim ,
- the vertical C/D ratio (Figure 20).

Although these parameters are useful for the detection of glaucoma, they are less effective in differentiating early glaucoma from moderate glaucoma ⁷.

RNFL

The OCT measurements parameters that best differentiate normal subjects from patients with early glaucoma are:

- RNFL thickness in the lower temporal zone,
- RNFL thickness in the lower quadrant,
- average RNFL thickness (Figure 20).

There is some evidence that measurements in the upper temporal sector would be as effective in discriminating between individuals with and without glaucoma as measurements in the lower temporal quadrant ⁸.

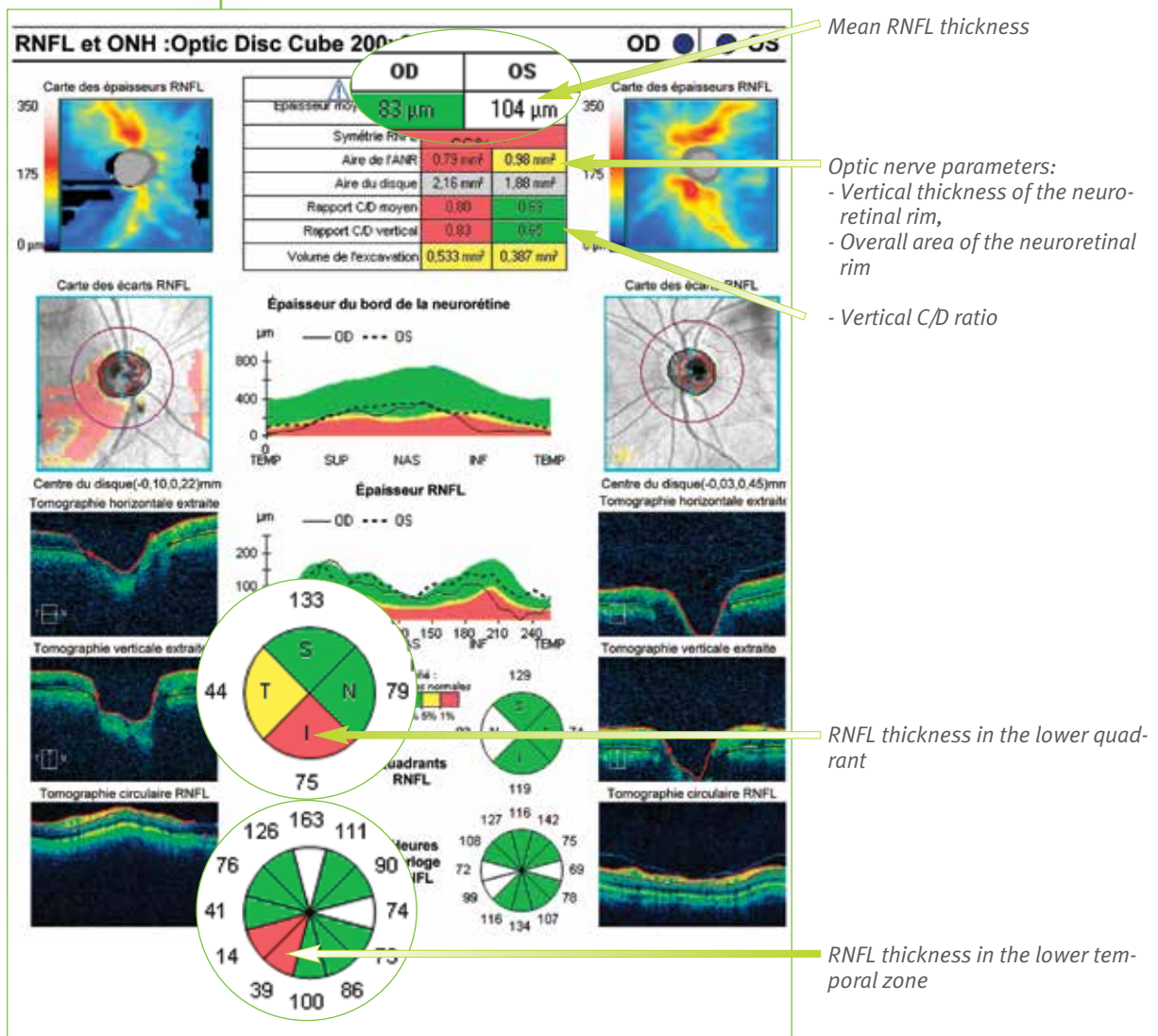


Figure 20

OCT imaging of the optic nerve and RNFL in glaucoma.

Macular ganglion cell complex

Macular ganglion cells can only be studied using spectral domain OCT, and hence imaging of these cells in glaucoma is a more recent innovation. Early glaucoma is mainly characterized by changes in the mean minimum thickness and lower temporal thickness (Figure 21).

For OCT examination, the macula is divided into 360 sectors, each one degree wide, and the mean minimum thickness is that of the thinnest sector.

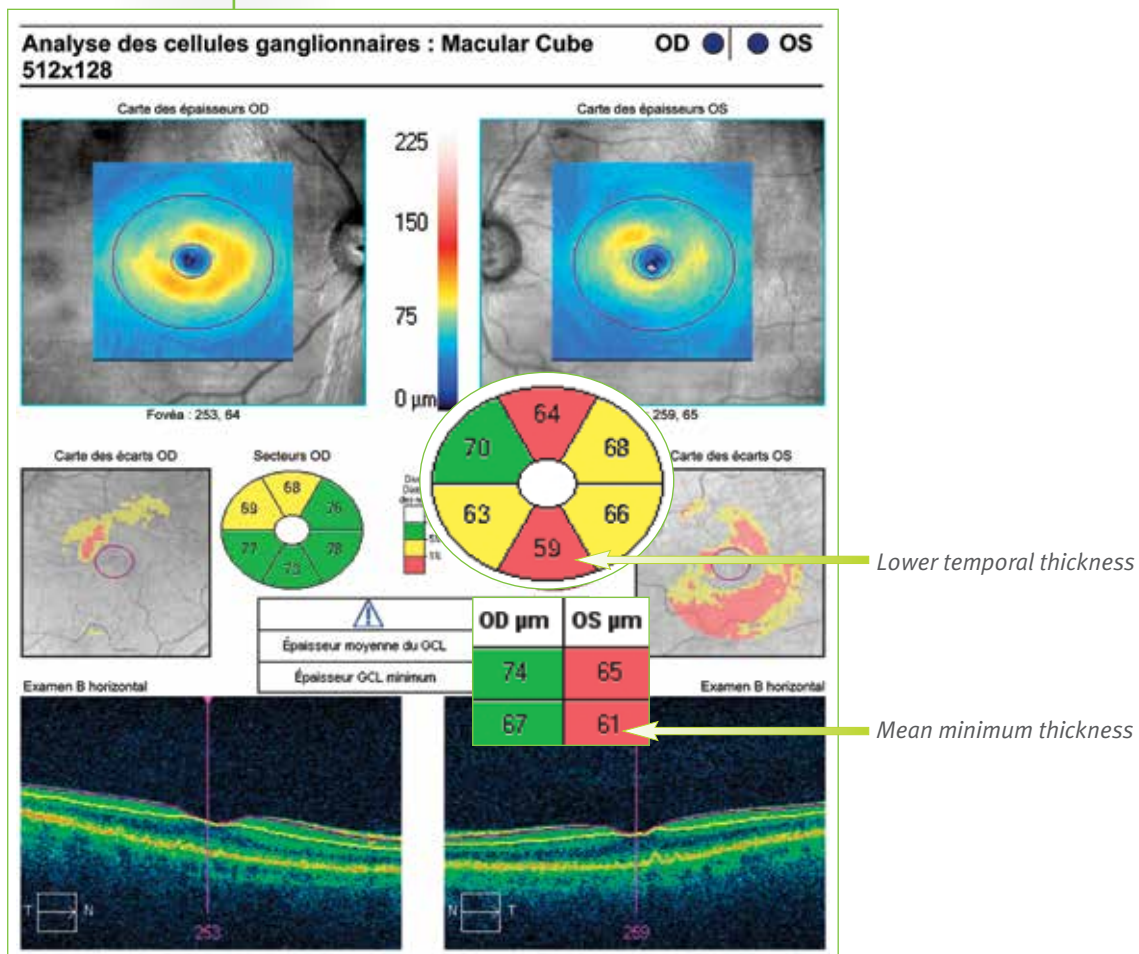


Figure 21

Spectral domain OCT measurements of the macular ganglion cell complex in glaucoma.

Optic nerve or retinal nerve fibres: which should be examined first in glaucoma?

As we have seen, OCT can provide detailed information about a variety of ocular structures, and this raises the question of which parameters are most reliable for the early detection of glaucoma: in particular, is it better to examine the optic nerve head or the parapapillary ganglion fibres? When a large number of optical fibres are present, the thickness of this layer can be easily measured, but as the thickness decreases the posterior edge of the layer becomes more difficult to differentiate from adjacent structures, and hence measurements become more variable. Conversely, in the presence of a thin ganglion cell layer, it would be easier to determine optic nerve parameters: OCT is very effective in measuring optic nerve parameters by analysis of the end of Bruch's membrane.

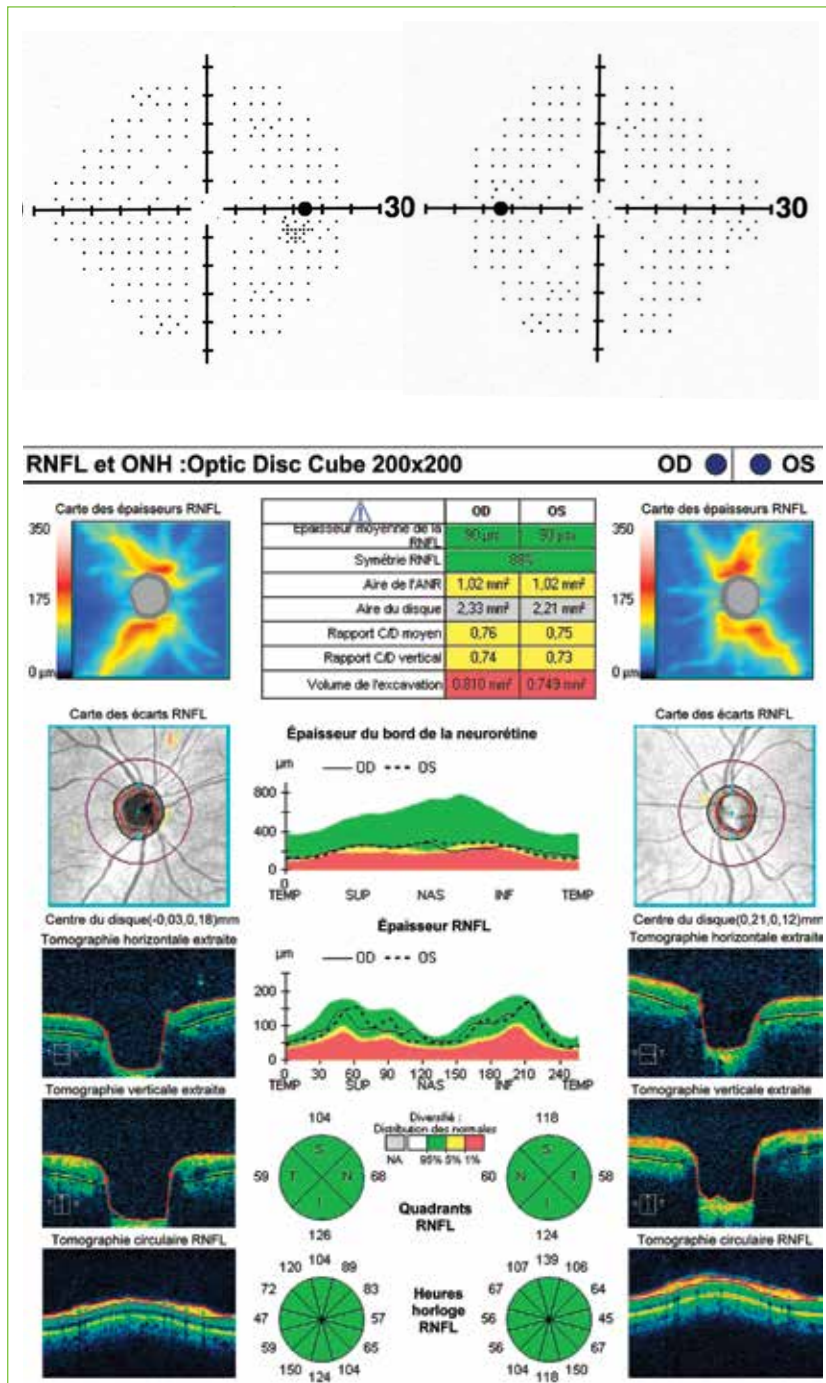
However, the appearance of the optic nerve varies greatly between individuals, making statistical comparisons difficult, particularly when the optic nerve is irregular, such as in patients with myopia or dysversion of the optic nerve head.

In general, it is easier to detect preperimetric glaucoma in the RNFL, although in rare cases optic nerve analysis may be preferable. In some patients, analysis of macular ganglion fibres is as effective as RNFL measurement ⁹.

Patients with isolated optic nerve impairment

Due to the marked variability in the appearance of the optic nerve between individuals, which is not adequately represented in the standard databases used by OCT software, isolated optic nerve impairment may occur. In this situation, the retinal nerve fibres appear normal at both parapapillary and macular ganglion cell level, and the visual field is also normal (Figure 22).

Optical fibre analysis is preferred in such cases, although it is still desirable to monitor the progressive changes in optic nerve parameters over time in the same patient.



All results are normal, except from an abnormal cavity volume for each eye. Glaucoma is not established. Simple monitoring is recommended in such cases.

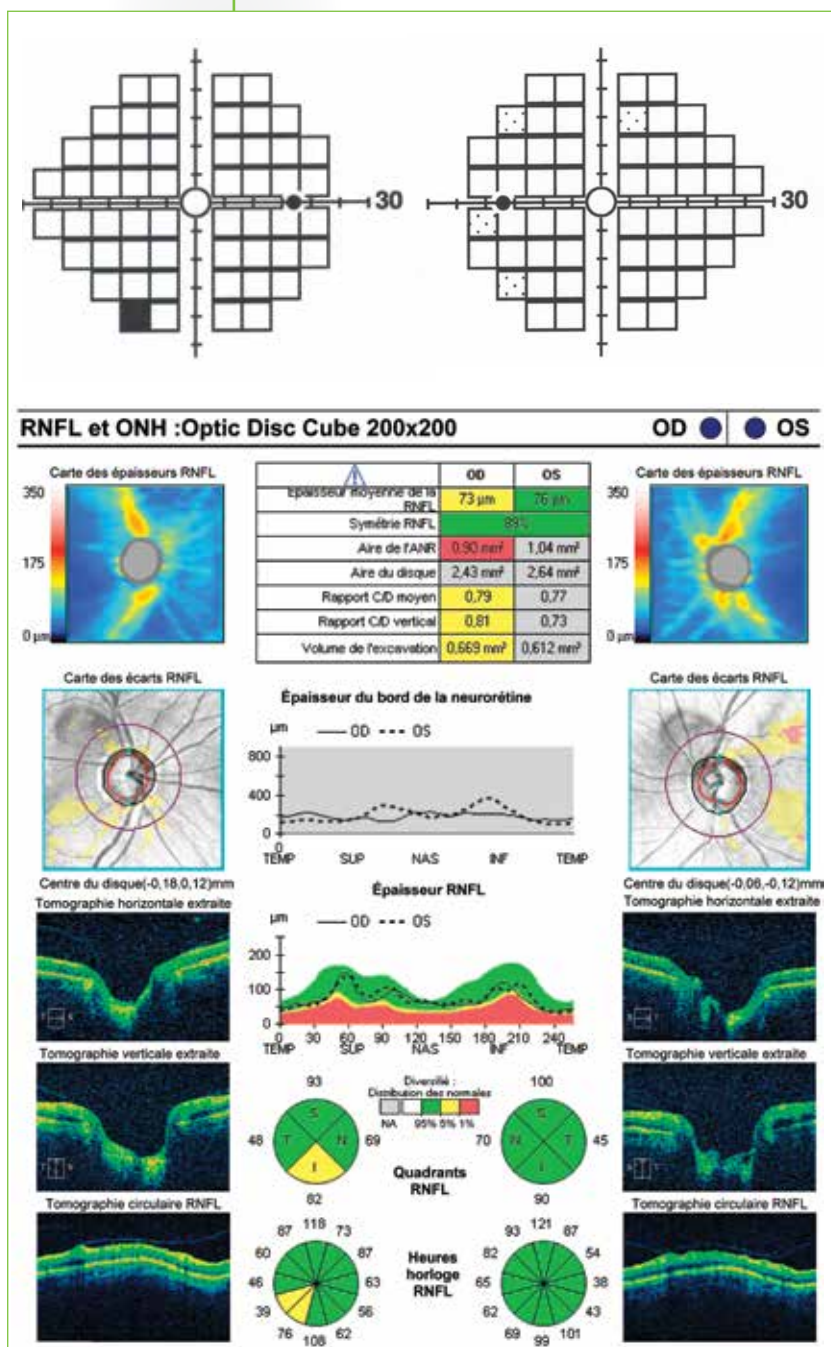
Figure 22

OCT findings in a patient presenting with a suspected physiological cavity.

Preperimetric glaucoma

The term preperimetric glaucoma denotes glaucoma that is detected by the presence of structural impairment or changes in early visual field detection tests, such as the blue-yellow visual field or the frequency doubling technology (FDT) Matrix, while conventional visual field assessments (e.g. Humphrey-type automated perimetry or Octopus® perimetry) are normal. OCT findings in various presentations of preperimetric glaucoma are shown in the following figures.

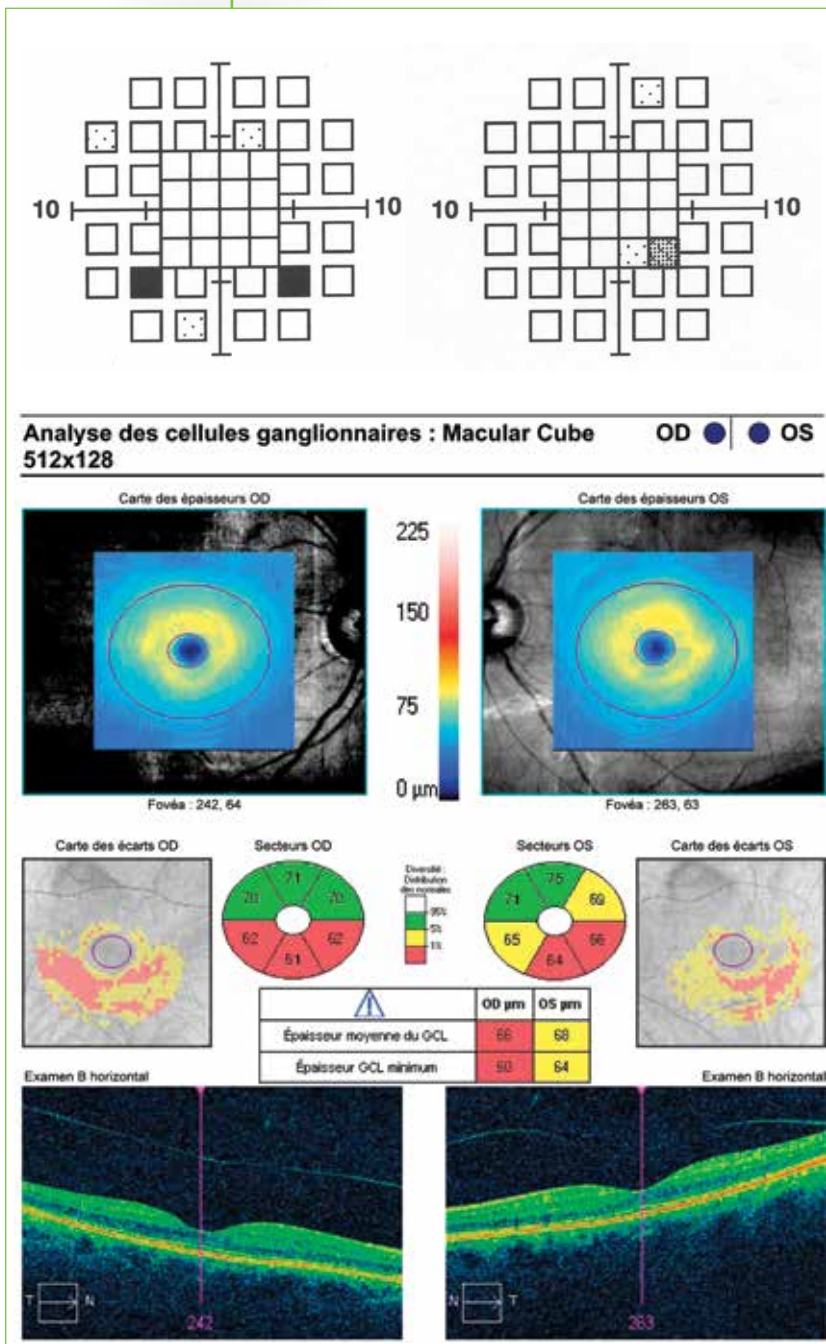
Isolated impairment on OCT



Optic nerve OCT and FDT matrix findings in a 60-year-old patient with ocular hypertension (23 mmHg). OCT and FDT matrix findings are at the limits of normal ranges.

Figure 23
Preperimetric glaucoma

OCT may be the only complementary examination required in such patients. Simple monitoring is usually sufficient, but treatment is a viable alternative, particularly if the OCT deficit is large.



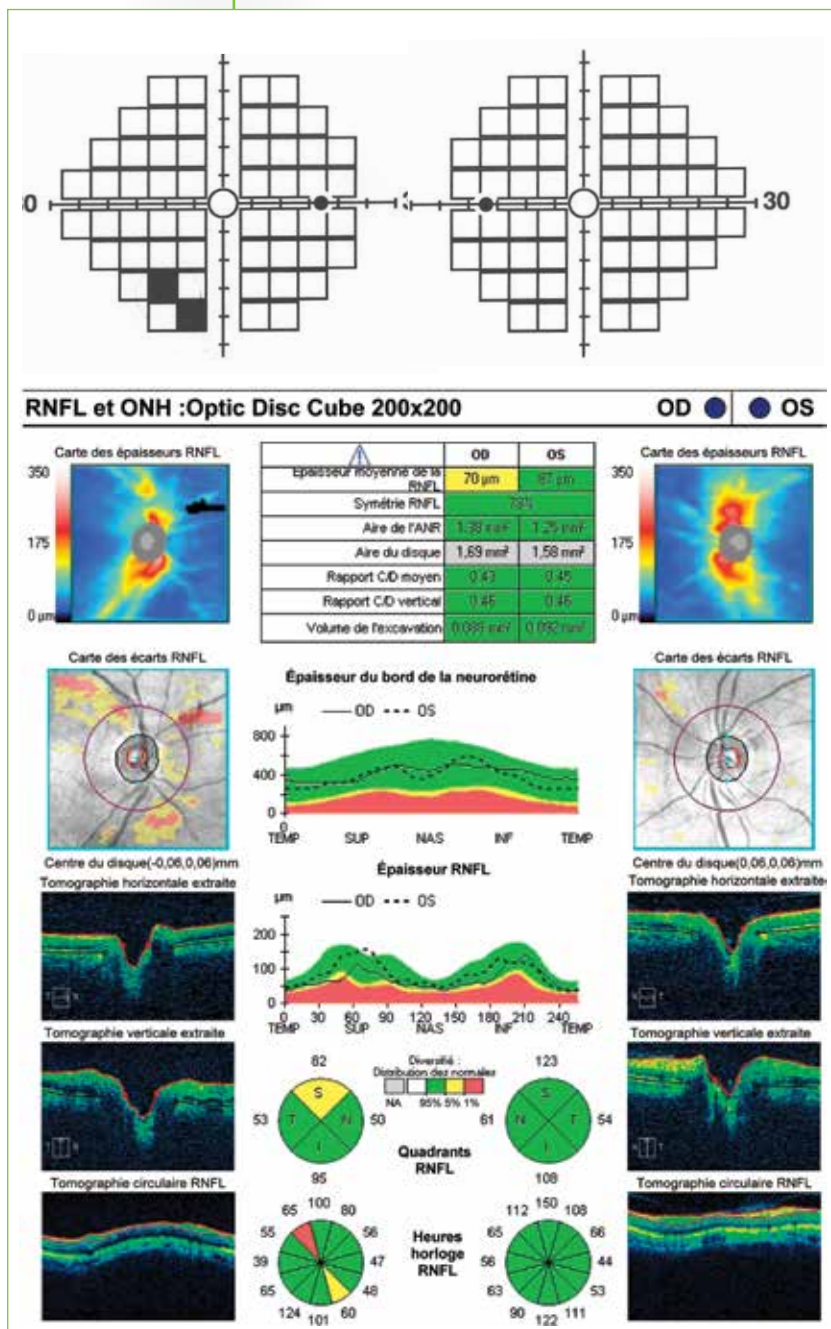
Macular OCT findings in the same patient as in Figure 23. There is a clear, well systematized, impairment in the right eye, and the 10° matrix test is abnormal.

Figure 24

Preperimetric glaucoma

Preperimetric glaucoma: Impairment of the RNFL and the FDT Matrix visual field

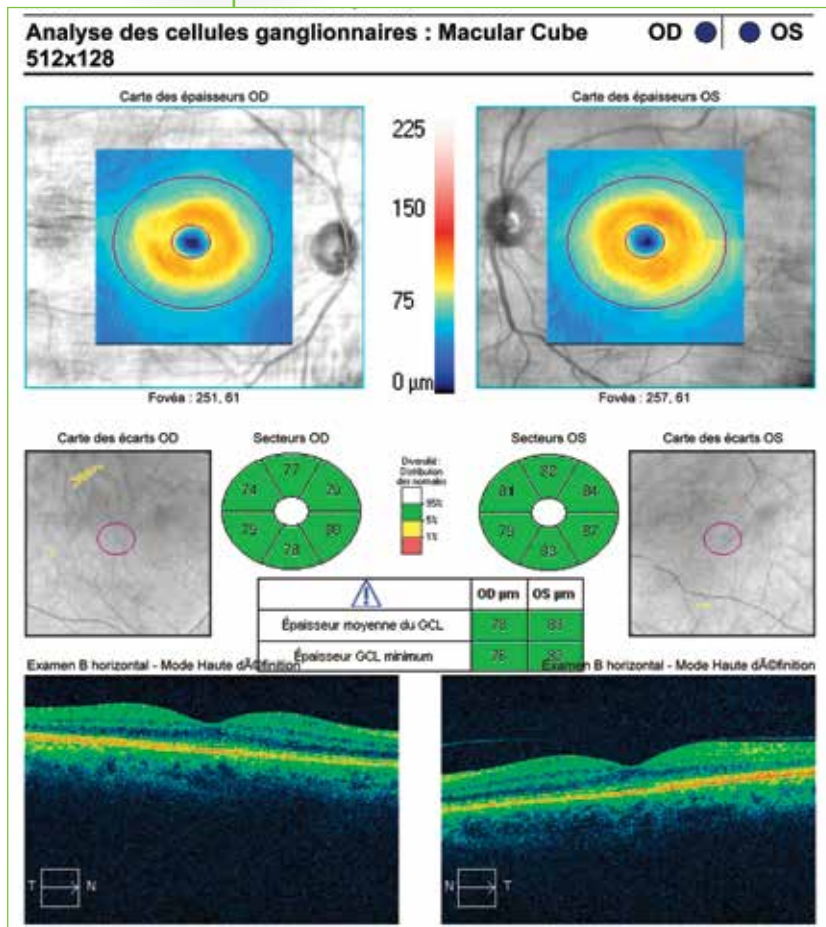
Early visual field impairment detected by OCT and FDT Matrix indicates the beginning of glaucoma, particularly if the deficits are consistent. These deficits may precede the development of conventional perimetry deficits by 5 years.



Optic nerve OCT and FDT matrix findings in a 70-year-old patient with ocular hypertension (24 mmHg). The optic nerve appears normal, but OCT and FDT matrix show matching impairments of the RNFL in the right eye.

Figure 25
Optic nerve OCT and FDT matrix

Figure 25 shows optic nerve OCT and FDT matrix findings from a 74-year-old patient with ocular hypertension (24 mmHg). The optic nerve is normal, but OCT and FDT Matrix show matching impairments in the RNFL of the right eye. In this patient, there was no central impairment, as assessed by macular cube OCT (Figure 26).



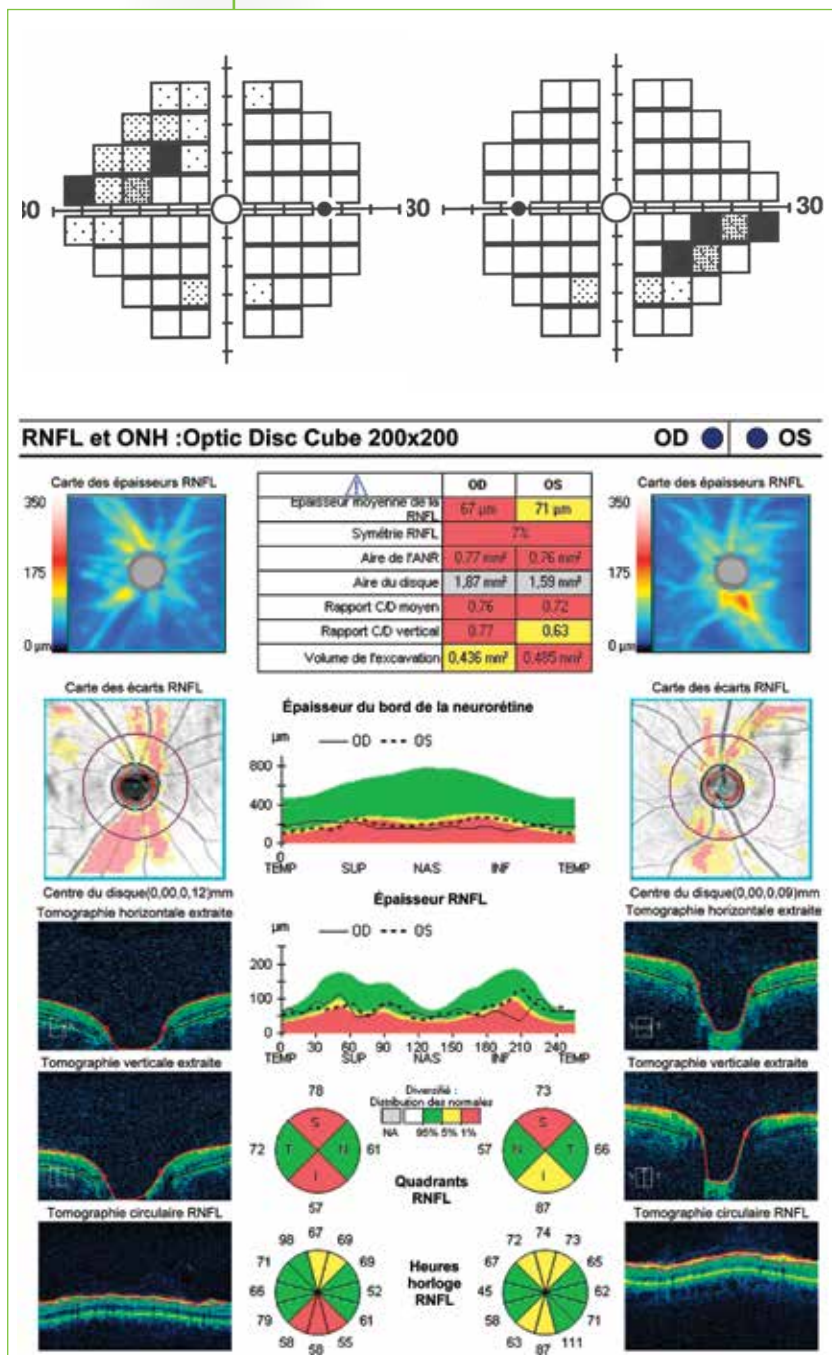
Macular cube OCT analysis in the same patient as in Figure 25. There is no central impairment.

Figure 26

Macular cube OCT analysis

Preperimetric glaucoma: impairment of the RNFL layer, the macula and the FDT Matrix visual field

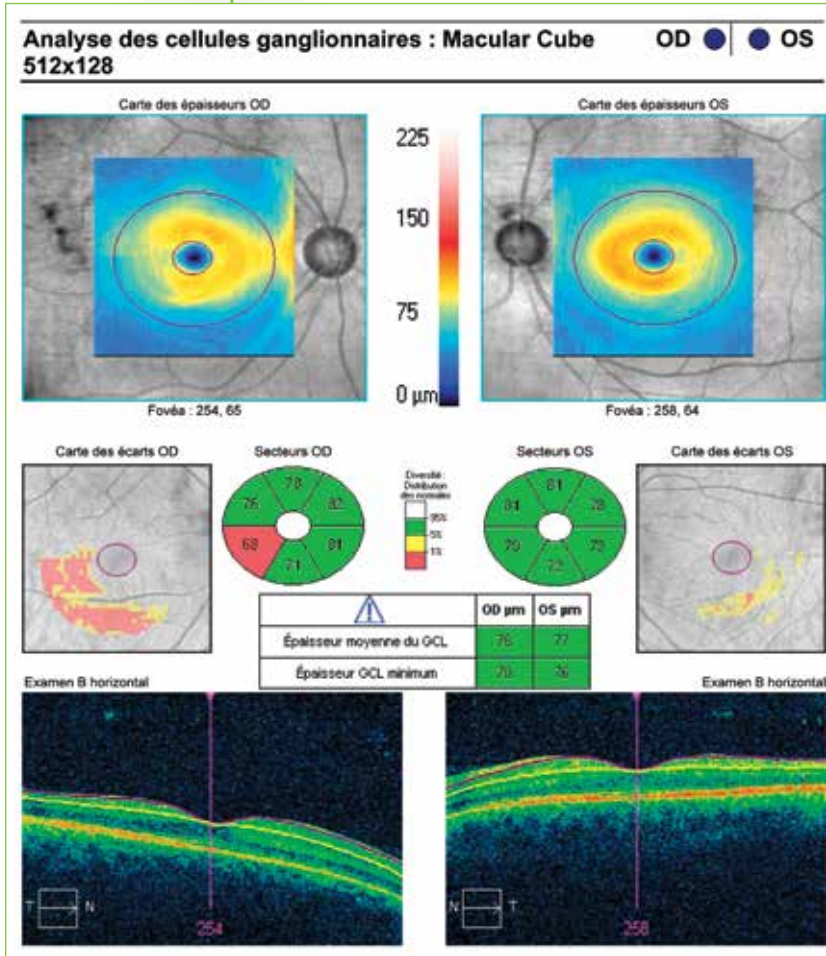
There is often an impairment of both the RNFL layer and the macular ganglion cell complex in OCT. If the deficit is more present in the parapapillary region, we can assume that hypertension likely plays a major role. Otherwise, we will consider more vascular problems.



OCT and FDT matrix findings in a 55-year-old patient with ocular hypertension (26 mmHg). Automated periphery measurements are normal, but FDT matrix shows bilateral impairment. OCT confirms the presence of this impairment, in both the optic nerve and RNFL.

Figure 27

This situation is illustrated in Figure 27, which shows OCT and FDT matrix findings in a 55-year-old patient with ocular hypertonia (26 mmHg). Automated perimetry findings are normal, but bilateral impairment is apparent on Matrix evaluation. OCT confirms this impairment, both in the optic nerve and the RNFL layer. OCT examination of the macular region shows slight macular impairment on the right side and normal results on the left side (Figure 28). This profile would suggest early hypertonic glaucoma.

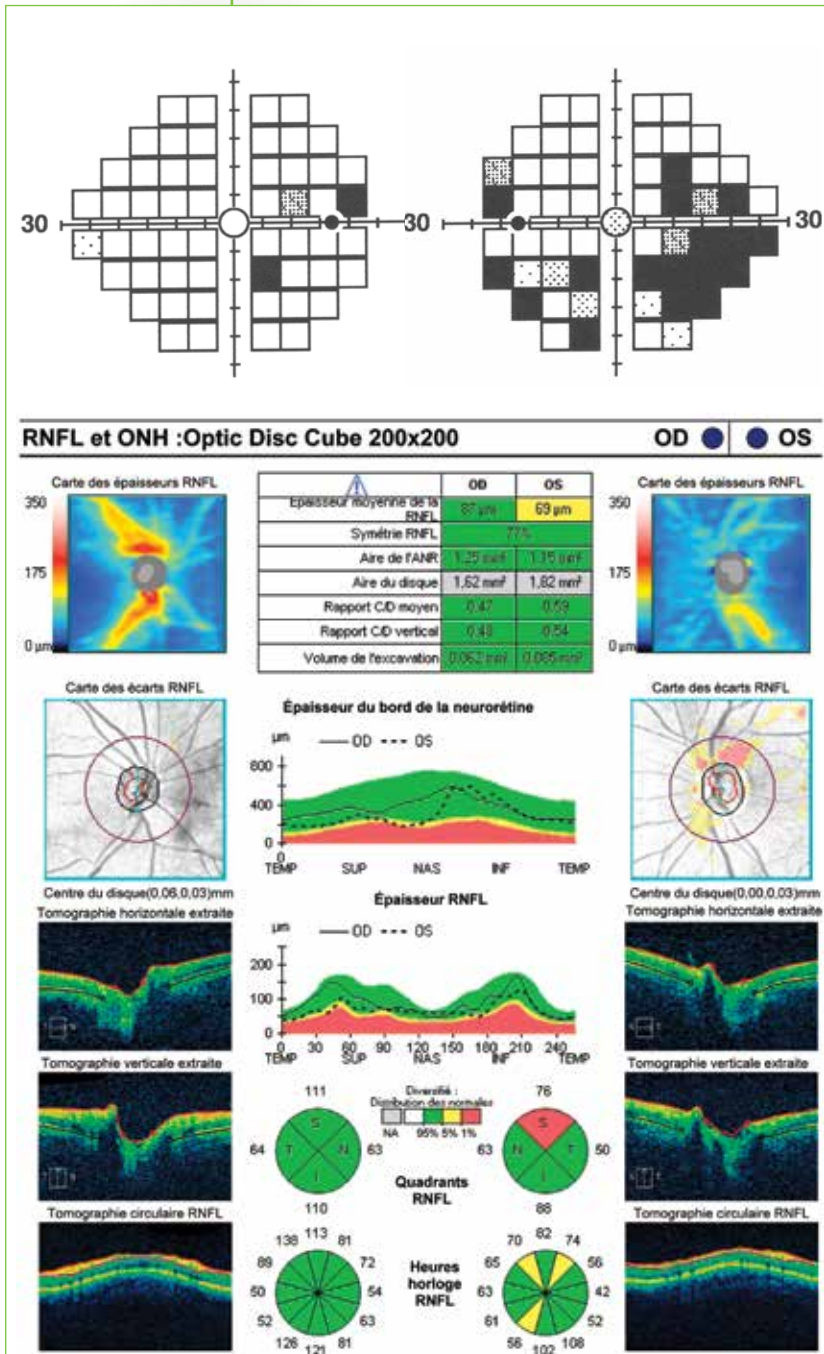


Macular cube OCT analysis in the same patient shown in Figure 27. There is little impairment on the right side, and normal findings on the left side. The combination of RNFL, macular and FDT matrix impairment suggests early hypertonic glaucoma.

Figure 28

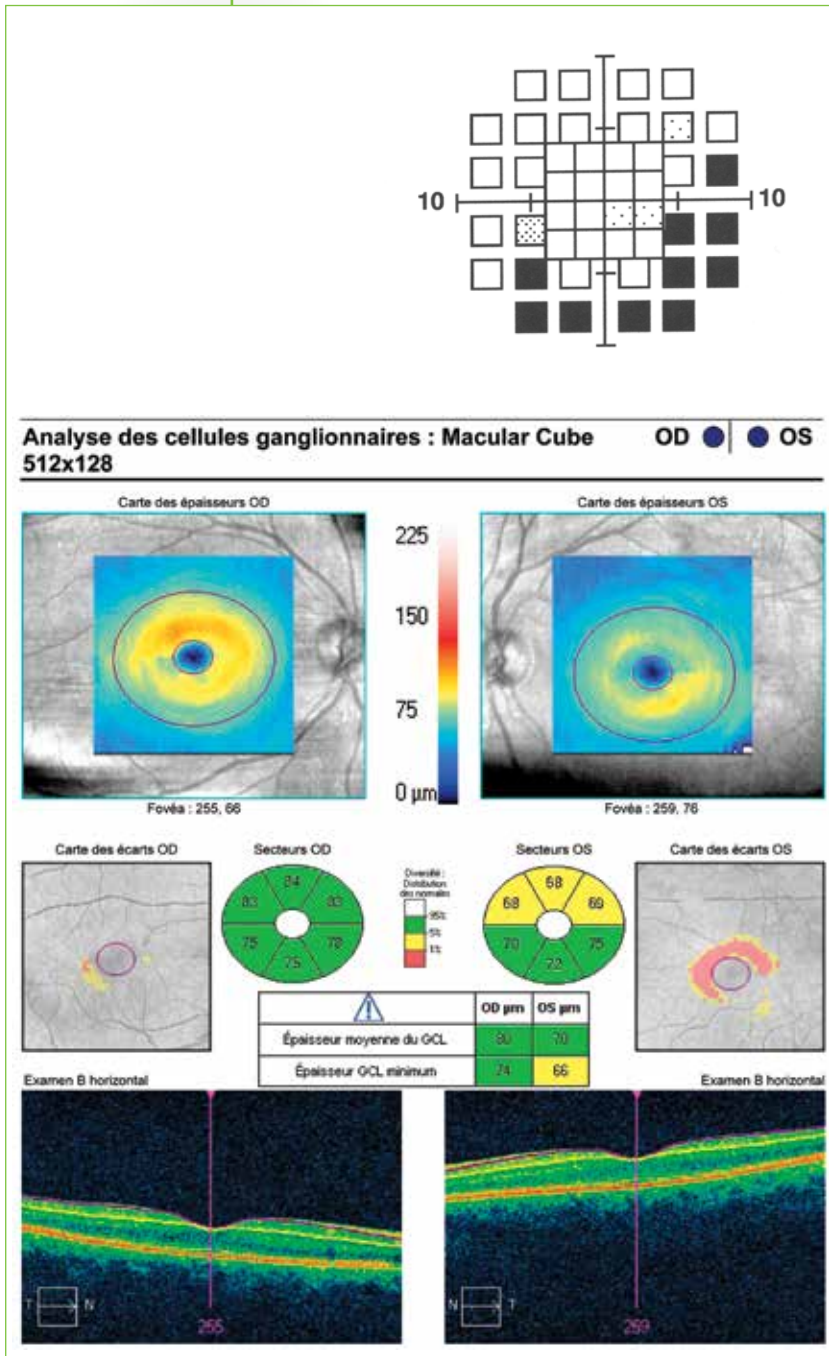
Preperimetric glaucoma: impairment of the FDT Matrix with normal OCT

It is rare to observe normal OCT findings in a patient who already has perimetric visual field impairment, although such cases could hypothetically occur in glaucoma (Figures 29 and 30). These findings should suggest a more central impairment, and further testing is needed to establish the diagnosis.



OCT and FDT matrix findings in a 60-year-old patient with ocular hypertension (24 mmHg). The matrix visual field shows marked impairment on the left side, although only slight impairment is visible on OCT.

Figure 29

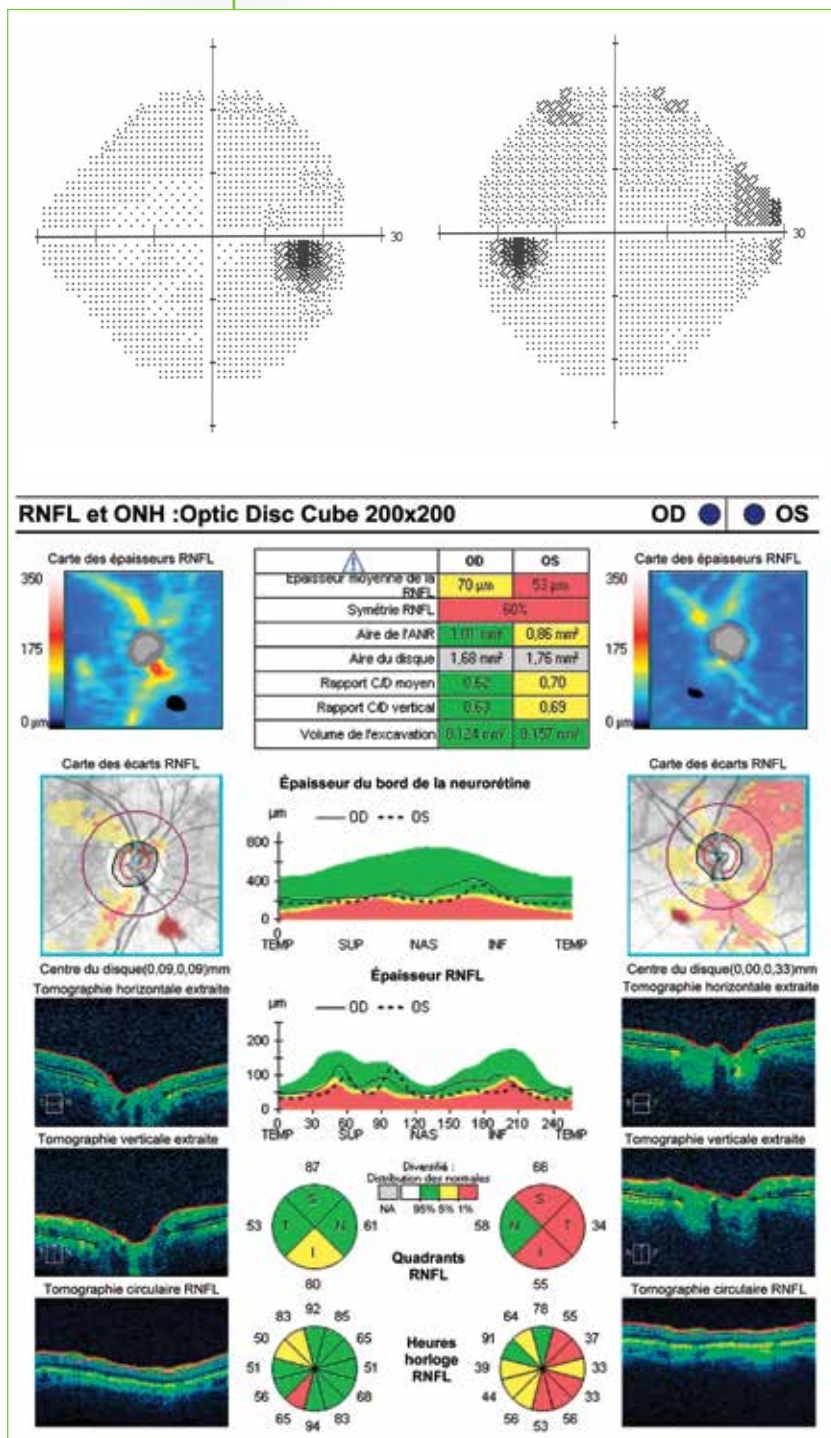


Macular cube OCT analysis and visual field assessment in the same patient as in Figure 29. The macular ganglion cell complex is normal on the left side, and at the limit of normal on the right side, but the matrix central 10° test results are abnormal.

Figure 30

Early open-angle glaucoma

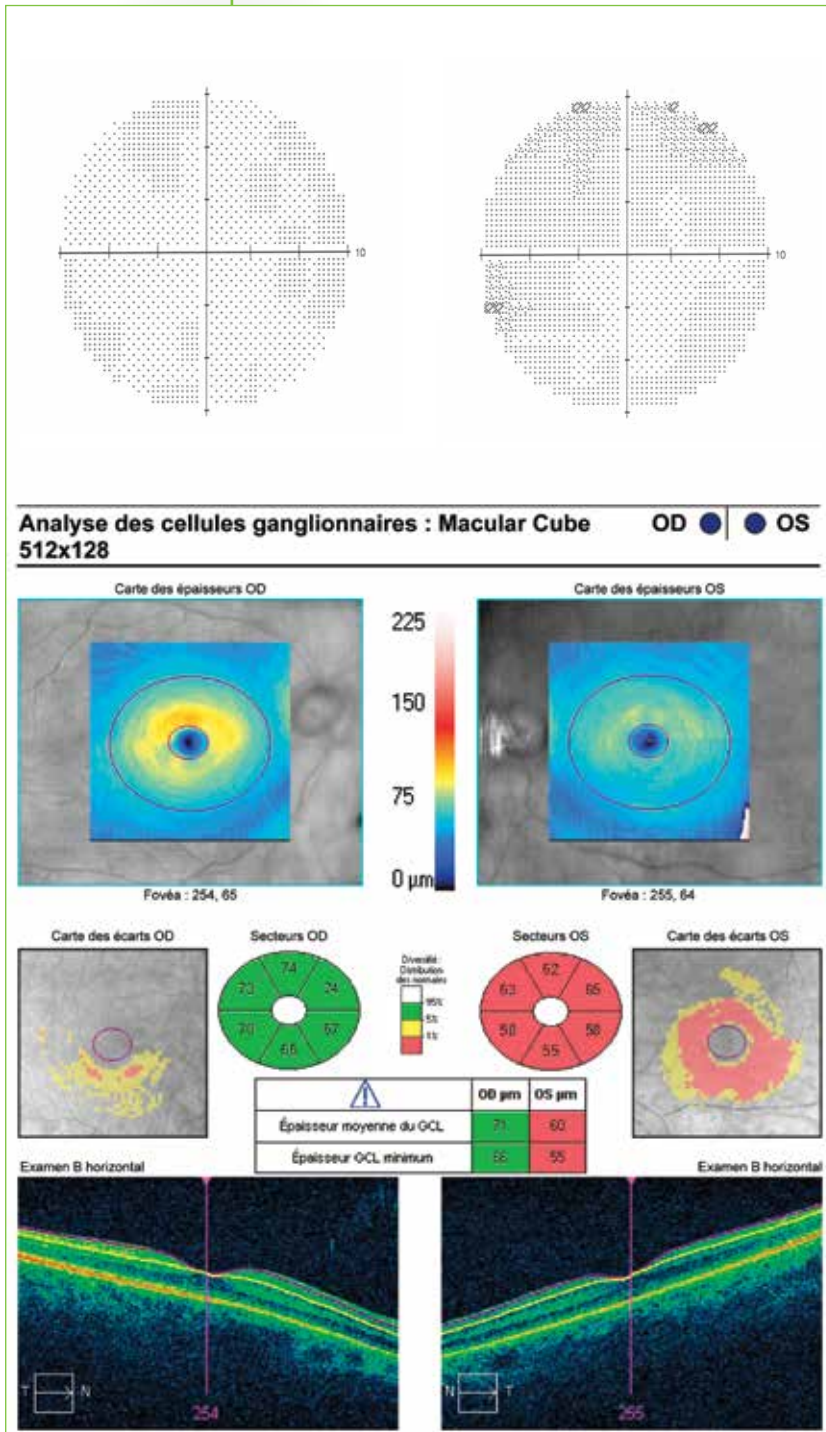
OCT findings are often consistent with visual field assessments in patients with early or moderate glaucoma (Figures 31 and 32). An OCT finding that impairment is greater in the macular region than in the peripapillary region is not indicative of severe glaucoma, provided the deficit remains moderate.



Optic disc OCT and visual field assessments in a 79-year-old patient with ocular pressures of 22 mmHg in the right eye and 26 mmHg in the left eye. In the right eye, the visual field is normal, and OCT shows a lower temporal deficit typical of early glaucoma. In the left eye, the impairment is more marked and extensive.

Figure 31

In young patients with early or moderate glaucoma, OCT impairment is greater than visual field impairment.

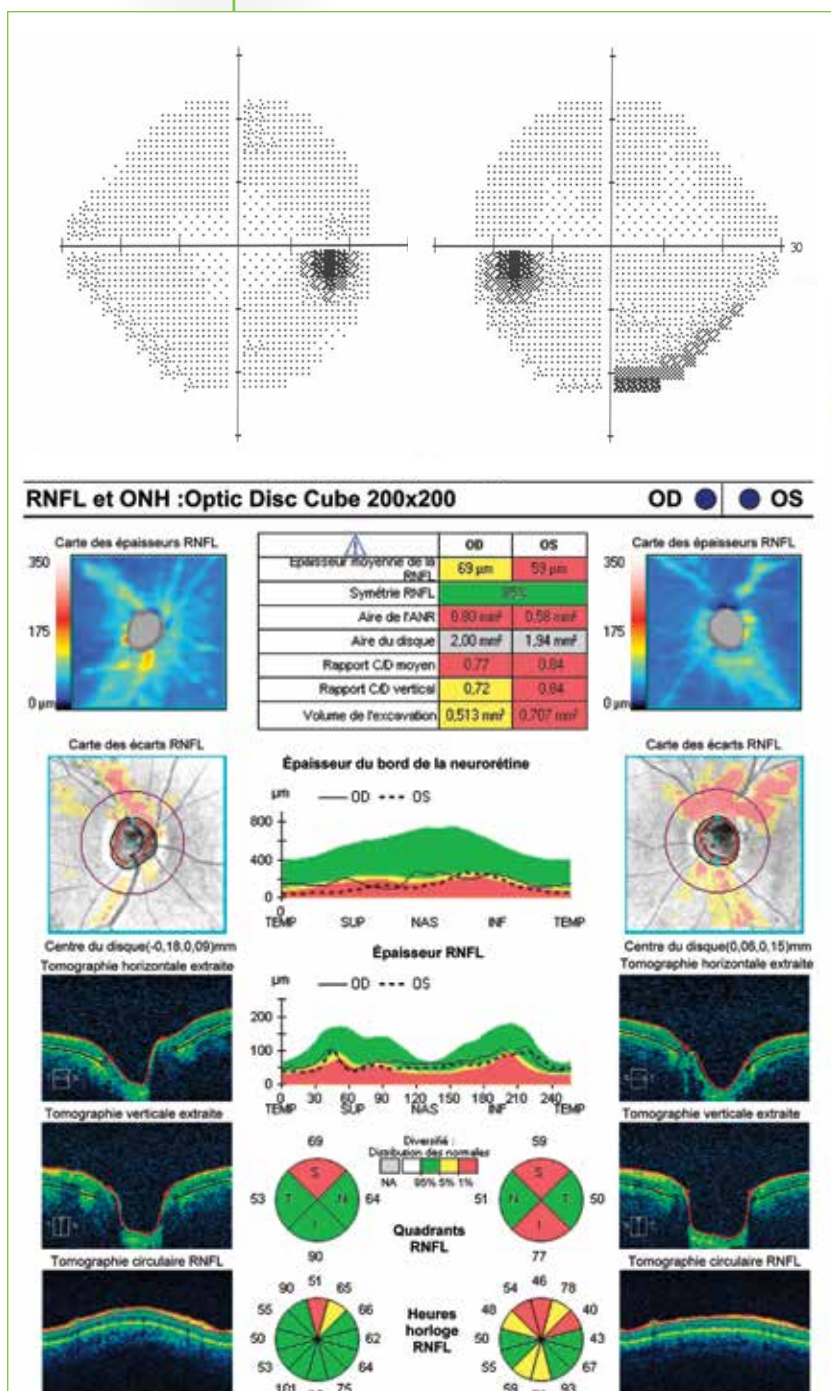


Macular cube OCT and central 10° visual fields in the same patient as in Figure 31. Macular impairment is observed in the left eye, with abnormal values for mean and minimum thickness. The central 10° visual fields are normal.

Figure 32

Early open-angle glaucoma: depth of OCT and visual field impairment in early open-angle glaucoma

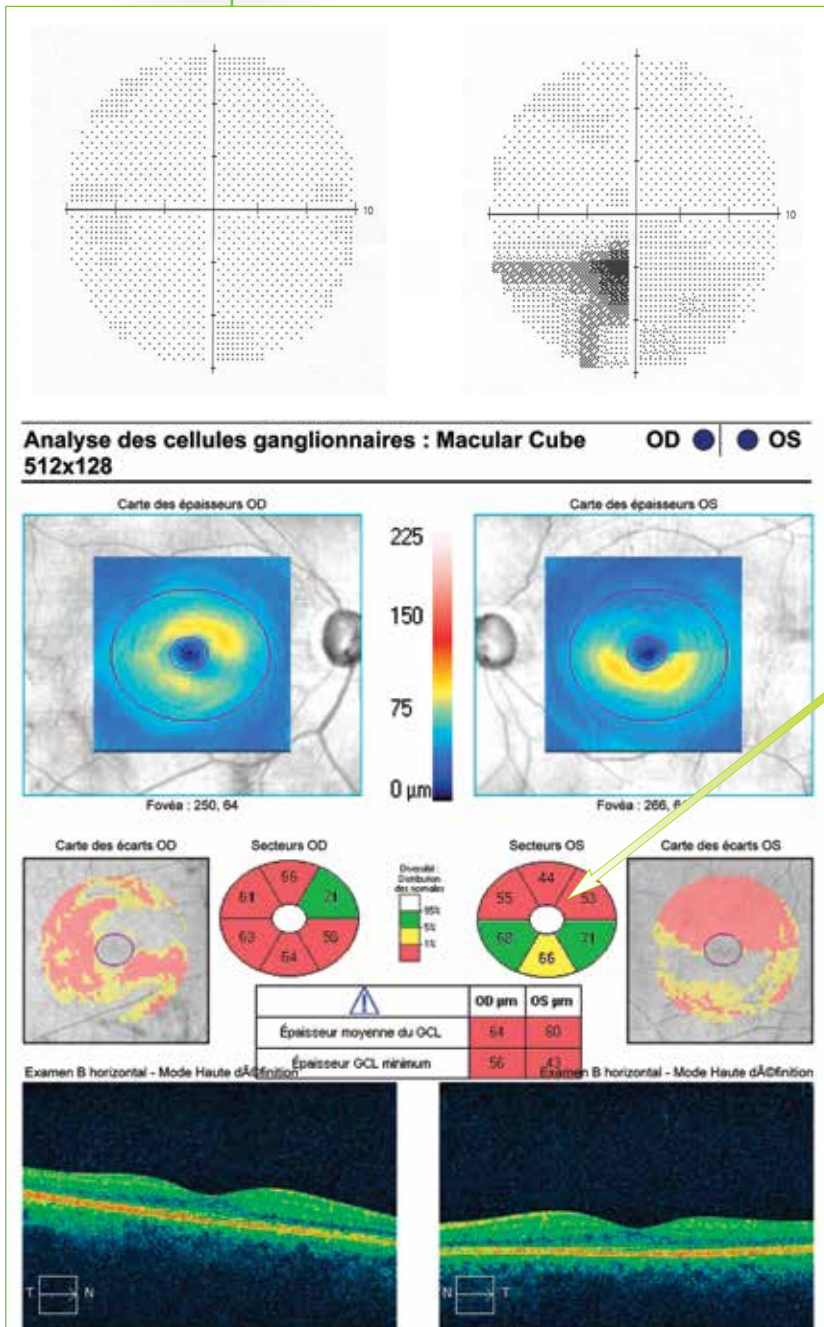
The impact of a reduction in RNFL thickness on the visual field depends on the severity of the impairment, and hence the thickness must be analysed accurately in the different regions of the retina. Figures 33 and 34 show OCT findings in a 70-year-old patient with an 8-year history of open-angle glaucoma. OCT and visual field impairments are almost concordant, with more



Optic disc OCT and visual field assessments in a 70-year-old patient with an 8-year history of open-angle glaucoma. Impairments in the visual field and OCT measures are almost concordant, with more marked changes in both the RNFL and the cavity on the left side.

Figure 33

marked changes in both the retinal nerve fibre and the cavity being seen on the left side. Significant macular impairment is present on both sides, but there is no significant impairment of the right visual field. This is due to the fact that the macular ganglion complex in the corresponding zone is still very thick ($> 60 \mu\text{m}$); by contrast, on the left side, the thickness in the upper sector is reduced to $44 \mu\text{m}$, resulting in a deep lower paracentral scotoma. Such findings explain why impairment may not be noticeable in the central region of the visual field despite marked regional thinning of the macular ganglion cell complex. For this reason, both the minimum and mean thickness of the complex should be measured.

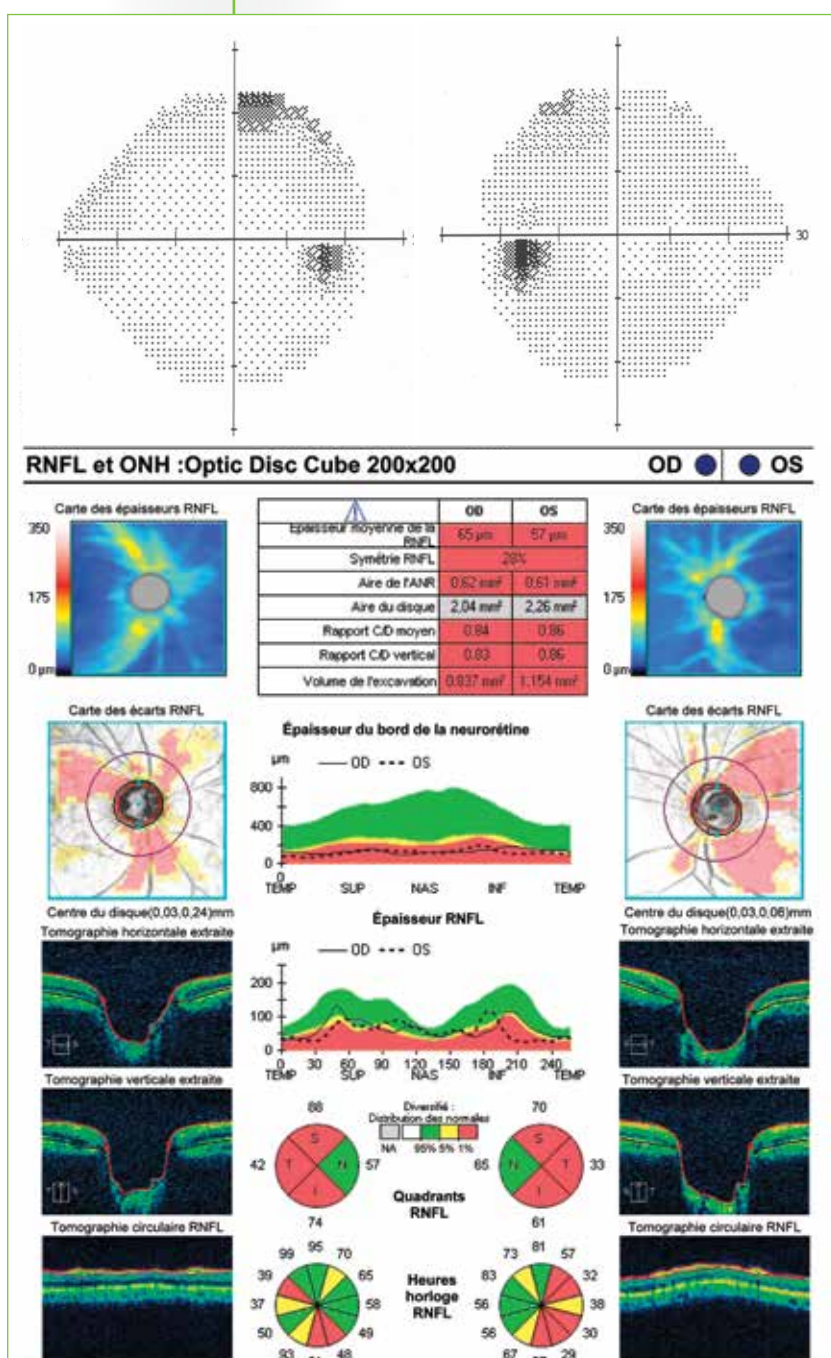


Macular cube OCT and central 10° visual fields in the same patient as in Figure 33. Significant macular impairment is present on both sides (arrow), but there is little impact on the right visual field. This is because the macular ganglion complex is still very thick ($> 60 \mu\text{m}$) in the corresponding zone, whereas on the left side the thickness in the upper sector is reduced to $44 \mu\text{m}$, resulting in a deep lower paracentral scotoma.

Figure 34

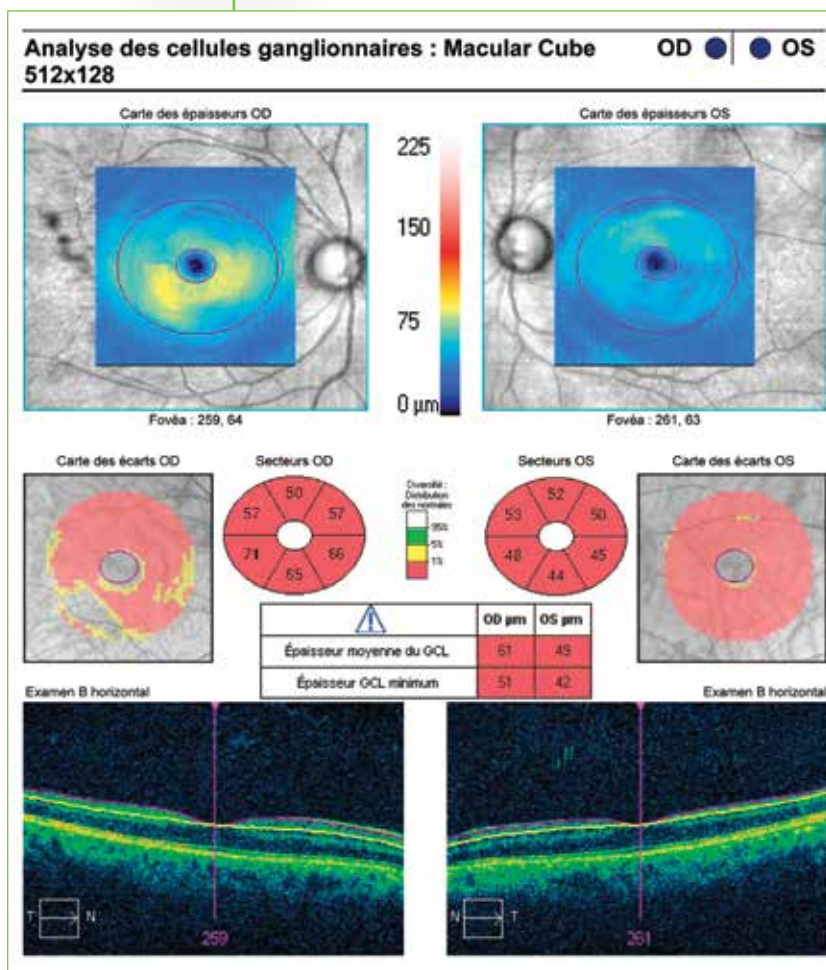
Early open-angle glaucoma: predominant OCT impairment in early open-angle glaucoma

In younger patients with early open-angle glaucoma, OCT findings may be altered to a greater extent, compared with older patients, before changes in visual fields become apparent (Figures 35 and 36). This is due to the fact that in younger patients there is a greater reserve of receptor fields in the ganglion cells: in each region of the visual field, several ganglion cells process the same zone, and thus greater damage can be tolerated before visual impairment develops. This reserve decreases with age.



OCT findings in a 31-year-old patient with a 4-year history of open-angle glaucoma. All optic nerve parameters, and most RNFL parameters, are abnormal, but there is little impairment of the visual field.

Figure 35

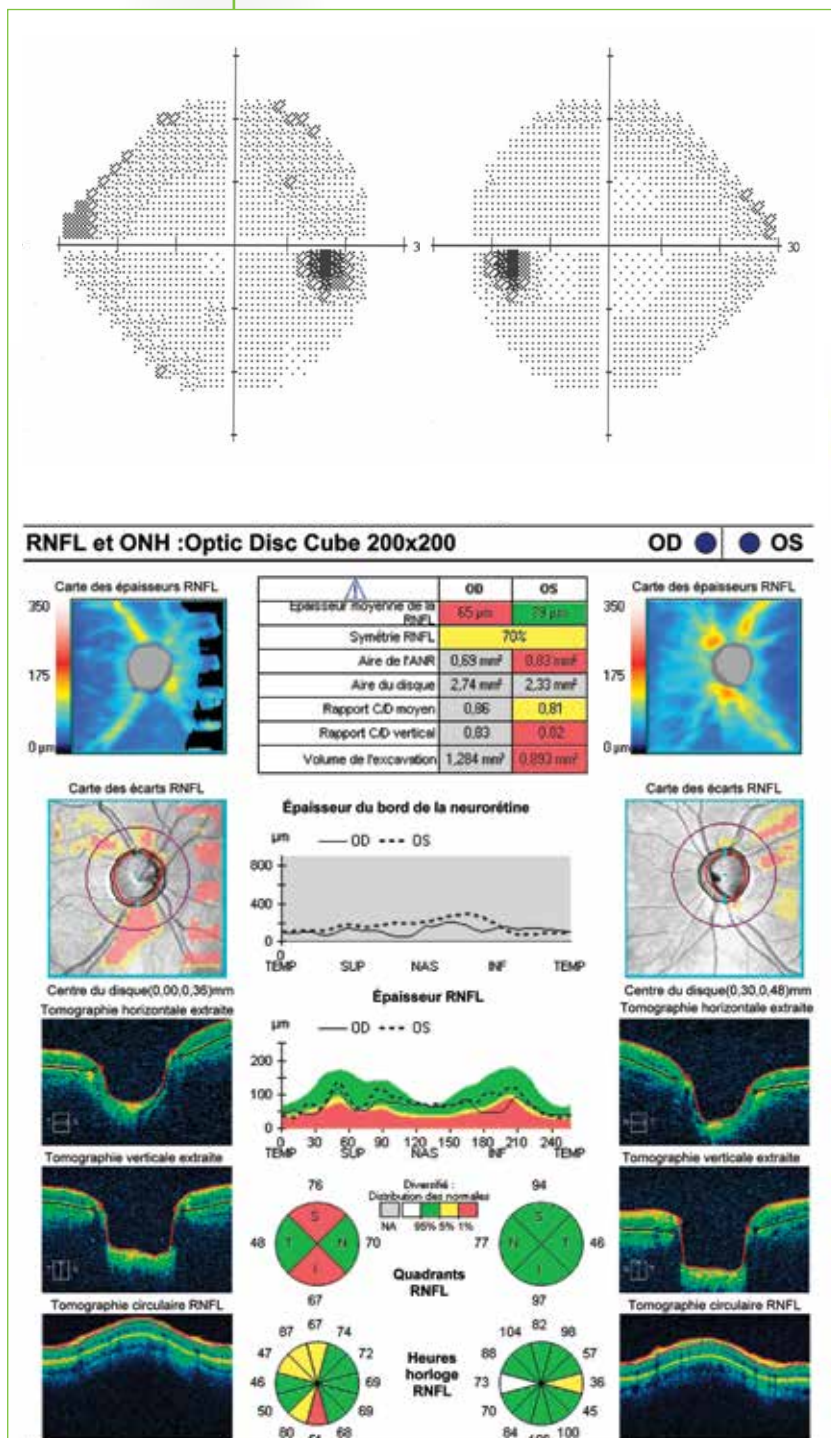


Macular cube OCT in the same patient as in Figure 35. There is significant macular impairment without loss of visual acuity or impairment of the central visual field.

Figure 36

Primary impairment of the optic nerve without impairment of the RNFL

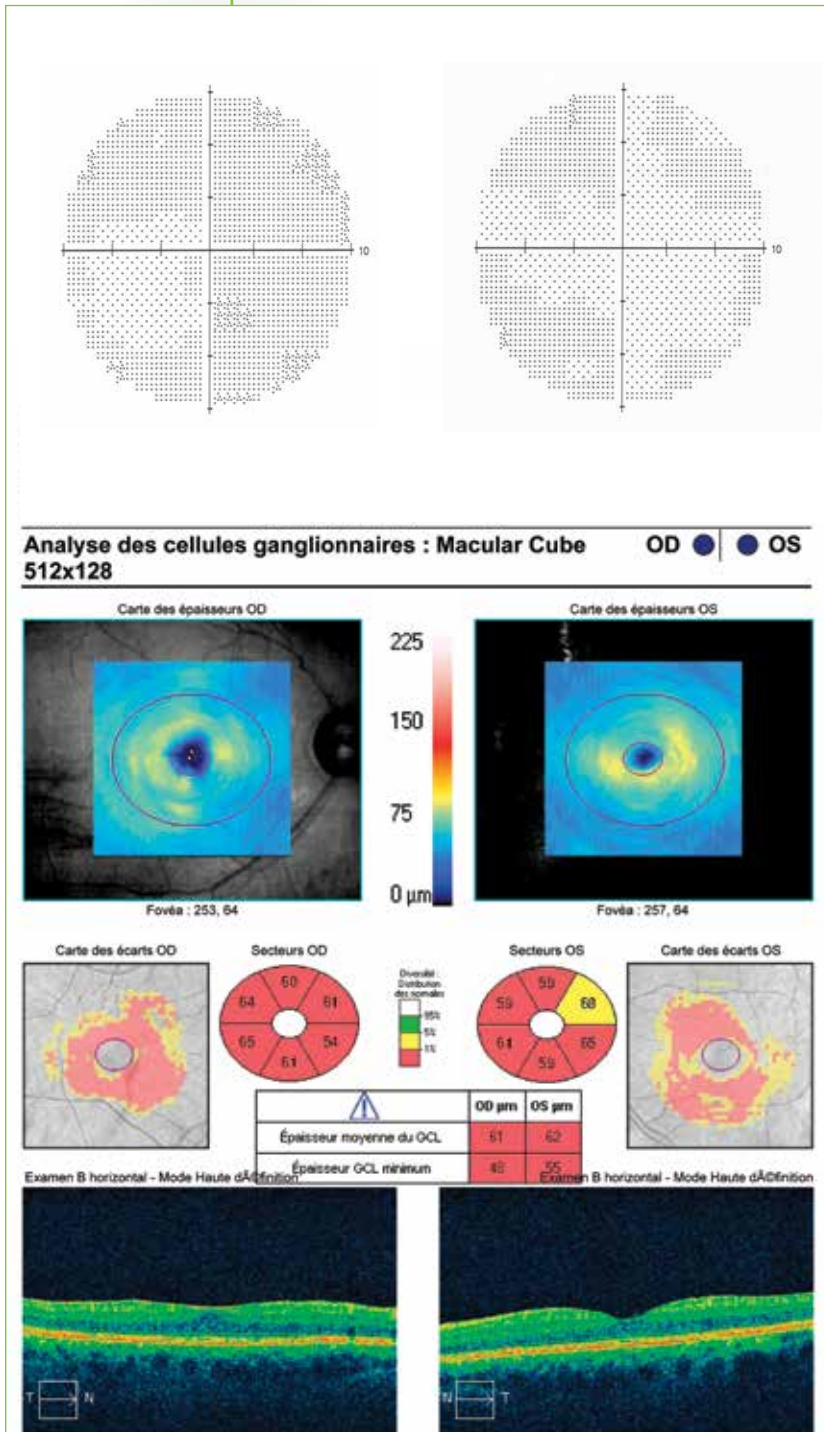
Importantly, the absence of RNFL layer thinning does not completely exclude the possibility of glaucoma. The presence of a cavity on clinical examination or OCT, associated with mild visual field impairment, should be taken as evidence of true glaucoma.



OCT of the RNFL and optic nerve, and visual field assessments, in a 68-year-old patient with ocular hypertension. In the right eye, OCT and visual field findings unequivocally show the presence of glaucoma. However, in the left eye, the RNFL is normal but all optic nerve parameters are abnormal. In this patient, glaucoma is clearly bilateral, and the slightly abnormal visual fields support this diagnosis.

Figure 37

This is illustrated in Figures 37 and 38, which show OCT findings in a 68-year-old patient with ocular hypertonia. OCT findings from the right eye unequivocally indicate the presence of glaucoma. In the left eye, however, the RNFL is normal but all optic nerve parameters are abnormal; in this case, the diagnosis is supported by the presence of abnormal visual fields (Figure 37). In the presence of a normal RNFL, analysis of the macular ganglion cells can differentiate between isolated hypertonia and early optic fibre impairment (Figure 38).



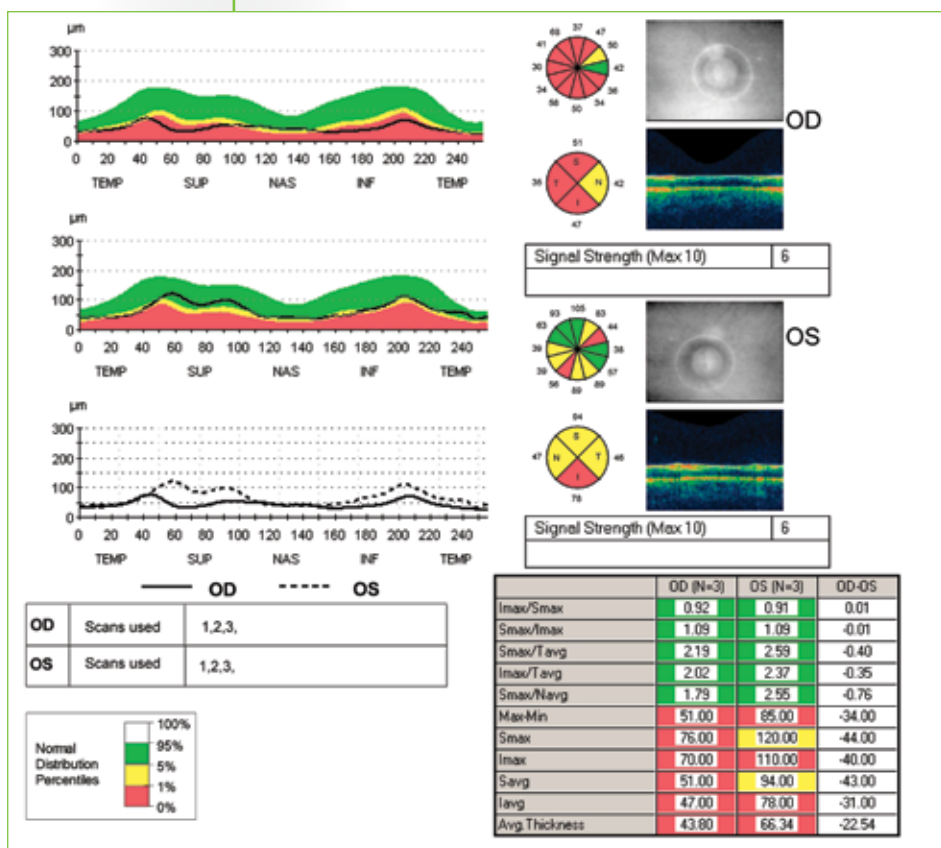
Macular cube OCT and central 10° visual fields in the same patient as in Figure 37. Bilateral impairment of the macular ganglion cell layer is present, but the central visual field is normal.

Figure 38

Comparison between time domain and spectral domain OCT in glaucoma with incipient open angle

Comparisons between time domain OCT (Stratus OCT, Carl Zeiss) and spectral domain OCT (Cirrus™ HD-OCT, Carl Zeiss) show that the two methods are comparable in terms of their ability to identify incipient glaucoma (Figure 39).

The principal difference between them is that spectral domain OCT is more reproducible, and therefore allows better monitoring than time domain OCT¹⁰.



Time domain OCT (a) and spectral domain OCT (b) images from a patient with incipient glaucoma. The two techniques provide similar results.

Figure 39a

However, the results obtained with the two techniques are not identical; in particular, in patients with severe glaucoma there may be 10–20% variability.

Furthermore, the colour codes used in the displayed results from Stratus OCT and Cirrus™ HD-OCT are not interchangeable and, in general, the measured thickness of the RNFL is lower with the Cirrus than with the Stratus device.

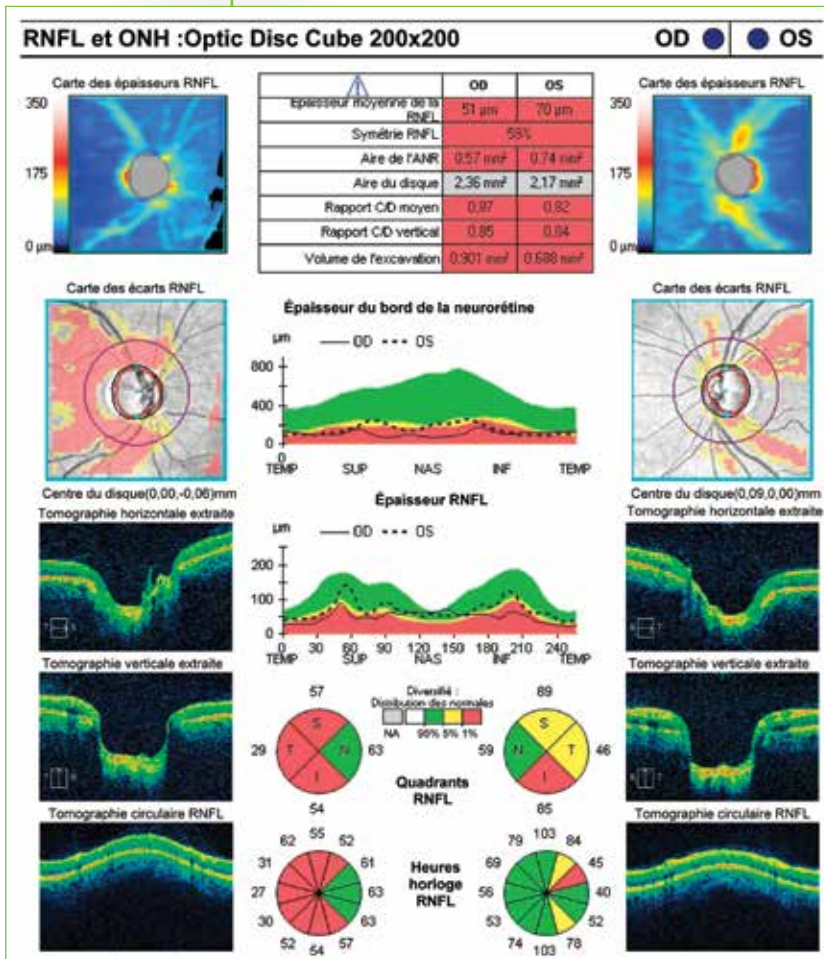
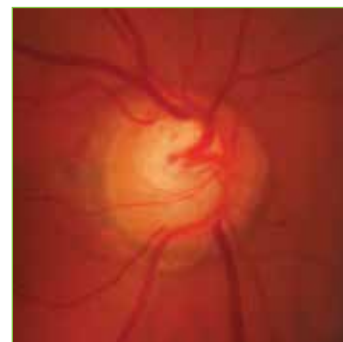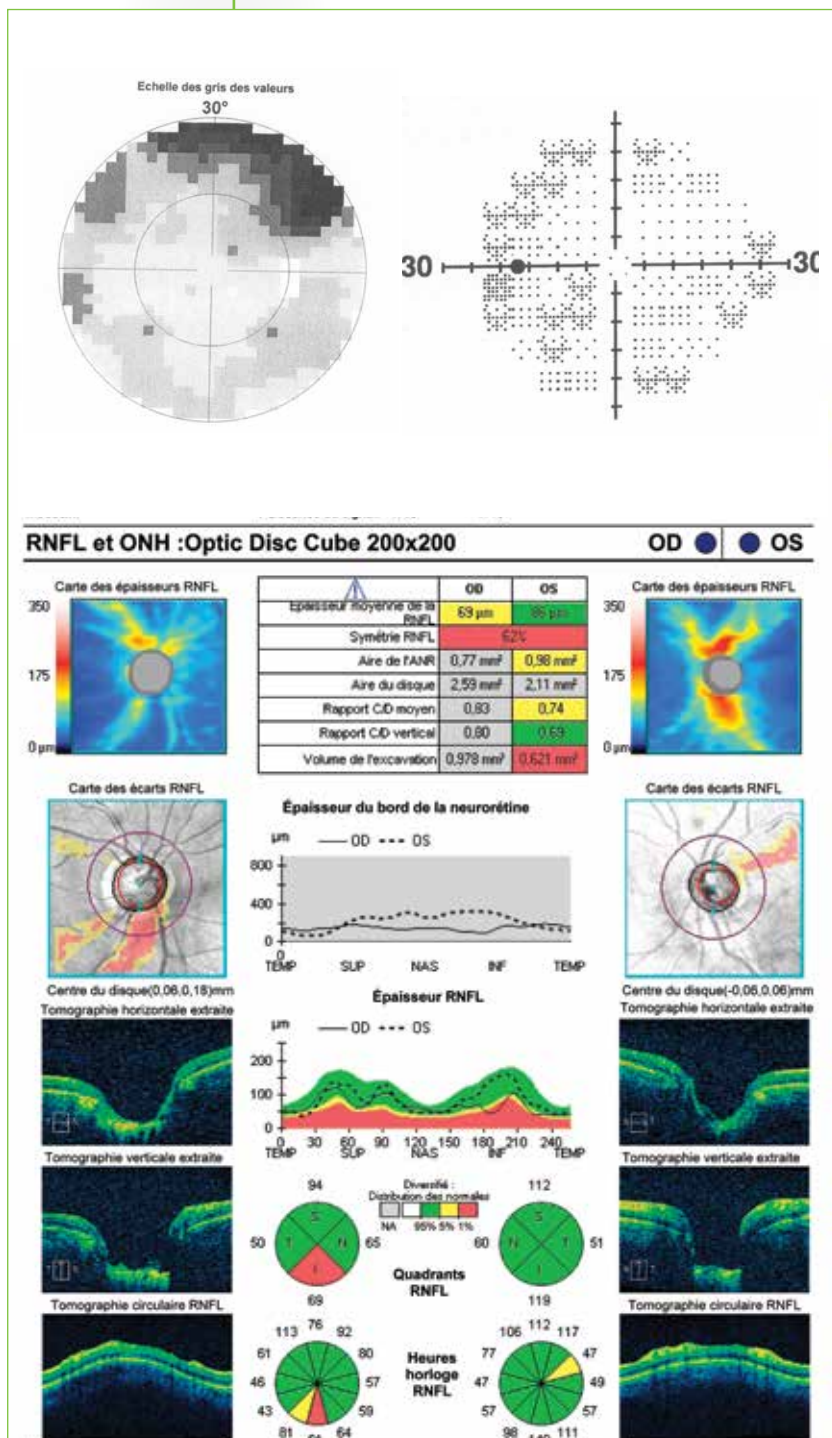


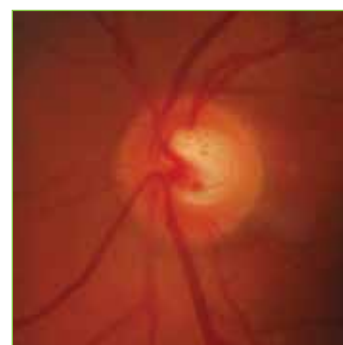Figure 39b

Moderate open angle glaucoma: concordance of OCT findings and visual field testing

In patients with moderate open-angle glaucoma, perfect concordance between OCT and visual field testing is rare, because in many cases OCT can detect more serious impairment than perimetry testing.



Right eye

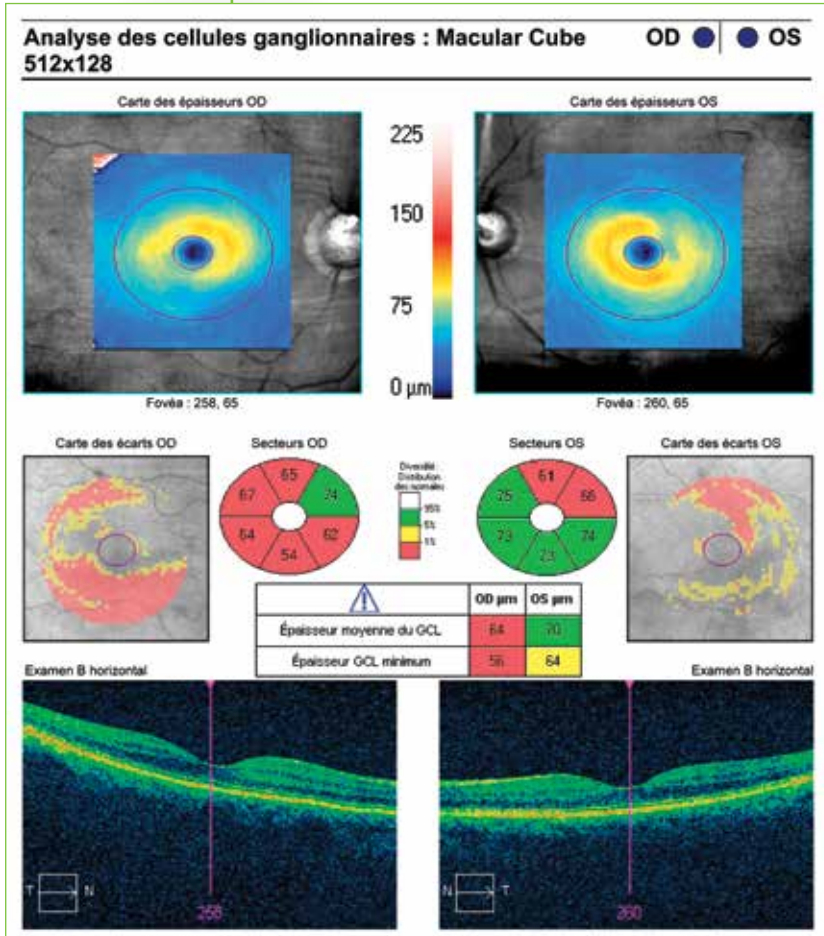


Left eye

OCT of the RNFL and visual field testing in a patient with moderate open-angle glaucoma. Visual field testing shows a marked deficit, but OCT shows RNFL involvement only in the lower concordant region of the right eye.

Figure 40

Results from a patient with moderate glaucoma are shown in Figures 40 and 41. Visual field testing shows a marked deficit, but OCT shows RNFL involvement only in the lower concordant region of the right eye (Figure 40). Analysis of macular ganglion cells (Figure 41) confirms this impairment, which is concordant with the results of visual field testing, but also shows subclinical impairment in the upper region and in the left eye.

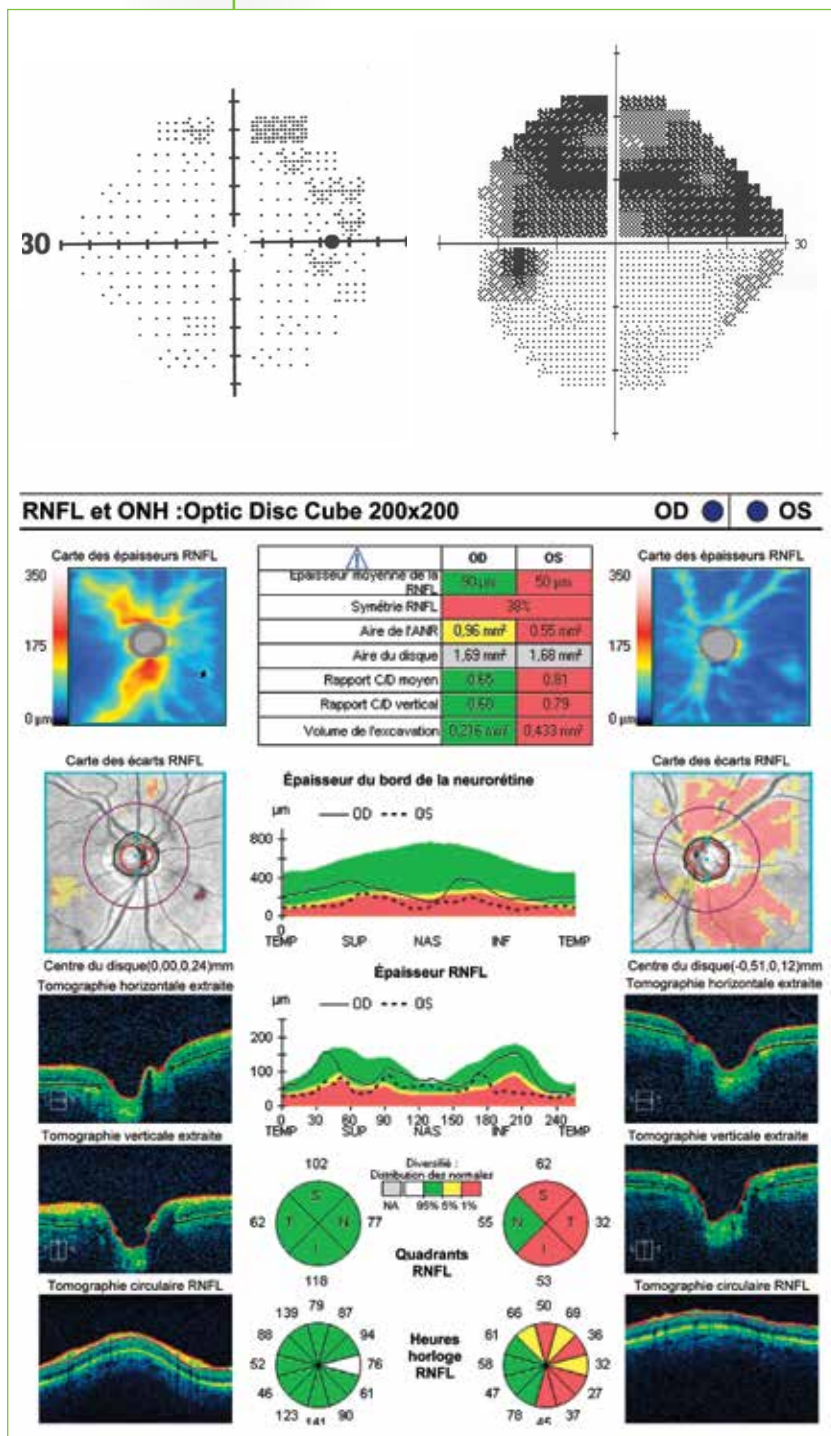


Macular cube OCT from the same patient as in Figure 40. Impairment of the macular ganglion cells is concordant with the results of visual field testing, but subclinical impairment is also present in the upper region and in the left eye.

Figure 41

Moderate open angle glaucoma: predominant OCT impairment

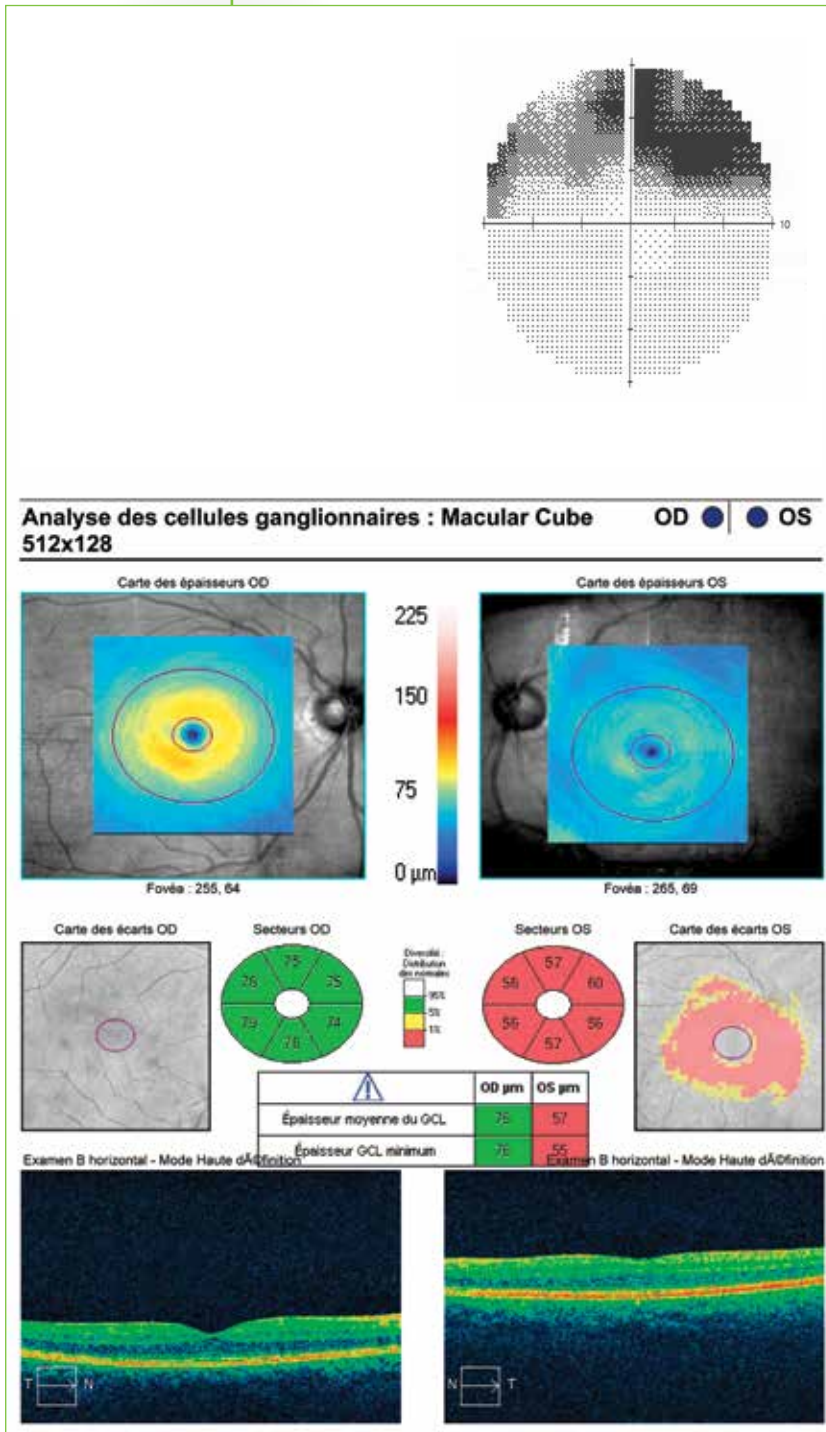
In patients with moderate glaucoma, OCT impairment is sometimes more significant than would be expected from visual field testing alone. Hence, in addition to confirming perimetric deficits, OCT can be very useful in the investigation of other regions that appear normal in visual field testing.



OCT findings in the RNFL and visual field test results in a patient with moderate glaucoma. RNFL impairment is seen in both the lower and upper concordant regions of the left eye. Both Matrix visual field testing and OCT findings are normal in the right eye.

Figure 42

An example of this situation is shown in Figures 42 and 43. In this patient, OCT reveals RNFL thinning in both the upper and lower regions (Figure 42), together with subclinical impairment of macular ganglion cells in the upper region (Figure 43).



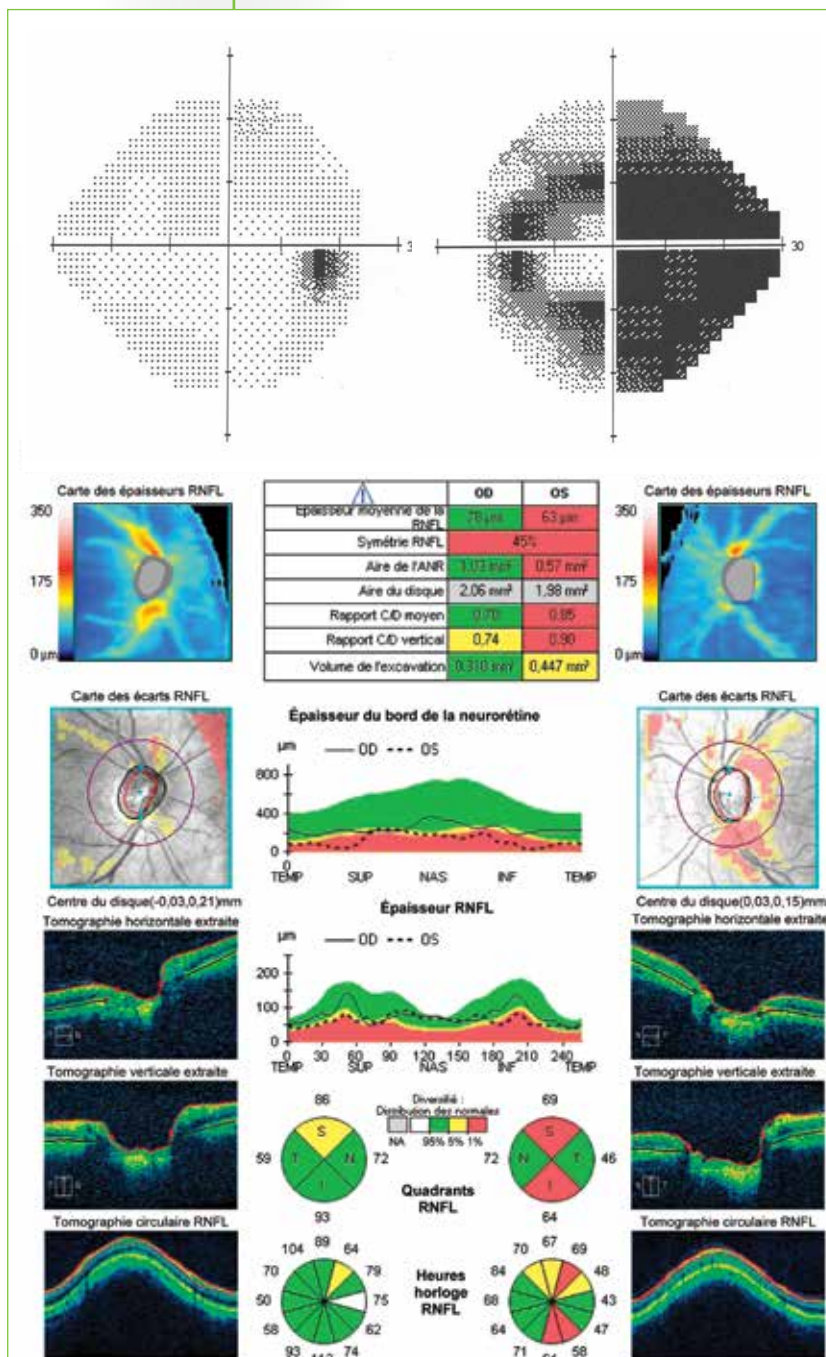
Macular cube OCT and central 10° visual fields in the same patient as in Figure 42. Analysis of macular ganglion cells confirms that impairment is concordant with visual field testing, but also shows subclinical impairment in the upper region. The right eye is entirely normal.

Figure 43

In patients with advanced glaucoma, OCT findings can confirm the presence of structural damage but the diagnosis is based predominantly on visual field testing. Indeed, beyond a certain point in advanced glaucoma, there is no further decrease in the thickness of the RNFL or macular ganglion cells, despite the presence of optical atrophy, because support structures account for the residual thickness of the RNFL.

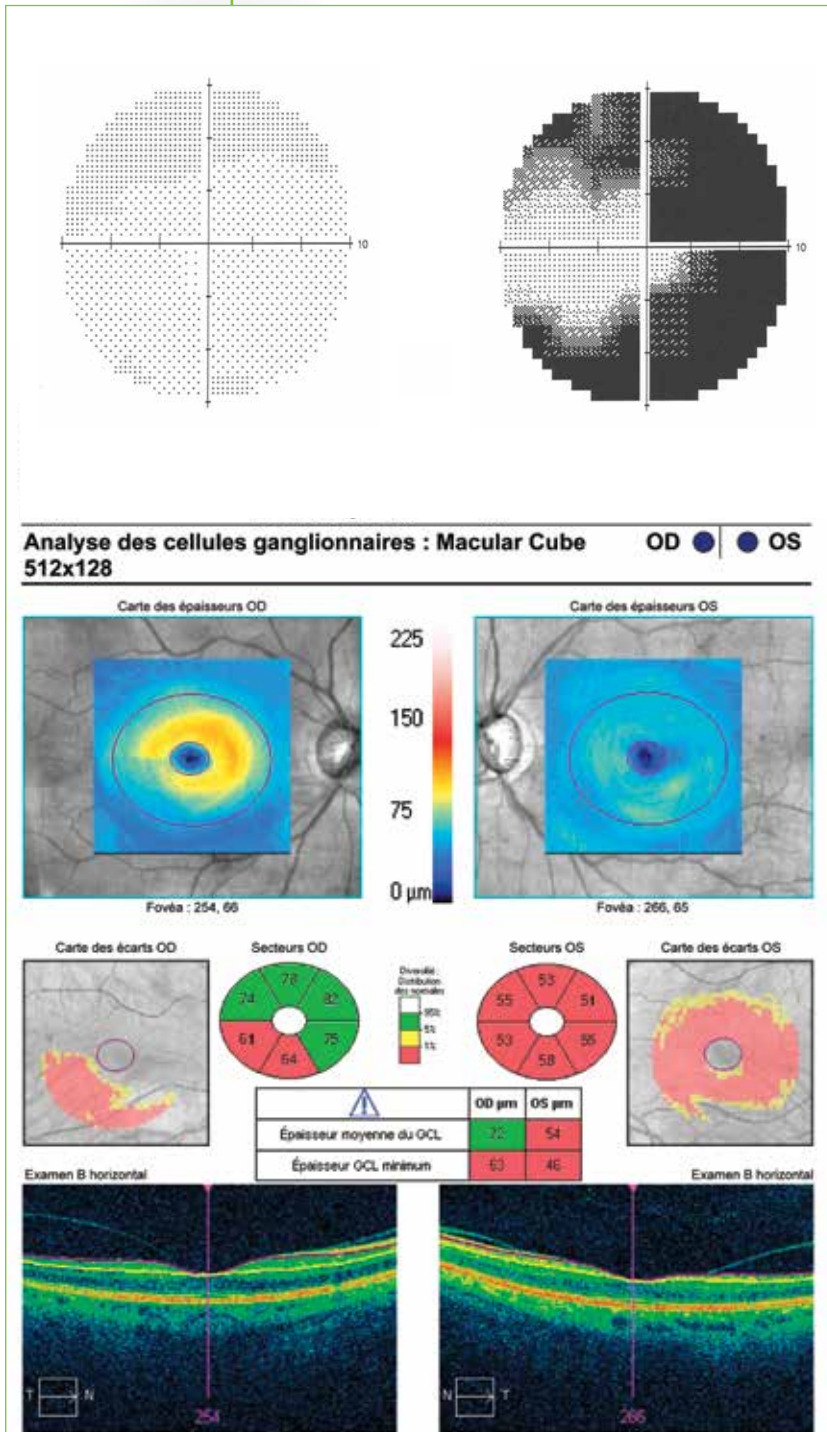
Advanced open-angle glaucoma: concordant impairment on OCT and visual field testing

In advanced glaucoma, the RNFL regions corresponding to regions of absolute deficit on visual field testing are about 50 μm thick (Figures 44 and 45).



OCT findings in a 61-year-old patient with glaucoma predominantly affecting the left eye. The OCT profile shows preferential impairment in the upper and lower sectors, with relative preservation of the temporal fasciculus.

Figure 44

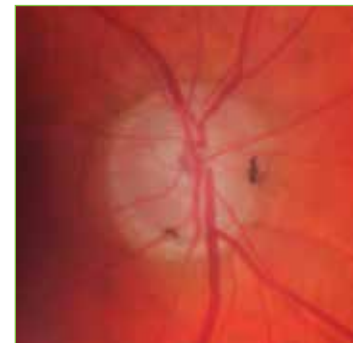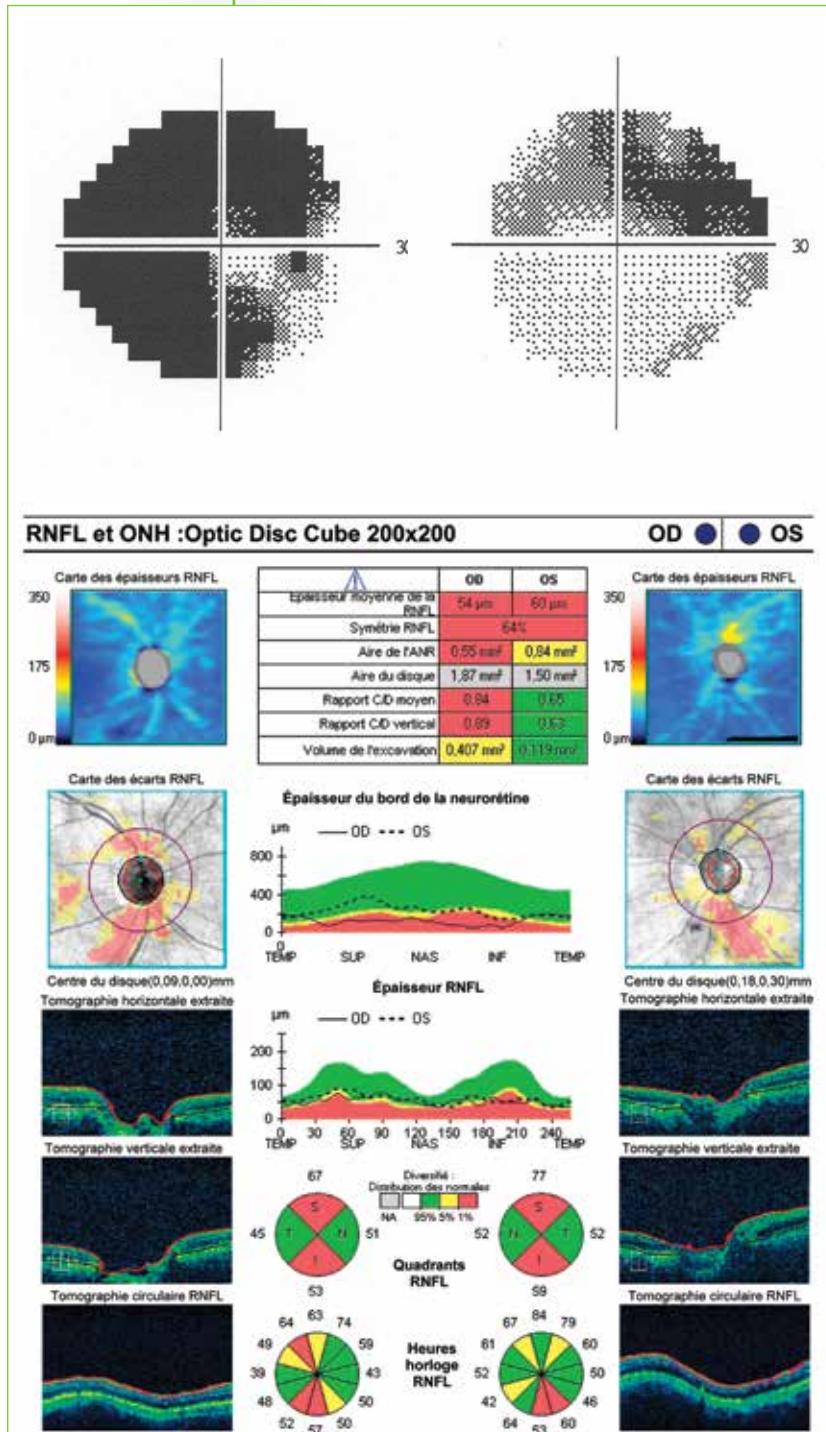


Macular cube OCT and central 10° visual fields from the same patient as in Figure 44. Moderate impairment is present in the right eye, whereas all macular regions are affected in the left eye (the eye mostly affected by glaucoma). Note that a difference in thickness of 15 μm to 20 μm separates areas of incipient deficit (right eye) and absolute deficit (left eye).

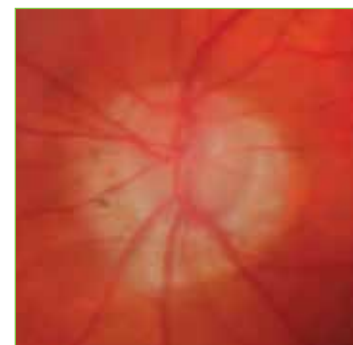Figure 45

Advanced open-angle glaucoma: predominant impairment of the visual field

In the most advanced stages of glaucoma, it is difficult to rely on measurements of cell layer thickness, either at the papillary or macular level, because only slight reductions are seen in this situation (Figures 46 and 47).



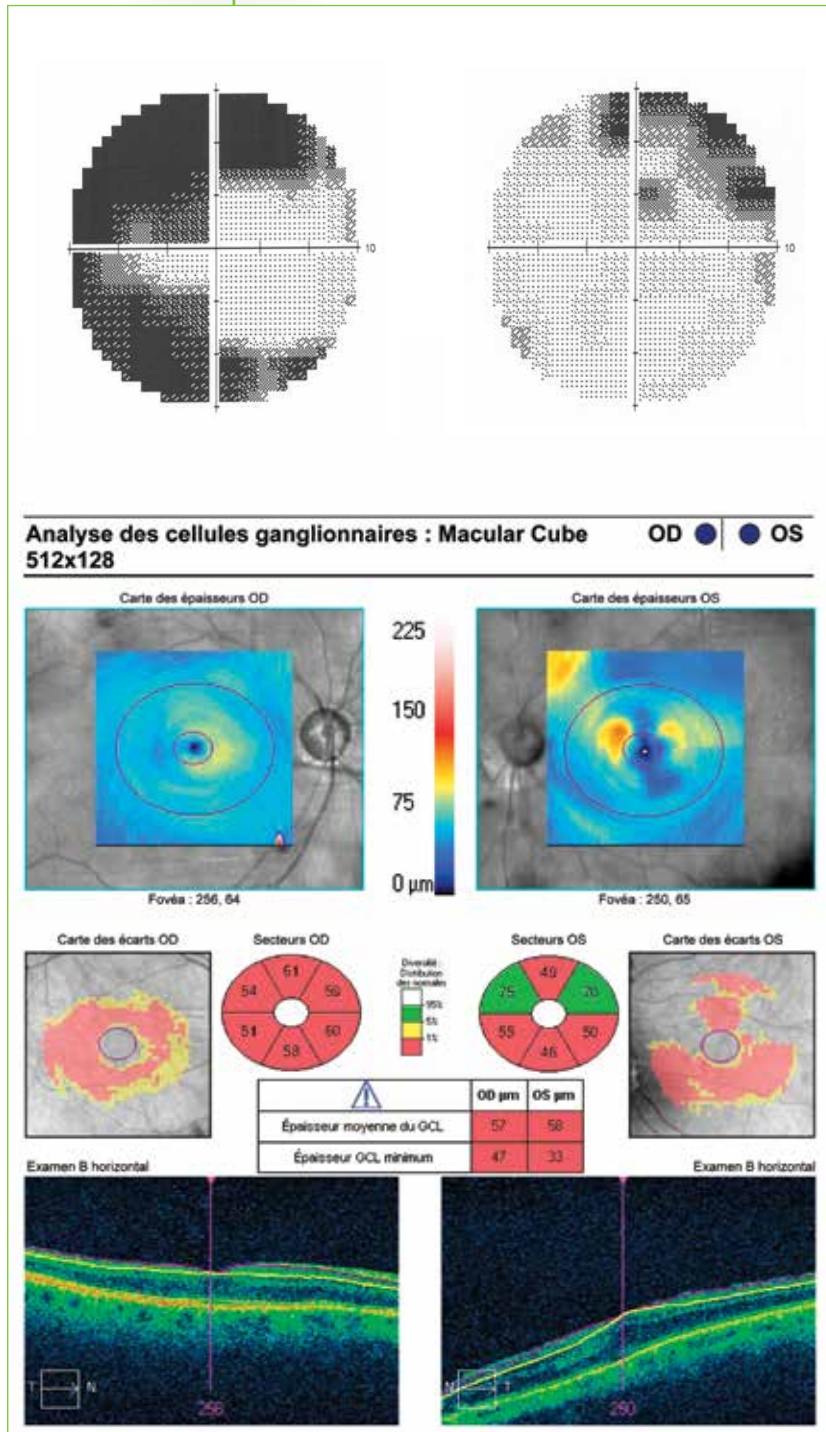
Right eye



Left eye

OCT findings in an 84-year-old patient with advanced glaucoma and reduced visual acuity in the right eye. On this side, the visual field mean deviation (MD) is -26dB, compared with -11dB in the left eye. OCT differences between the eyes are less pronounced, with a mean RNFL thickness of 54 µm in the right eye and 60 µm in the left eye.

Figure 46

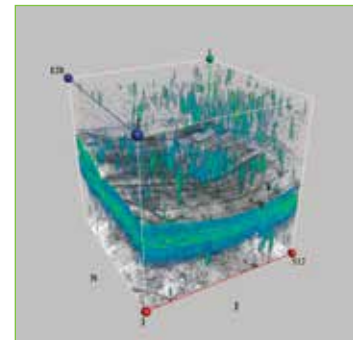
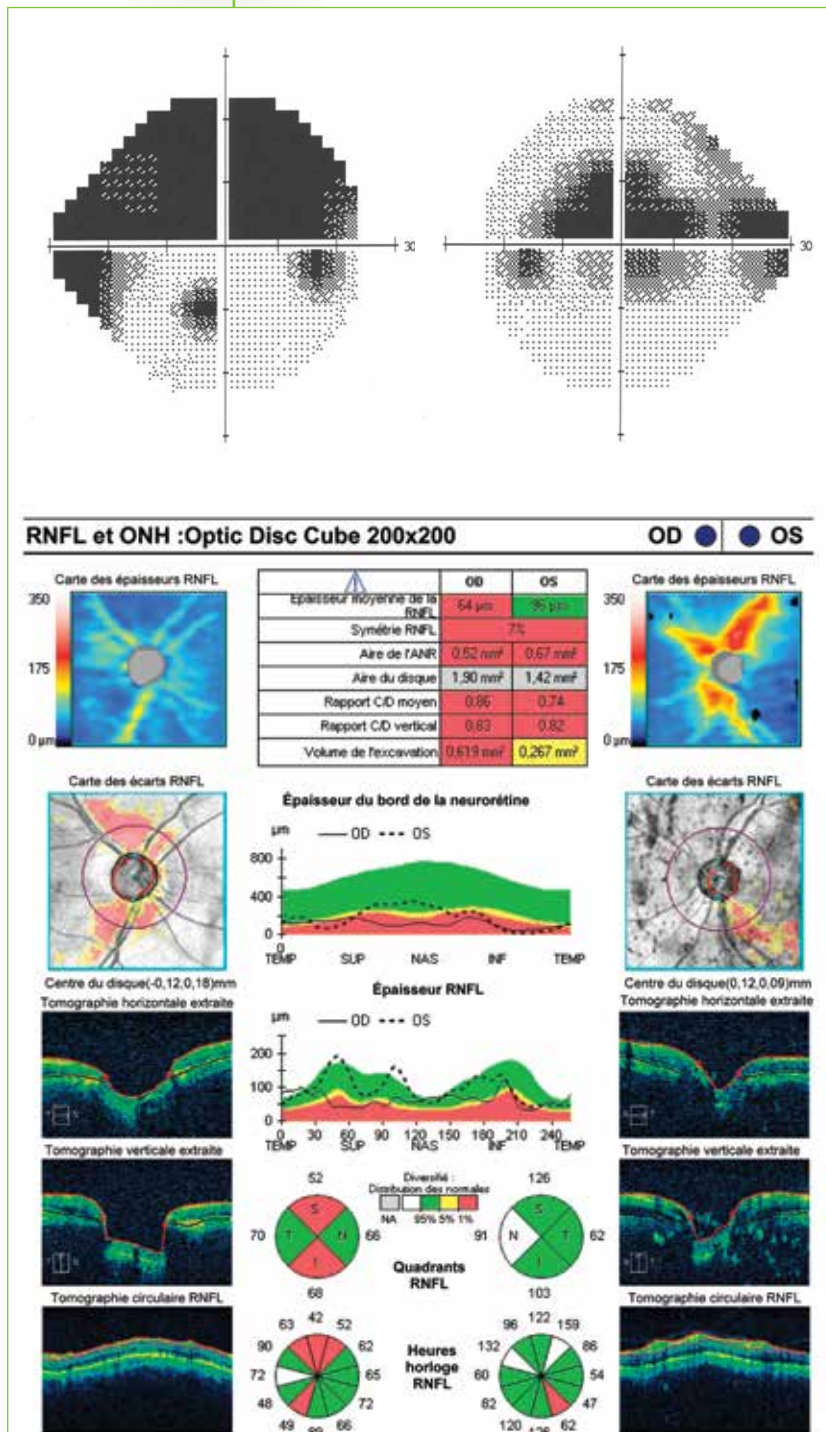


Macular cube OCT and central 10° visual fields from the same patient as in Figure 46. OCT. Again, there is no clear correlation between visual field deficits and the thickness of the ganglion cell complex: the MD is -20dB in the right eye and -9dB in the left eye, and the mean thickness of the macular fibres is 57 μm and 58 μm , respectively.

Figure 47

Advanced open-angle glaucoma: discordance between findings on OCT and visual field testing

In some cases, only moderate impairment can be seen on OCT despite obviously abnormal visual fields. This could be a genuine finding, or a result of measurement errors due to poor signal quality.

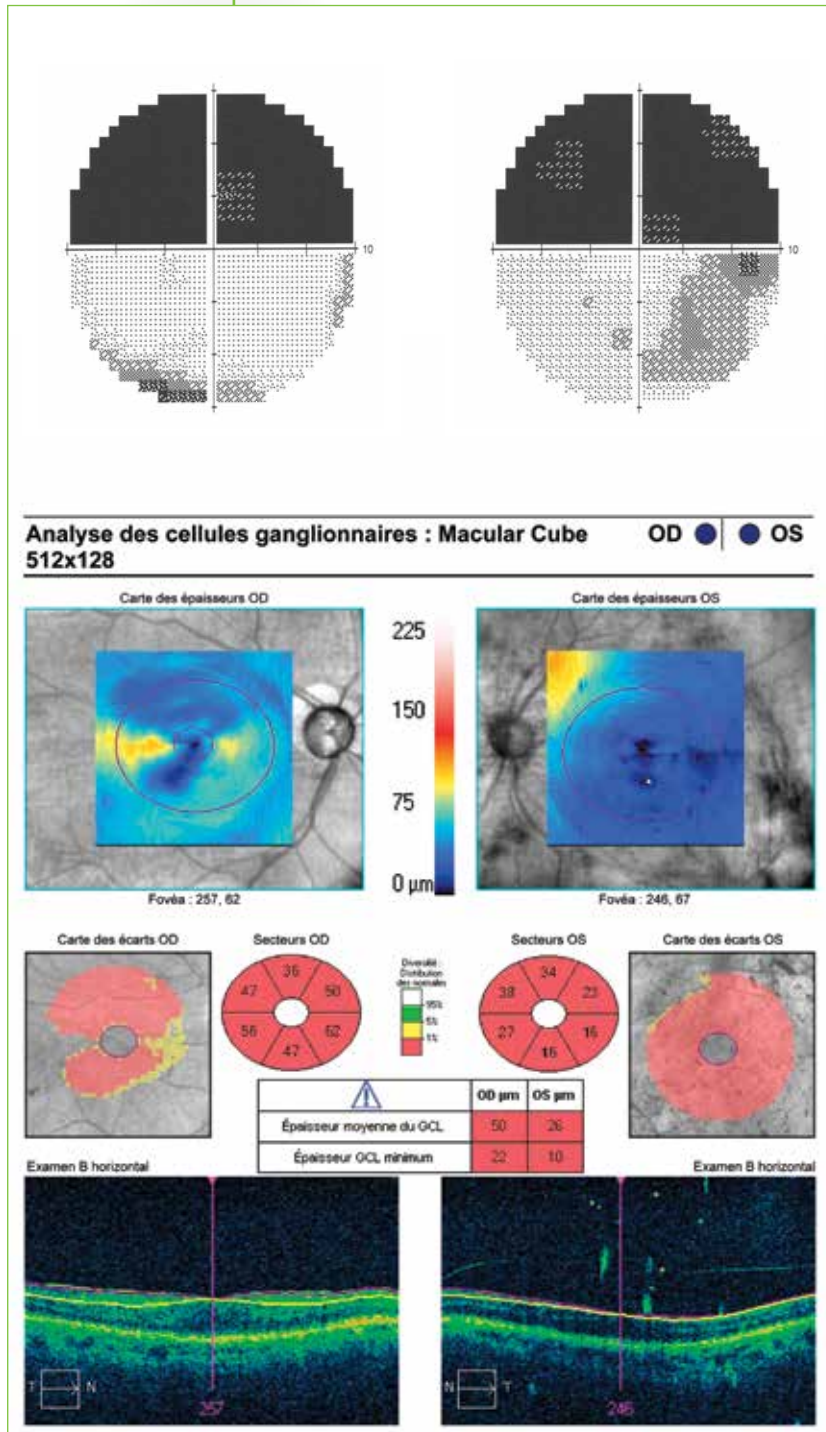


'Drop' aspect associated with vitreous opacities of the left eye

OCT findings in a 65-year-old female patient with almost symmetrical bilateral glaucoma. Despite similar visual field abnormalities in both eyes, the RNFL only appears to be abnormal in the right eye. This could be due to measurement errors associated with serious sparkling synchysis of the left eye, which is well visualised by OCT and leads to decreased signal quality.

Figure 48

In the case shown in Figures 48 and 49, for example, abnormalities in the RNFL are seen only in the right eye, despite the presence of almost symmetrical bilateral visual field impairment. This could be due to the formation of crystalline opacities resulting from liquefaction of the vitreous body (synchysis) in the left eye, which decreases the signal quality in OCT.

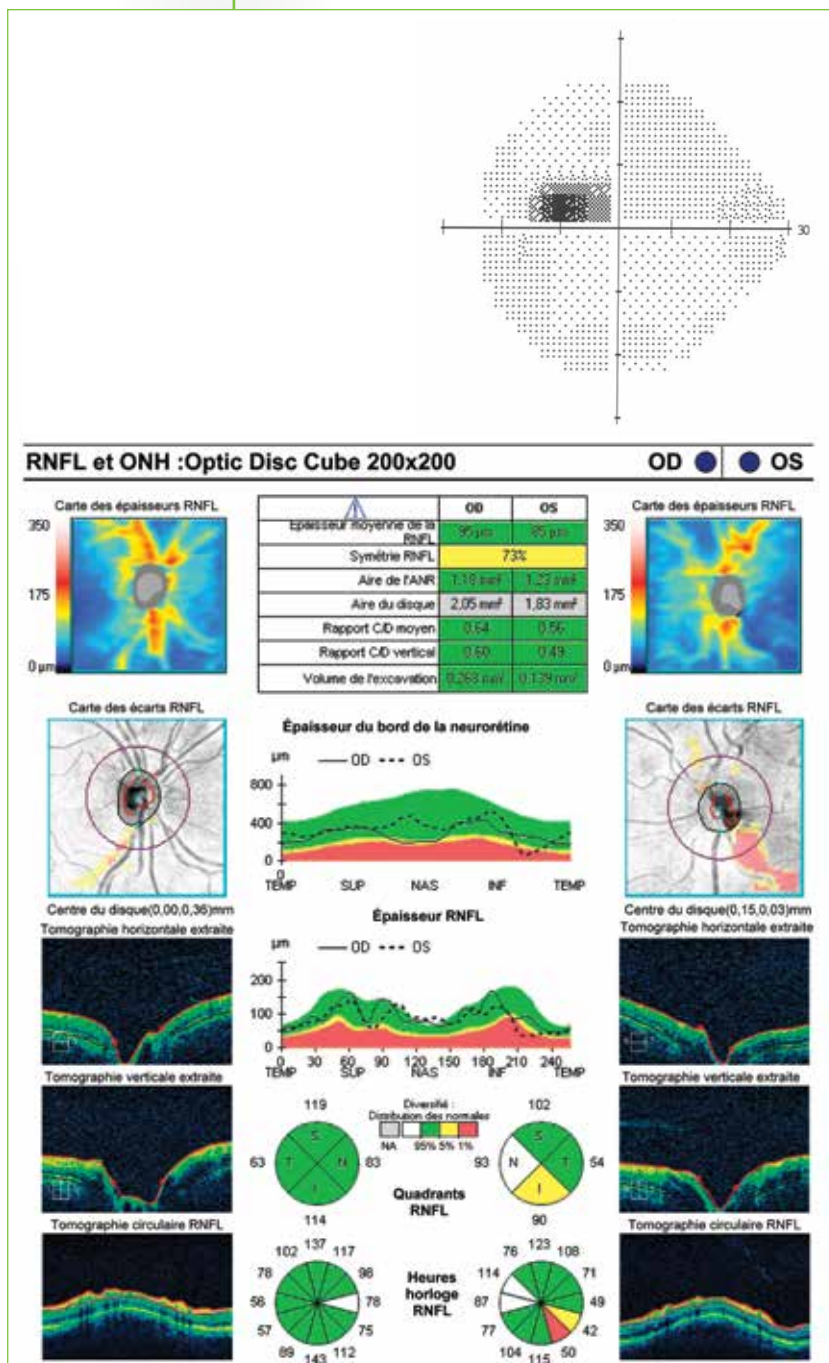


Macular cube OCT and central 10° visual fields in the same patient as in Figure 48. Macular abnormalities are shown on OCT in both eyes.

Figure 49

Normal-pressure glaucoma

In normal-pressure glaucoma, impairment of the central 10° of the visual field is often observed. Due to the high number of ganglion cells in this central region, this is reflected in a marked reduction in the retinal ring area, and hence in major hollowing (excavation; also known as cupping) of the optic nerve head in the advanced stage. The same characteristics can be seen on OCT. In addition, an isolated or predominant impairment of the macular region may be present in many cases; indeed, this is characteristic of early-stage normal-pressure glaucoma.

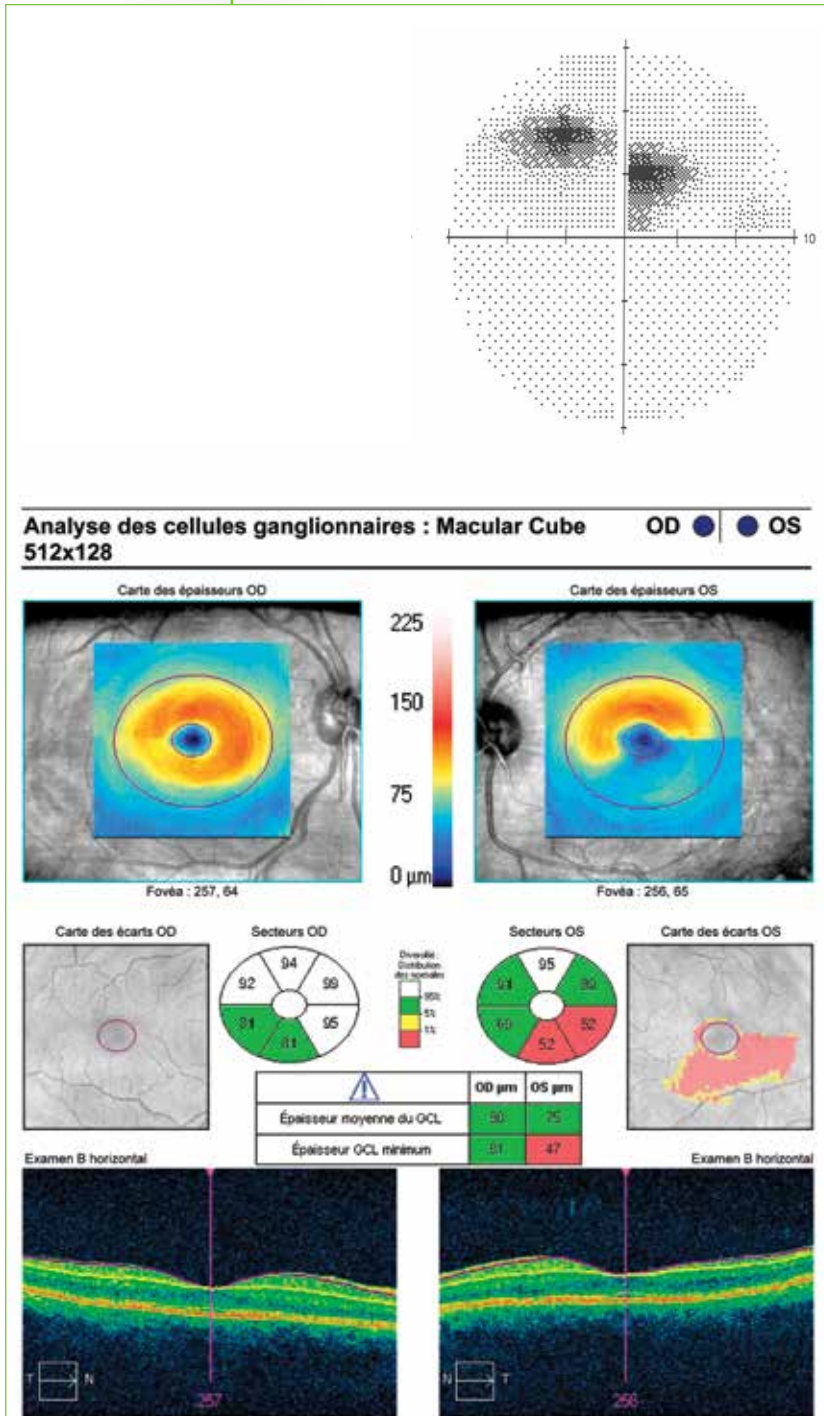


OCT findings from a 60-year-old patient, with an ocular pressure of 15 mmHg without treatment. A slight fasciculate deficit, affecting both the optic nerve and the para-papillary fibres, is observed in the left eye; optic nerve parameters are normal. The results for the right eye are normal.

Figure 50

Normal-pressure glaucoma: isolated fascicular deficit

An isolated deficit may be found in patients with normal-pressure glaucoma, which manifests as a notch in the optical nerve head and the RNFL (Figures 50 and 51).

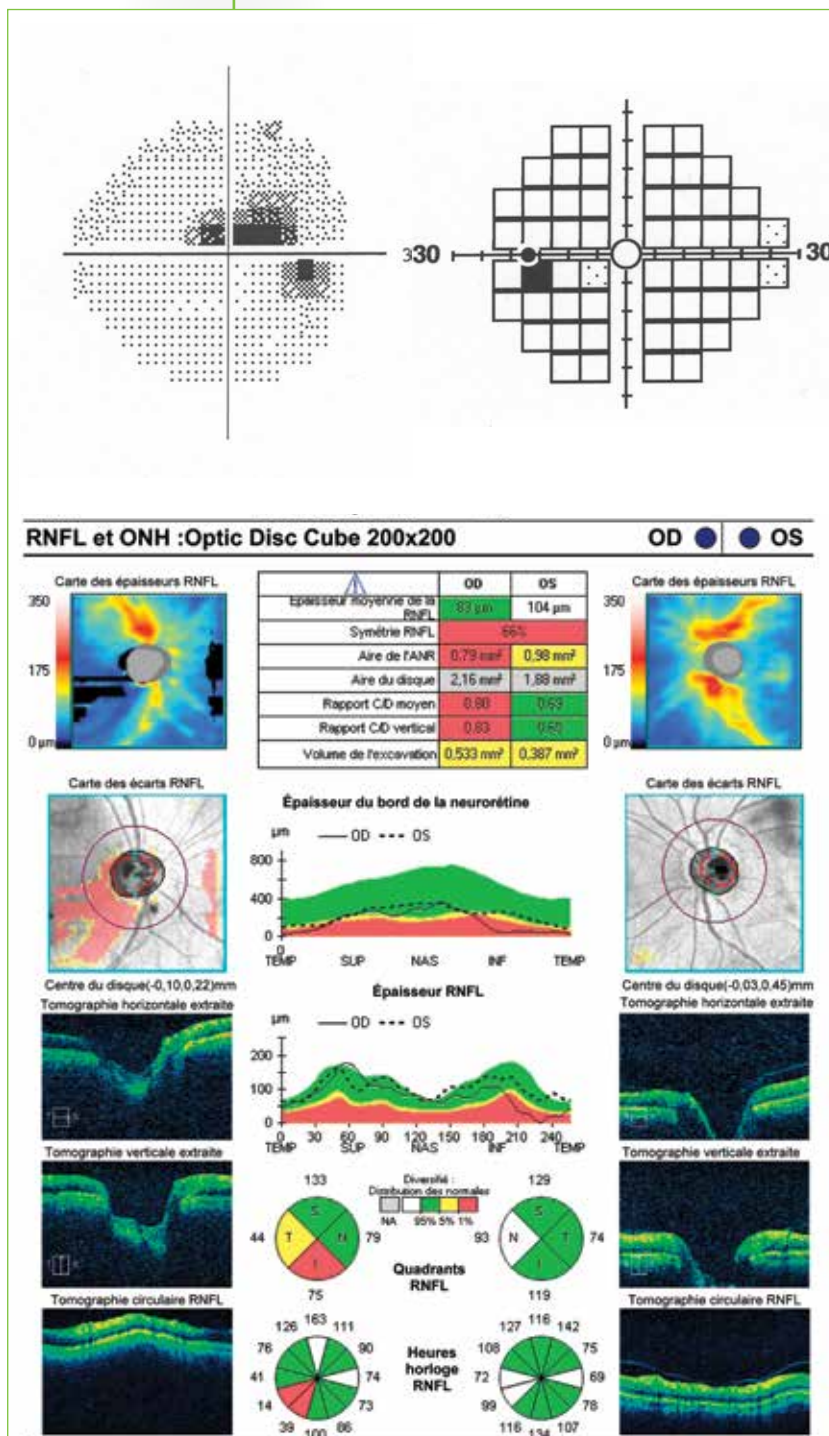


Macular cube OCT and central 10° visual fields from the same patient as in Figure 50. There is highly localized impairment of the left macular ganglion cell complex.

Figure 51

Incipient normal-pressure glaucoma

In the early stages of normal-pressure glaucoma, the mean RNFL is reduced less than in hypertonic glaucoma (Figures 52 and 53), because the affected fasciculi are finer ¹².

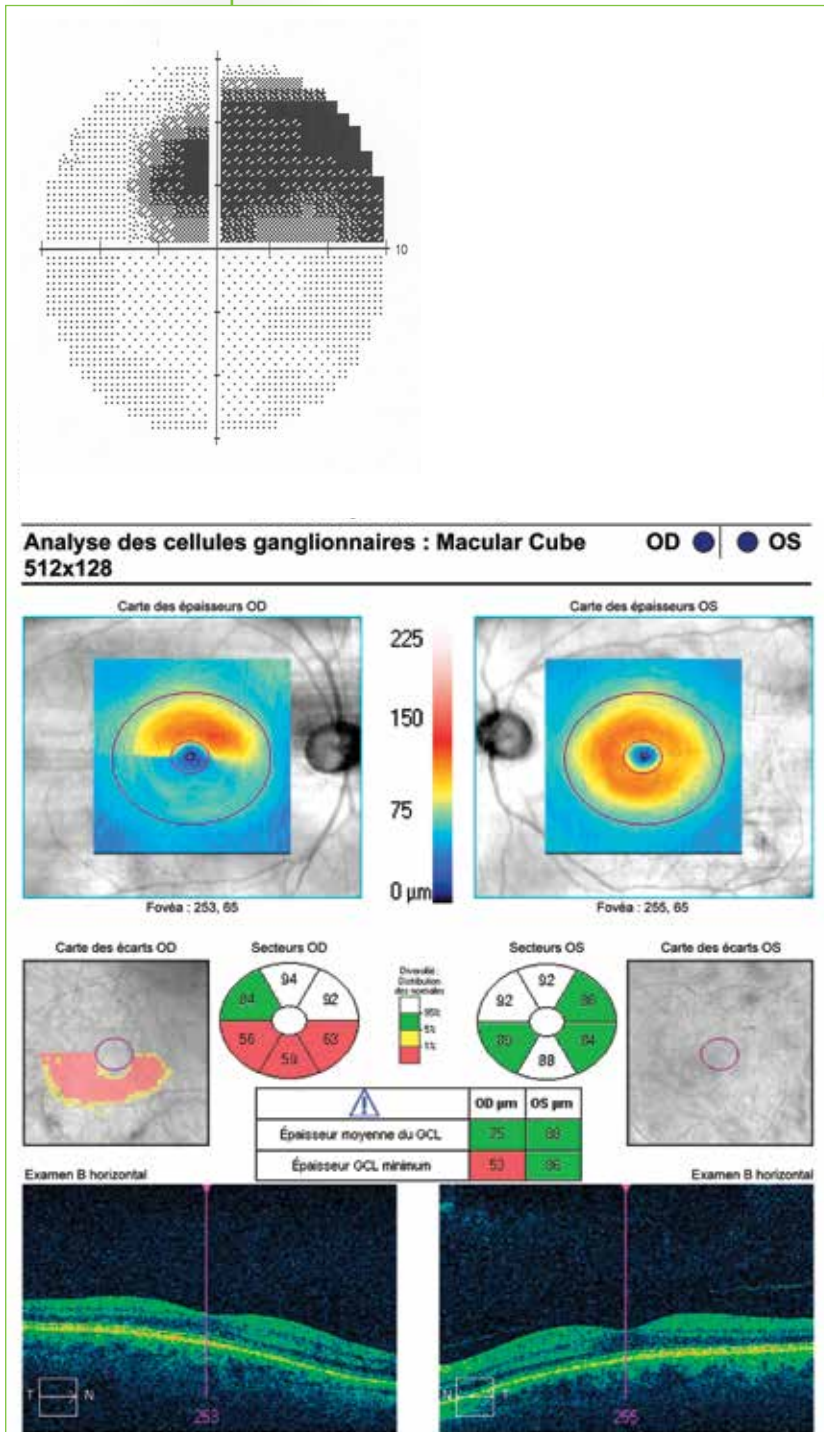


OCT findings in a 68-year-old female patient with an ocular pressure of 16 mmHg without treatment. OCT shows localized impairment in the right eye: the mean RNFL thickness is not reduced, but there are significant changes in optic nerve parameters.

Figure 52

In the patient shown in Figure 52, the mean RNFL thickness is not affected, but the optic nerve parameters do show significant changes. The RNFL thickness in the macular region may be gradually reduced without producing loss of visual field.

Paracentral scotomas in normal-pressure glaucoma are deep and absolute, and there is only a brief relative scotoma phase.

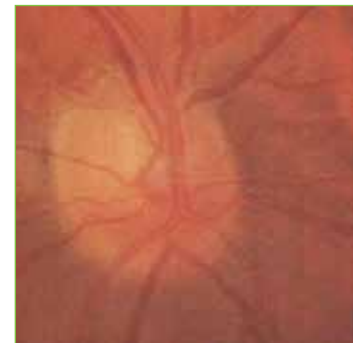
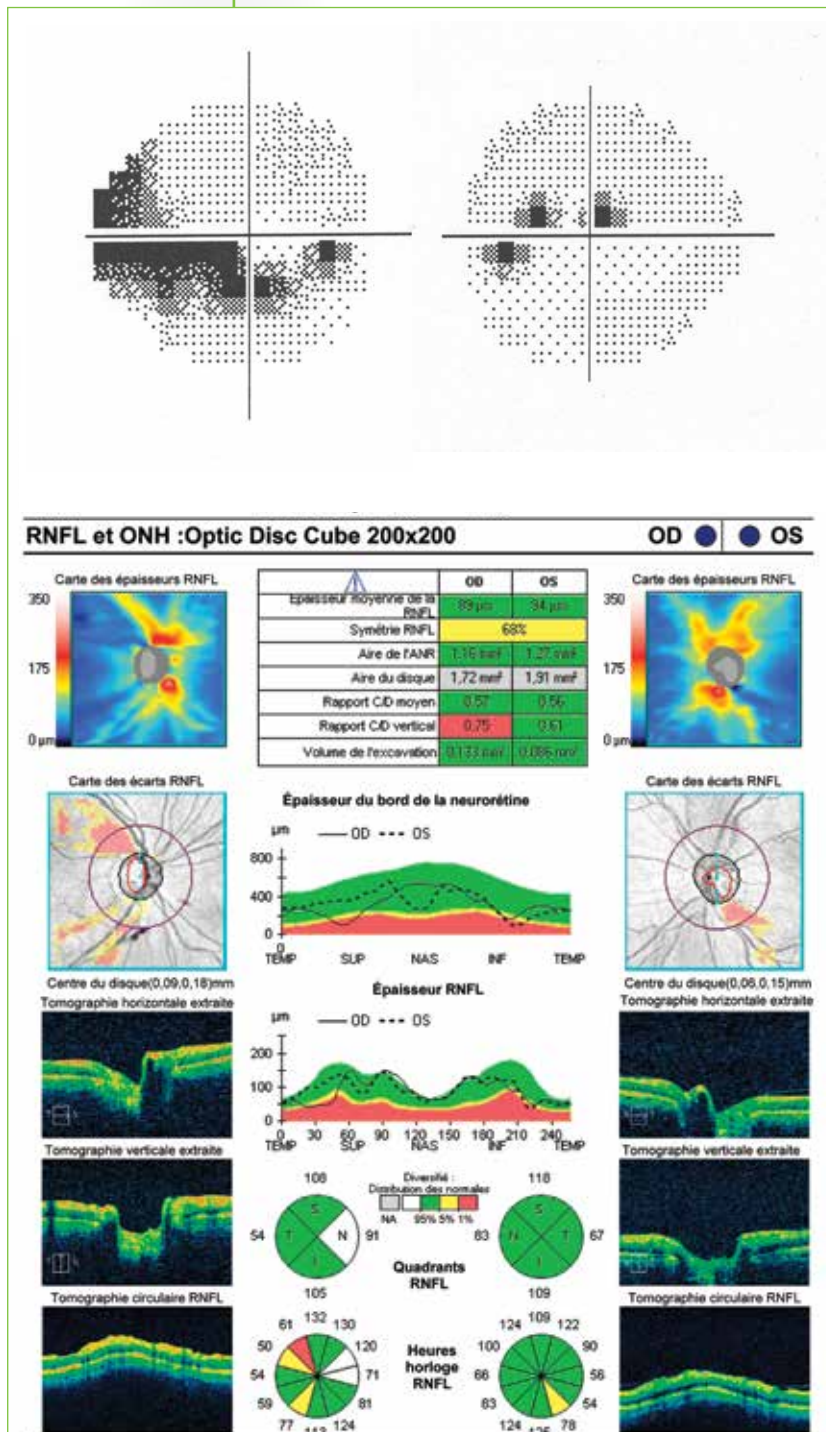


Macular cube OCT and central 10° visual fields in the same patient as in Figure 52. There is very localised lower macular impairment, concordant with the perimetric deficit.

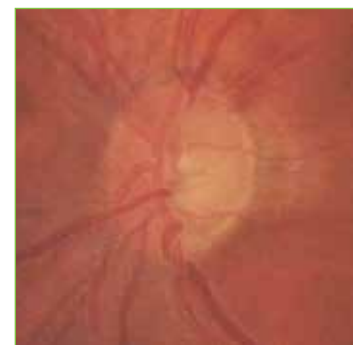Figure 53

Moderate normal-pressure glaucoma

Changes in OCT measurements between normal-pressure glaucoma and high pressure glaucoma become apparent during the early stages of the disease (Figures 54 and 55). When glaucoma is more advanced, resulting in more specific impairments of visual fields, these differences gradually disappear.



Right eye



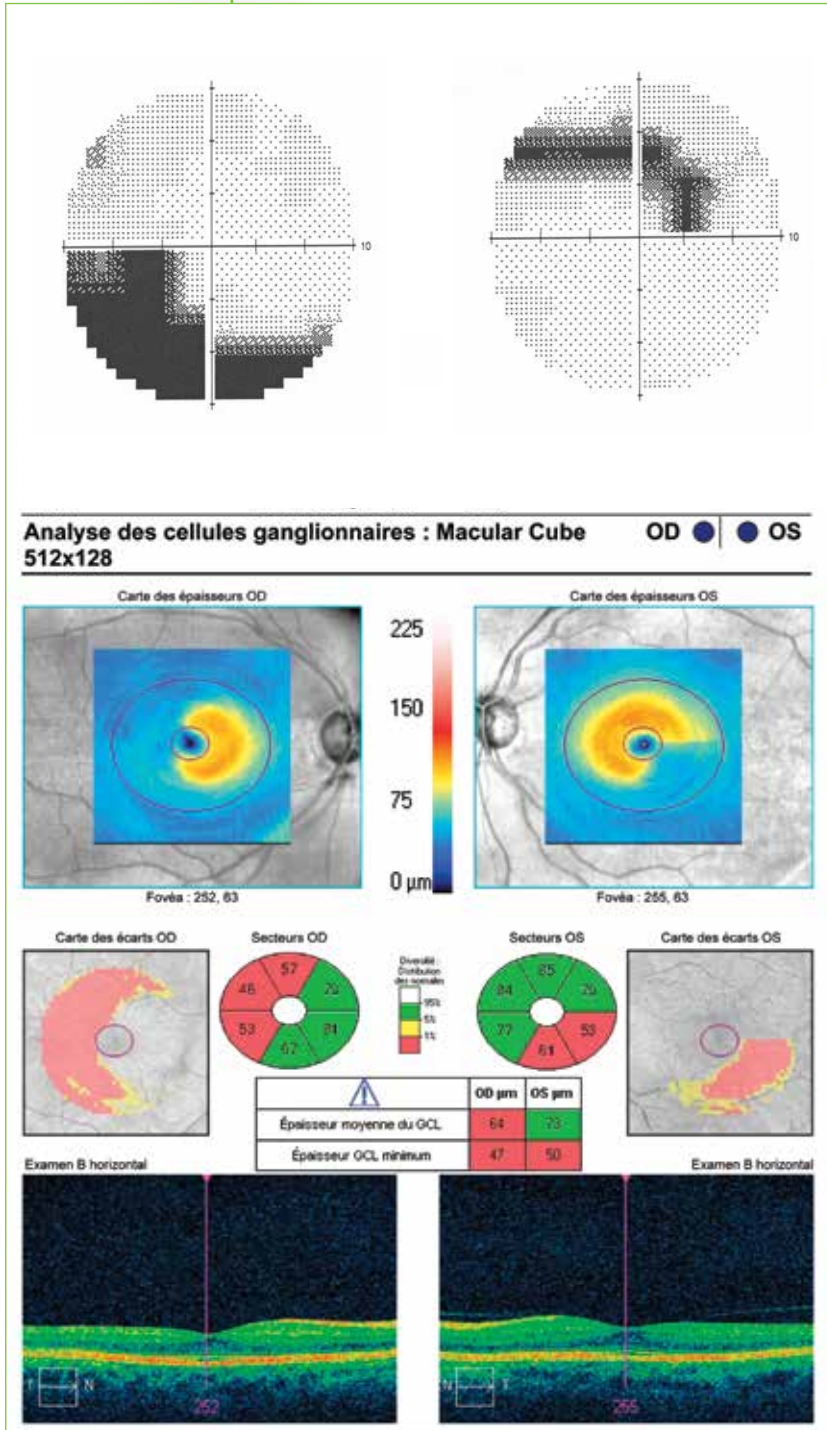
Left eye

OCT findings in a 60-year-old patient with normal-pressure glaucoma. The right eye shows the usual indications of open-angle glaucoma, with a nasal step and arcuate scotoma.

The thickness of the RNFL remains relatively unchanged: a small paracentral scotoma can be seen on the left, which only slightly alters the thickness of the RNFL.

Figure 54

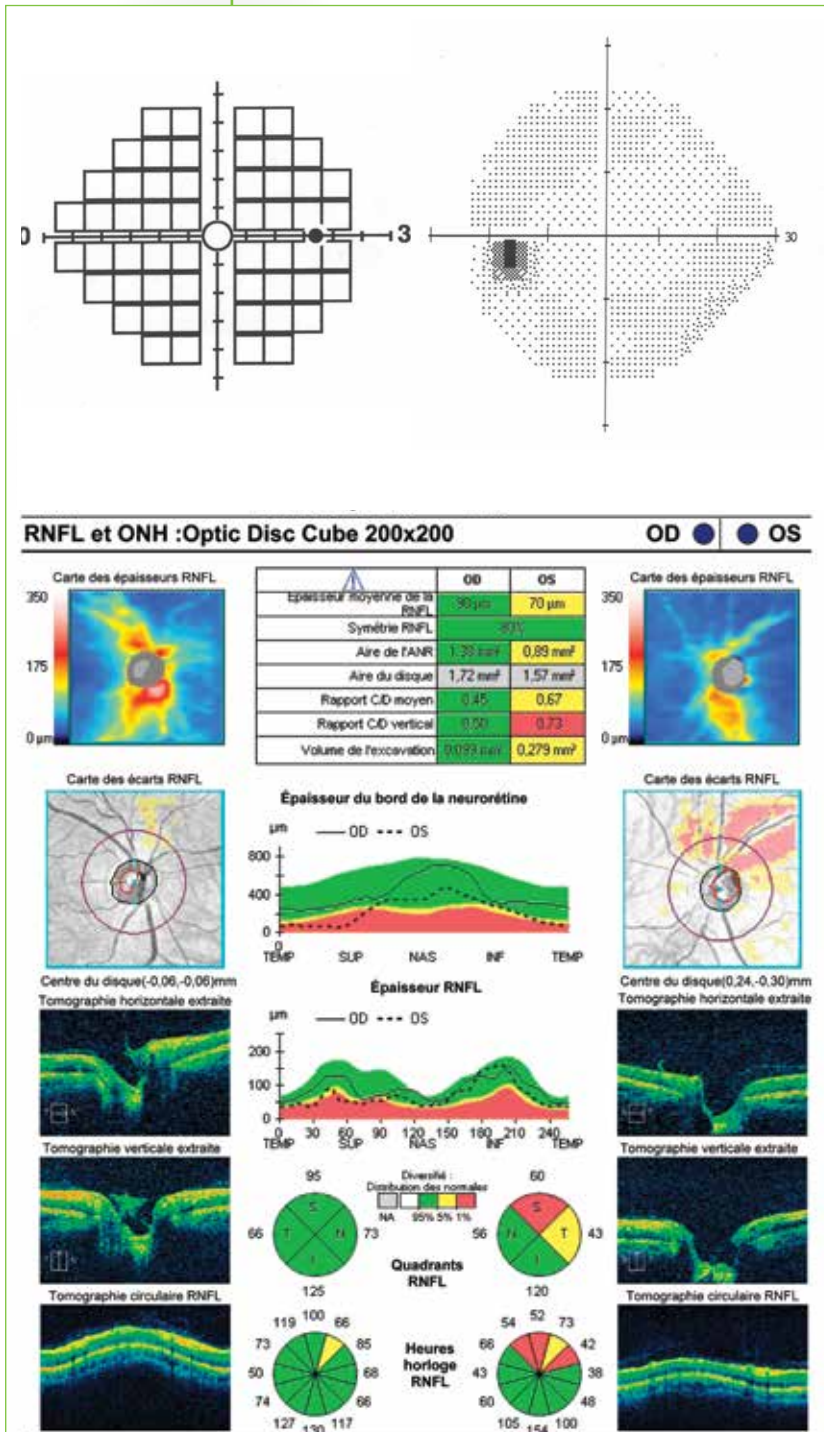
Spectral domain OCT analysis of the macular ganglion cell complex can be used to detect the beginning of impairment, which is reflected in extremely localized reduction of the fibres, with less global macular impairment than in primary open-angle glaucoma.



Macular cube OCT and central 10° visual fields in the same patient shown in Figure 54. The central 10° visual field test and OCT findings are concordant. In contrast to the situation often seen in hypertonic glaucoma, not all the macular sectors are damaged.

Figure 55

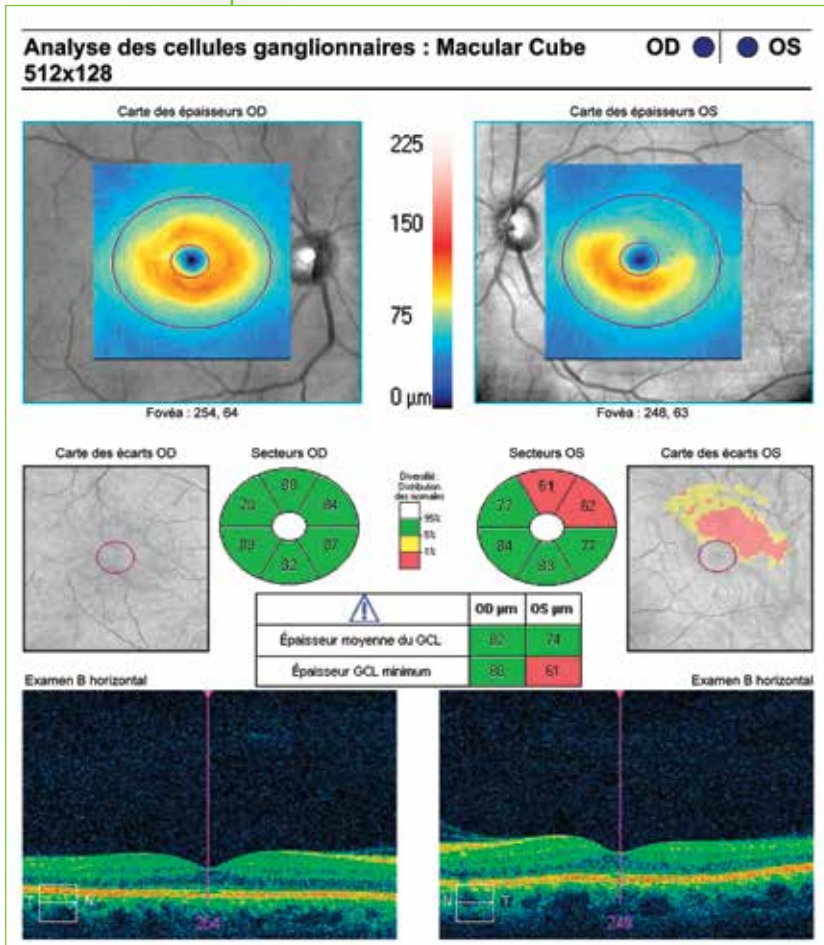
Immediately after a glaucoma crisis involving angle closure, OCT findings do not change significantly. However, after, 3–9 months, the RNFL is reduced both locally in the upper and lower regions and globally, whereas the perimeter usually remains unchanged (Figures 56 and 57). It might therefore be interesting to compare OCT findings immediately and some time after the acute crisis to determine whether structural impairment occurs as a consequence of acute hypertonia ¹³.



OCT and visual field findings in a 58-year-old patient who experienced a closed-angle glaucoma crisis in the left eye a year previously. The crisis was resolved by medical treatment and iridectomy. Intraocular pressure is 16 mmHg on each side. Matrix and OCT findings are normal in the right eye. In the left eye, the visual field appears normal but, upper region impairment is seen on OCT; optic nerve parameters in the left eye are slightly abnormal.

Figure 56

Even in the absence of an acute crisis and with normal pressure, RNFL thickness in the low temporal region is sometimes reduced in patients with narrow angles, particularly Asian patients¹⁴. This might reflect nocturnal increases in pressure.



Macular cube OCT findings in the patient shown in Figure 56. There is impairment of the macular region in the left eye, and the mean thickness is abnormal.

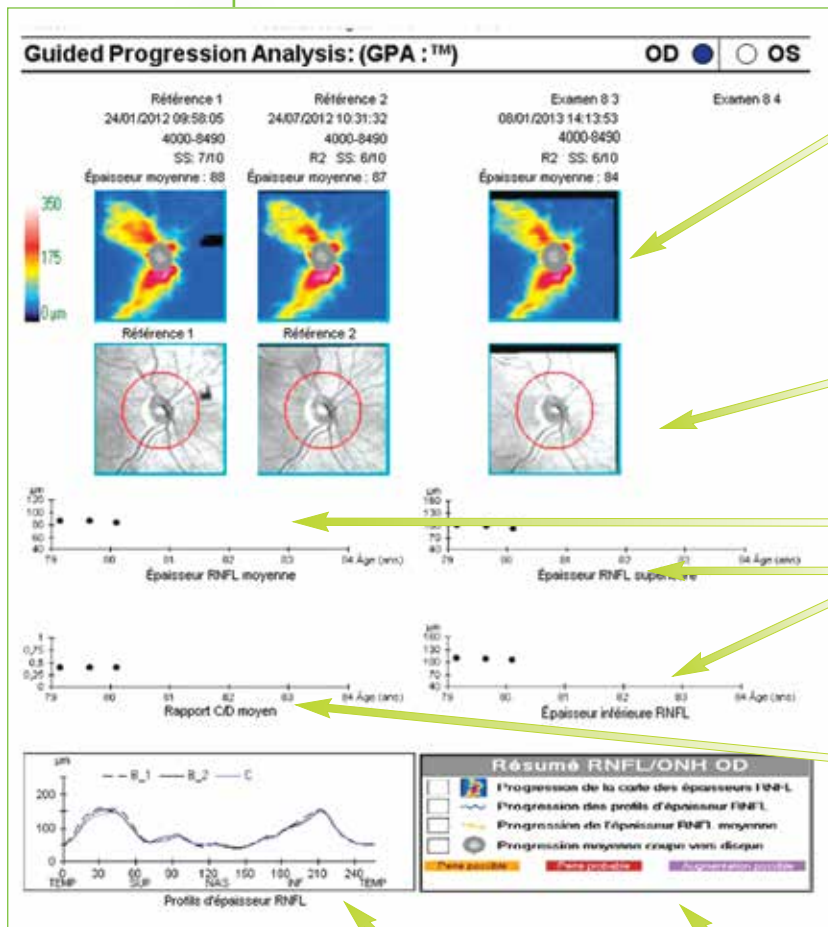
Figure 57

OCT can be used to detect and monitor the progression of glaucoma, although because spectral domain OCT is a relatively recent technique few long-term longitudinal studies are available: a 4-year patient follow-up has been reported in one study¹⁵. Such studies have shown that glaucoma may progress in several ways.

- The most common form of progression is an expansion of the deficit area, with increasing encroachment towards the macula.
- Less frequently, the impairment is deepened or appears in a different region. In order to detect such progression, examination at 2 mm from the centre of the optic nerve offers better discrimination of small changes; the region usually selected for examination, 3.4 mm from the centre of the optical nerve, is too peripheral. In more than 50% of cases, such progressive changes in OCT findings are not confirmed by automatic perimetry testing, a finding which underlines the low correlation between these two examinations, at least over short periods. Conversely, in about 20% of cases, isolated progression in the perimeter is confirmed without changes in OCT parameters.

The Guided Progression Analysis (GPA) report has proposed a glaucoma monitoring programme and an analysis of progression, based on Cirrus HD-OCT findings (Figure 58).

This GPA programme, like perimetry testing, is used to detect significant disease progression. However, it does have important limitations. Glaucoma is considered to be progressive if changes seen in a repeated examination



Optical fibre thickness

Changes in the thickness of optical fibres between examinations, when a first change is detected, are drawn in yellow; if confirmed during the next examination, they are in red.

Longitudinal changes in the global mean thickness of the RNFL in the upper and lower regions (3 traces)

Changes in mean cup/disc ratio

Fibre thickness profile in the various regions (TSNIT), using the same colour code in the event of aggravation

Probability of stability or progression aggravation for fibre thickness and TSNIT (focal progression), average thickness (diffused progression), and mean cup/disc ratio

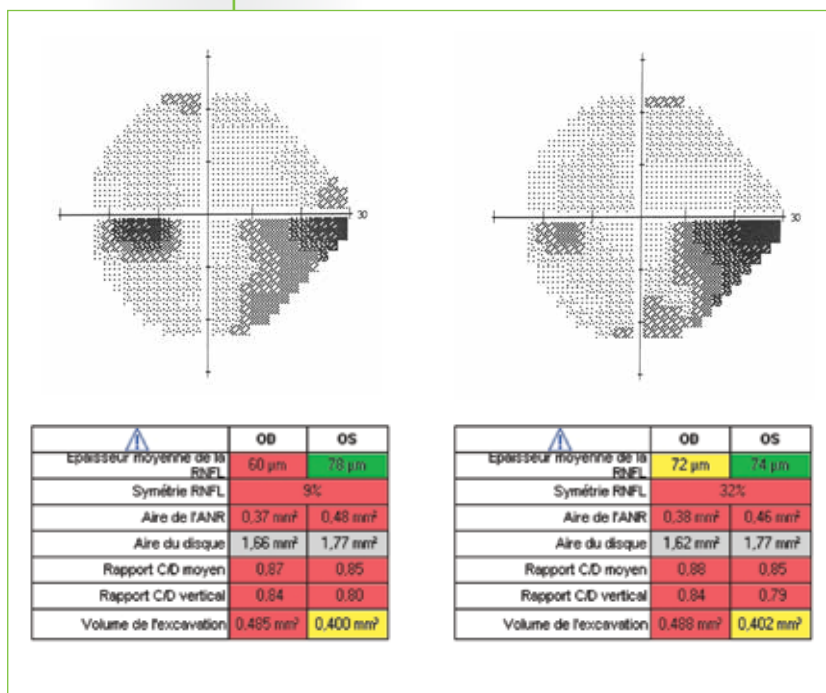
Figure 58

OCT parameters recommended for monitoring of glaucoma progression, according to the Guided Progression Analysis (GPA) report.

are greater than variability limits determined in healthy individuals, but it is not known whether this variability is different in glaucoma patients. In one study¹⁷, an increase in the volume of the RNFL was found in 13% of cases, which is difficult to accept because that would indicate an improvement of glaucoma; undoubtedly, this result is attributable to errors in the initial measurements. The same team carried out a similar study 3 years earlier using OCT Stratus, which showed a reduced ability to detect progression with previous generations of OCT devices. Furthermore, progression of structural and functional impairment does not occur in parallel. Indeed, the relationship between optical fibre loss and visual field deterioration is not linear¹⁸.

These studies clearly show that automatic perimetry testing is essential for glaucoma monitoring, but OCT also appears to be very useful, at least during the incipient and moderate glaucoma phases. When evaluating glaucoma progression by measuring the reduction in RNFL thickness, the glaucoma stage must also be considered:

- During the initial phases of glaucoma, optical fibre loss may increase without major changes in the visual field.
- As the disease progresses, moderate changes in RNFL thickness are reflected in severe deterioration of the visual field (Figure 59).
- During the later stages, the thickness of the RNFL no longer changes significantly, while the visual field continues to worsen. As noted previously, the persistence of a certain RNFL thickness does not mean that a significant number of ganglion cells remain, but rather that the support cells in this layer are still present.



Simultaneous worsening of results from visual field testing and OCT over 6 months. Mean RNFL in the left eye changed during this period from 78 µm to 74 µm: a 3 µm decrease is considered significant.

Figure 59

Can OCT findings improve in glaucoma?

In practice, OCT findings do not improve over time in patients with glaucoma. After a steep reduction in ocular pressure through surgery, OCT may show an increase in RNFL thickness, but this is a temporary phenomenon that only lasts for about 3 months¹⁹. Most commonly, apparent improvements in OCT parameters result from improved image quality during subsequent measurements following a suboptimal initial measurement.

Comparisons between spectral domain OCT devices in glaucoma patients

Several spectral domain OCT devices are available, including the Cirrus™ HD-OCT (Carl Zeiss), the 100RTVue (Optovue), and the Spectralis (Heidelberg). These use the same operating principle, but vary in terms of acquisition speed, the ability to monitor eye movements and the retinal layer segmentation method used. Although the different instruments produce similar results, the absolute values obtained may differ: for example, the Cirrus HD-OCT gives lower RNFL values than RTvue, due to differences in the measuring zone between the two devices²⁰.

For this reason, absolute values obtained using one spectral domain OCT scanner cannot be extrapolated to another.

OCT and cribriform plate analysis

In addition to impairment of optical nerve fibres, glaucoma is known to cause deformation of the cribriform plate. By using specific software (Enhanced Depth Imaging-Optical Coherence Tomography: EDI-OCT), it is possible to view the cribriform plate deforming towards the rear, and also shifting backwards in relation to the sclera in certain meridians²¹. It is not known whether this is a cause or a consequence of impairment of the plate; however, after surgical reduction of ocular pressure the cribriform plate gains anterior adhesion and thickens again²². This analysis appears to be an important development, as it offers the potential to visualize a number of deep components of the optic nerve complex²³. Conversely, there does not appear to be a great benefit from measuring the thickness of the choroids, which changes only slightly in glaucoma²⁴ and is unchanged in cases of peripapillary atrophy.

Non- glaucomatous optic neuropathies

Optic neuropathies lead to deterioration of the axons of both parapapillary and macular nerve fibres, which can be detected by OCT. As a result, OCT has become a very important diagnostic tool in neuro-ophthalmology ²⁶. In many cases, OCT findings can aid the diagnosis and provide information of the severity of the neuropathy. However, in some cases the OCT profile may resemble that of glaucoma, and hence it is important to understand the OCT findings characteristic of different neuropathies.

Analysis of the retinal ganglion fibre layer is of particular interest in patients with multiple sclerosis (MS) because the thickness of this layer correlates better with patients' functional symptoms (decreased lower visual acuity or reduced visual field) than other examinations, such as magnetic resonance imaging (MRI) ²⁷.

Acute neuropathy in MS

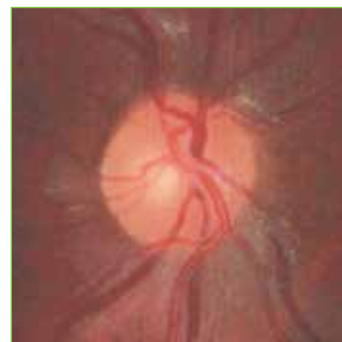

During the acute phase of optic neuropathy in MS, the RNFL is sometimes thicker than normal, a finding which reflects slight, sub-clinical, papillary oedema. This oedema is present even when the demyelinating plaque is located in the posterior part of the optic nerve.

Thinning of the RNFL occurs 1–3 months after an acute crisis, and stabilises after approximately 6 months. If no further crises occur, the RNFL subsequently remains stable after 6–8 months. The most marked changes in OCT findings are found in the macular area, where the ganglion cell layer accounts for approximately 34% of the retinal volume. MS-related optic neuropathy is characterized by a reduction of about 35–45% in the thickness of the macular optical fibre layer (i.e. a 20–40 μm reduction from a normal thickness of 110–120 μm) ²⁸. The contralateral eye is also affected in most cases, albeit to a lesser degree (20% reduction in thickness). Importantly, defects in perimetry testing do not become apparent until the macular layer is reduced by approximately 75 μm , and hence it is essential that OCT findings are evaluated according to the dynamics of neuropathy ²⁹: during the acute phase, the absence of layer thinning may provide false reassurance.

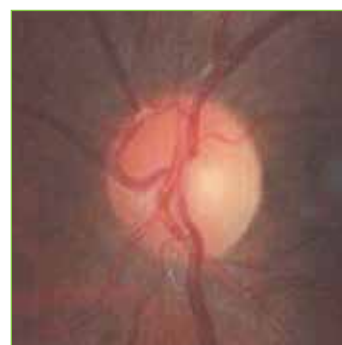Both the papilla and macula are affected by MS. As noted above, during the initial phases the RNFL may be artificially enlarged by papillary oedema, which is seen in macular ganglion cells. However, as the disease progresses, changes in the two structures develop in parallel ³⁰.

Correlations between OCT findings and visual field testing in MS

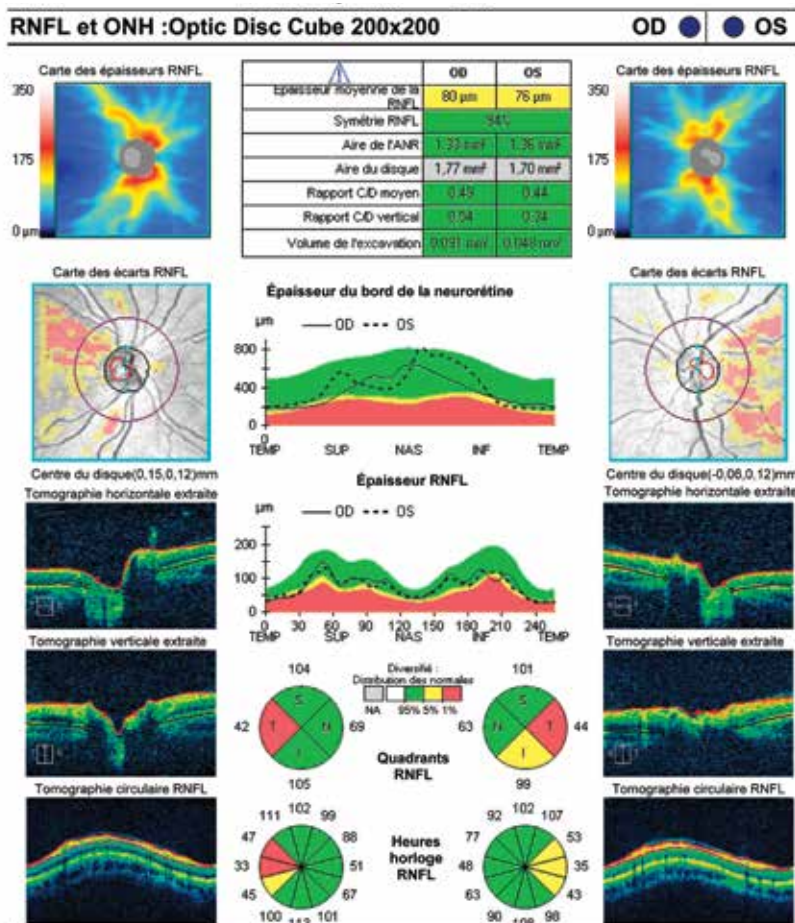
In patients with minimal evidence of neuropathy on OCT, the visual field and visual acuity generally remain normal after an acute crisis. By contrast, if the thickness of the peripapillary RNFL decreases to approximately 75 μm , decreases in the visual field become apparent (Figures 60 and 61).



Right eye



Left eye

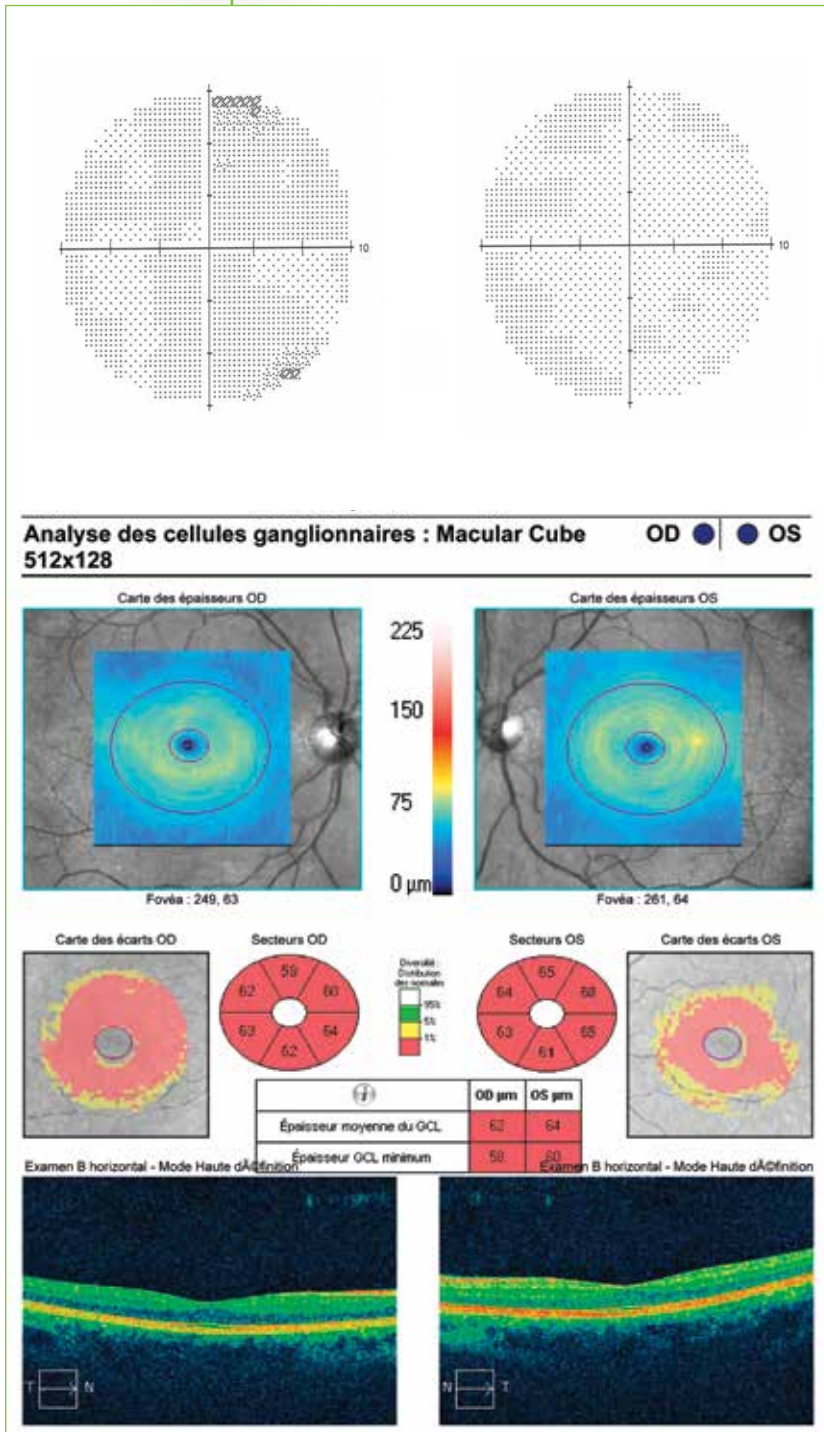


OCT and visual field findings in a patient with multiple sclerosis (MS) after an acute attack. OCT predominantly shows impairment in the temporal sectors of each eye, which is not seen with Goldmann's kinetic perimetry testing. The optic nerves are normal. Temporal impairment, as shown here, is typical of non-glaucomatous neuropathies such as MS-related optic neuropathy.

Figure 60

Location of optic neuropathy in MS

In patients with MS, optic neuropathy is most commonly seen in the temporal quadrant (Figures 60 and 61). This contrasts with the situation in glaucoma, in which impairment is generally seen in the superior or inferior quadrants.

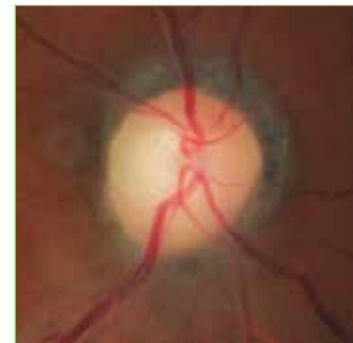
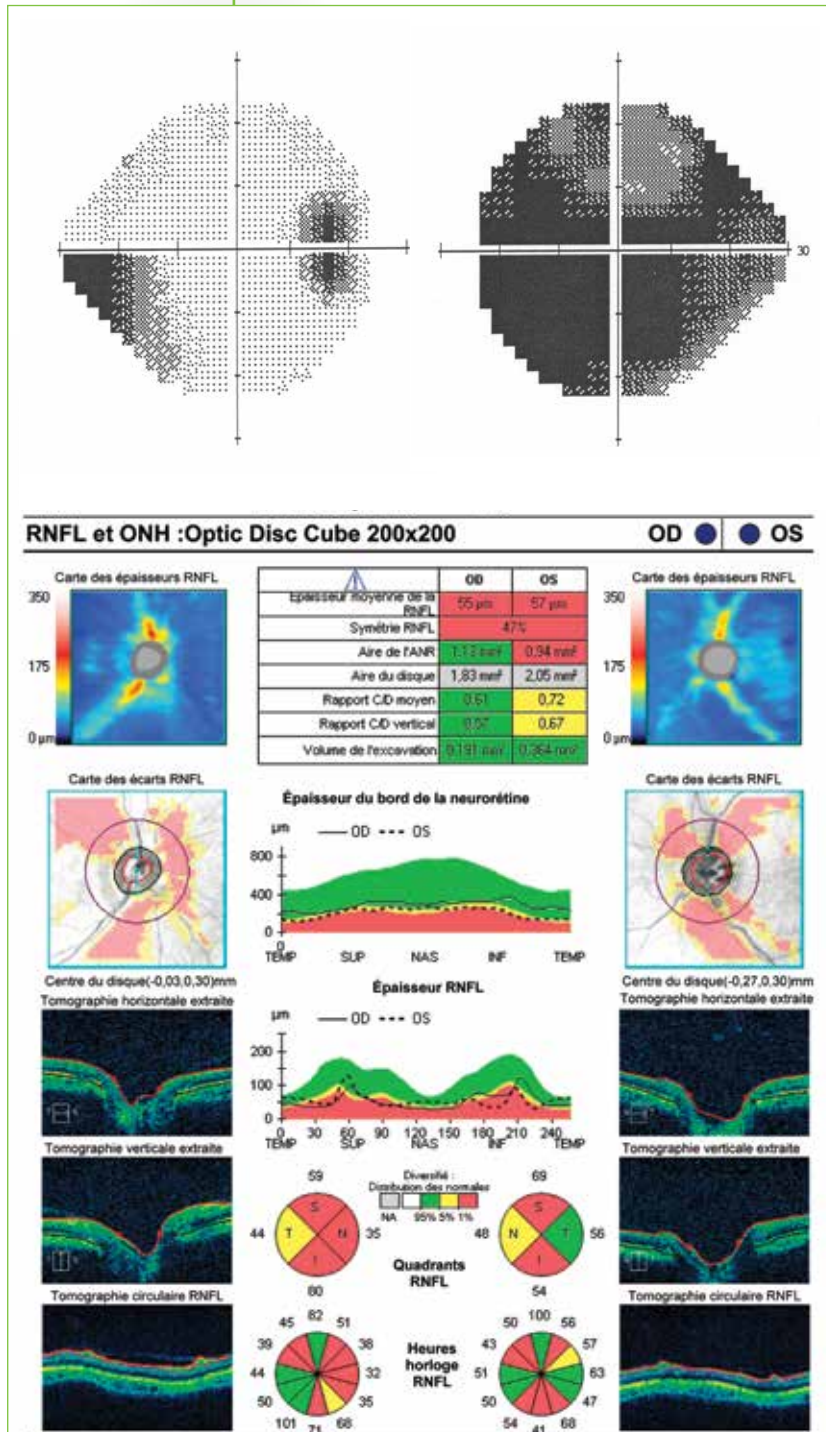


Macular cube OCT and central 10° visual fields in the same patient as in Figure 60. There is major impairment of macular ganglion cells in each eye, despite there being only slight changes in the central visual field. This type of diffuse impairment is a common finding in MS.

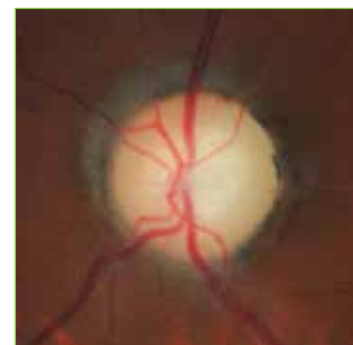
Figure 61

Important sequelae of MS neuropathy

The progression of MS is associated with progressive deterioration in both visual field and OCT findings (Figures 62 and 63). However, these may not always occur in parallel: in some cases, changes in OCT findings may be greater than changes in visual field testing.



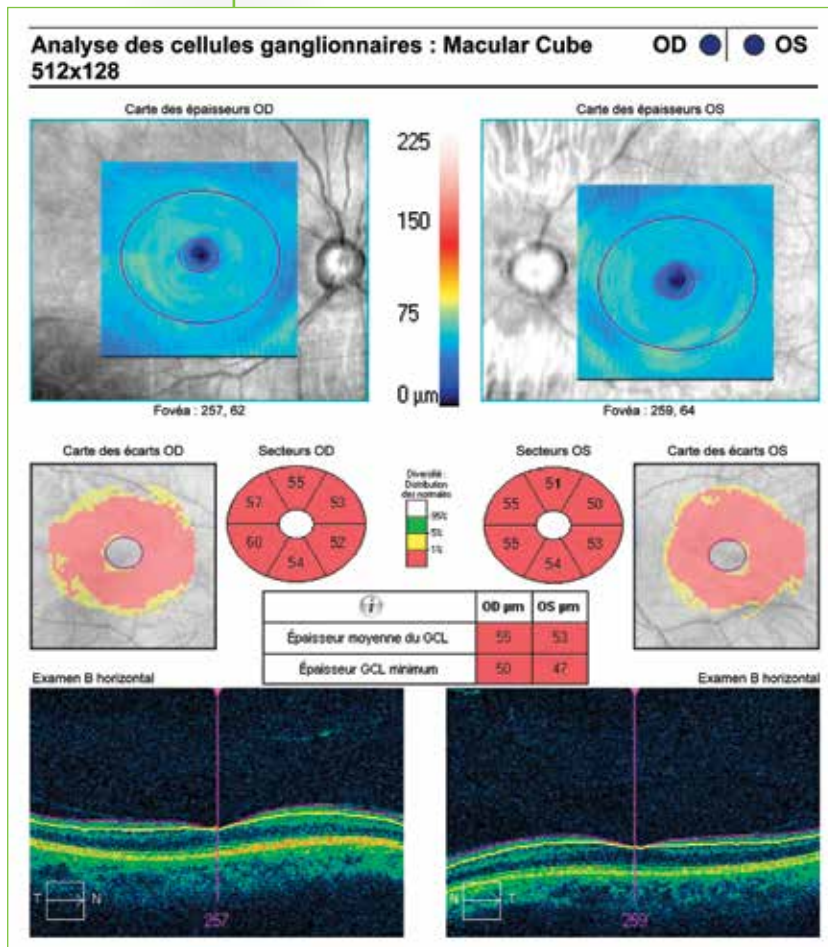
Right eye



Left eye

OCT and visual field findings in a female patient with MS and several acute attacks of optic neuropathy. The visual field of the left eye is severely affected: OCT confirms this impairment and also reveals an almost identical change in the right eye. The optic nerves show bilateral optical atrophy, which is more marked on the left. There is no pathological excavation of the optic nerve head.

Figure 62

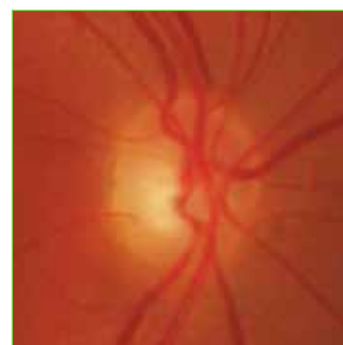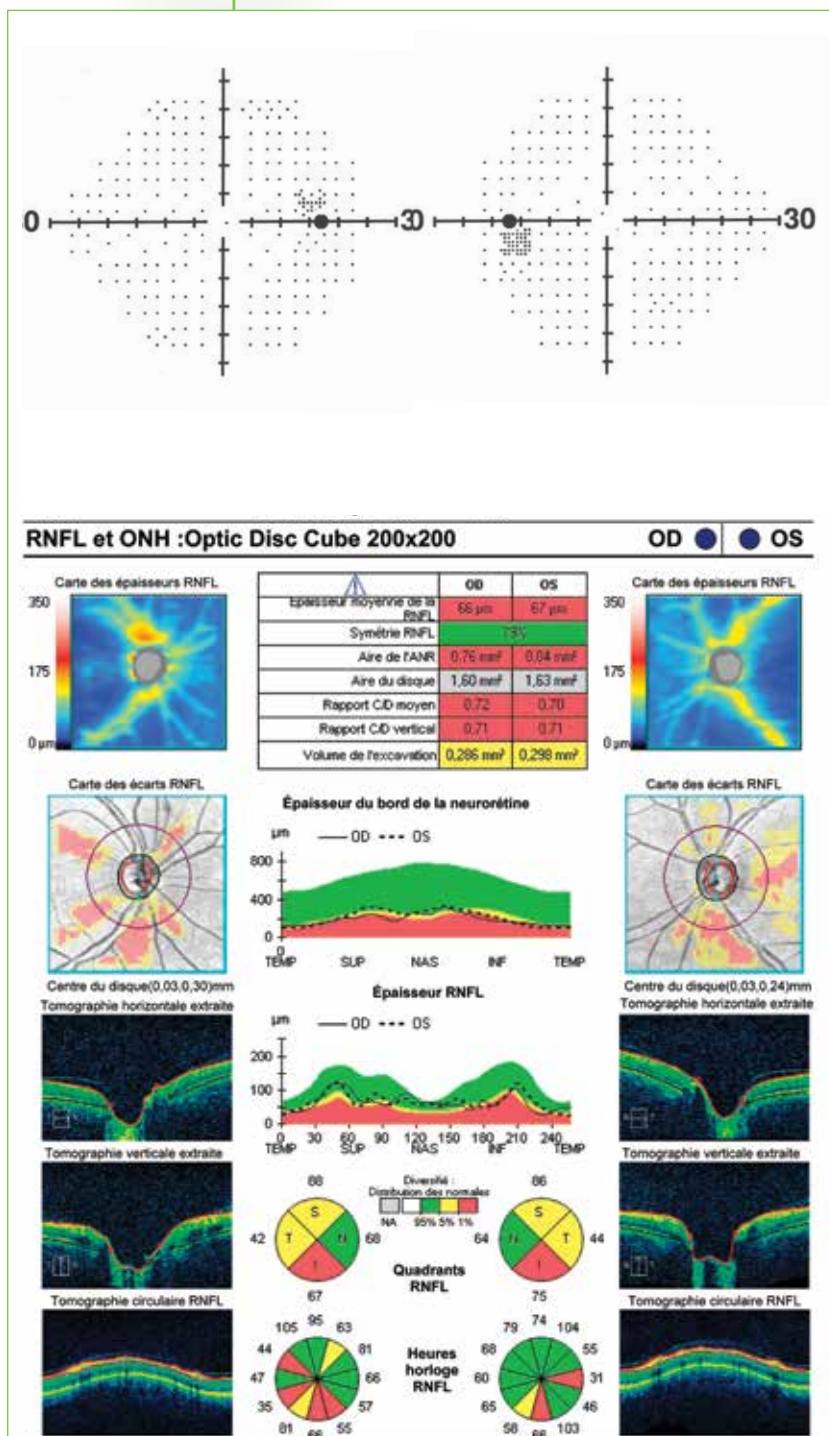


Macular cube OCT from the same patient as in Figure 62. Ganglion cell impairment is severe on both sides.

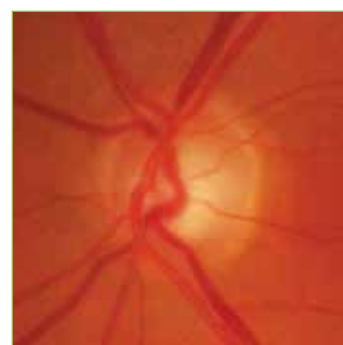Figure 63

Detection of subclinical MS neuropathy with OCT

impairment of the visual pathways is almost always present in MS, and hence OCT is a useful tool for the detection of subclinical impairment (Figures 64 and 65) and for monitoring progressive neurological changes ³¹.



Right eye

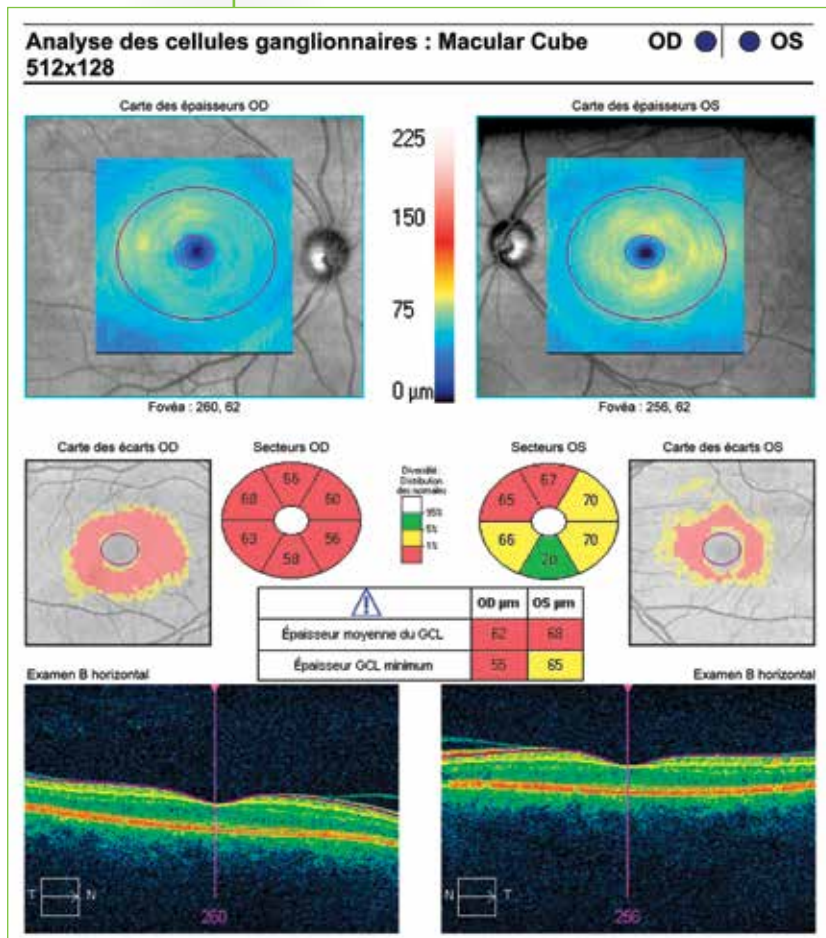


Left eye

OCT and visual field findings in an MS patient with no known episodes of optic neuropathy. marked pathology is seen on OCT, while the visual field is normal.

Figure 64

In addition, it could be used to monitor the effects of treatment on the course of MS.



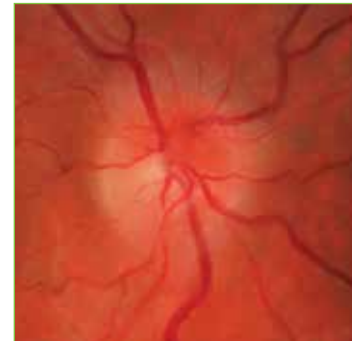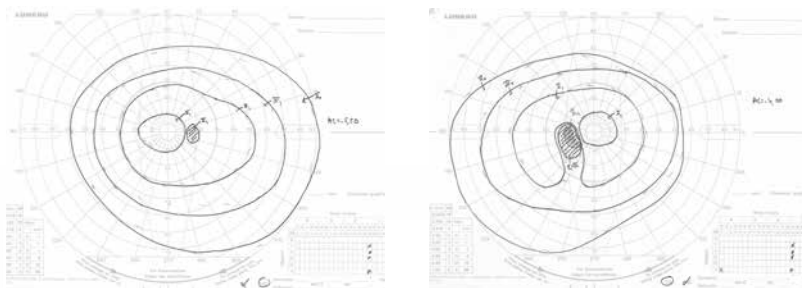
Macular cube OCT from the same patient as in Figure 64. Diffuse impairment of the macular ganglion cells is visible, but visual acuity is normal.

Figure 65

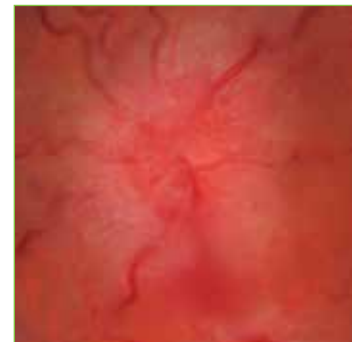Acute optic neuropathy unrelated to MS

Ophthalmologists are often confronted with acute optic neuropathy of unknown origin. In this situation, it is essential to consider the clinical context when trying to establish whether the pathology is demyelinating. Demyelinating optic neuropathy is characterized by:

- occurrence between the ages of 20 and 50 years
- ocular pain, particularly during eye movement
- strictly unilateral presentation
- progressive deterioration over about 1 week, followed by recovery after 1 month.

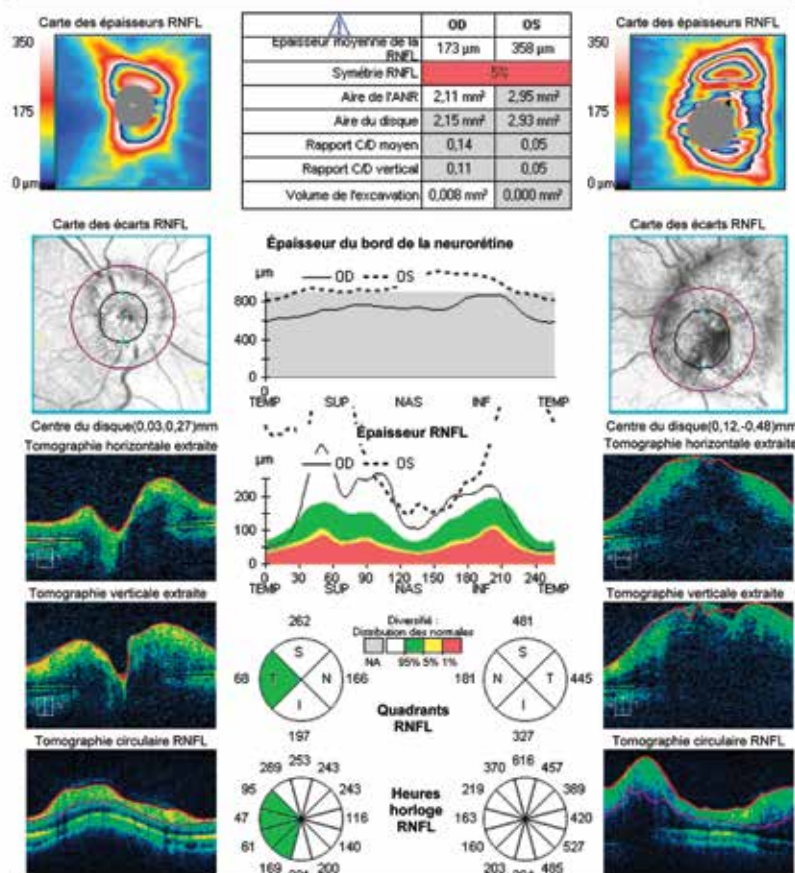


Right eye



Left eye

RNFL et ONH :Optic Disc Cube 200x200

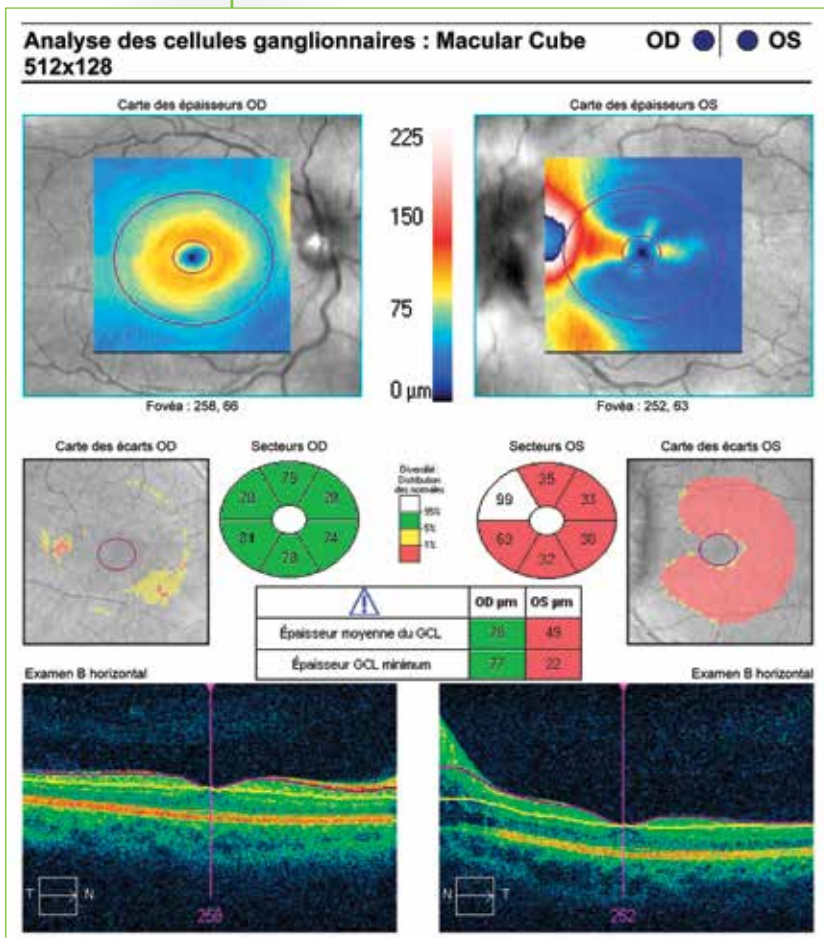


OCT and visual field test results from a 30-year-old patient with bilateral blurred vision, without reduced acuity. MRI results did not indicate MS. The ocular fundus shows greater papillary oedema on the left than on the right; this finding is confirmed by OCT, which shows a marked increase in parapapillary RNFL thickness on both sides.

Figure 66

Unfortunately, OCT profile cannot specifically identify demyelinating neuropathologies, which manifest as an initial increase in RNFL thickness resulting from oedema, followed by progressive reduction of the RNFL.

Figures 66 and 67 show OCT findings from a 30-year-old patient with bilateral blurred vision, in whom MRI findings did not indicate MS. OCT showed significant papillary oedema, particularly in the left eye (Figure 66), with severe ganglion cell impairment (Figure 67).



Macular cube OCT from the same patient as in Figure 66. The analysis of ganglion cells shows severe impairment on the left, while visual acuity is 10/10. Observation of the macula, remote from the papilla, allows accurate monitoring of the effects of optic neuropathy.

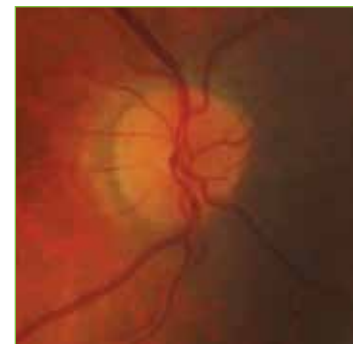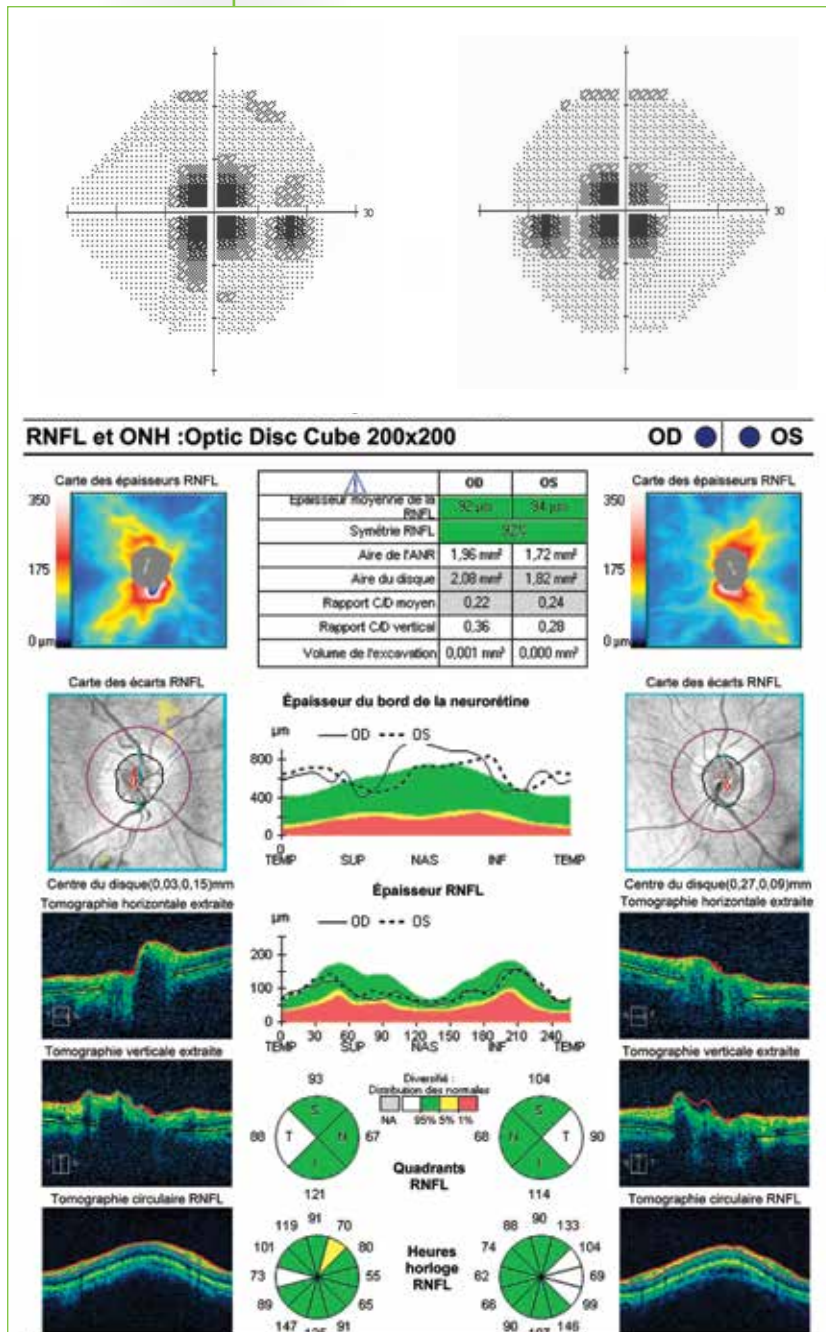
Figure 67

Toxic optic neuropathy

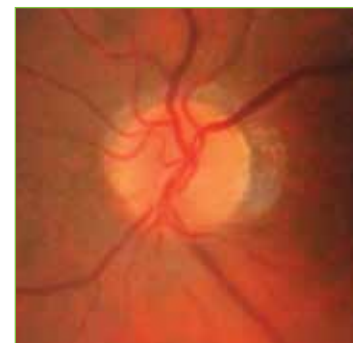Toxic or nutritional optic neuropathies are characterized by bilateral, symmetrical and painless impairment, which is classically associated with centrocaecal scotoma (Figures 68 and 69). In such cases, OCT often reveals bilateral and gradual impairment of the RNFL ³². Impairment of peripapillary optical fibres is confined to the temporal region, with relative preservation of the upper and lower sectors.

Apparent toxic optic neuropathy without papillary impairment

In the presence of papillary oedema, the parapapillary fibres may appear normal on OCT because the thickness of the cell layer is artificially increased by oedema.



Right eye

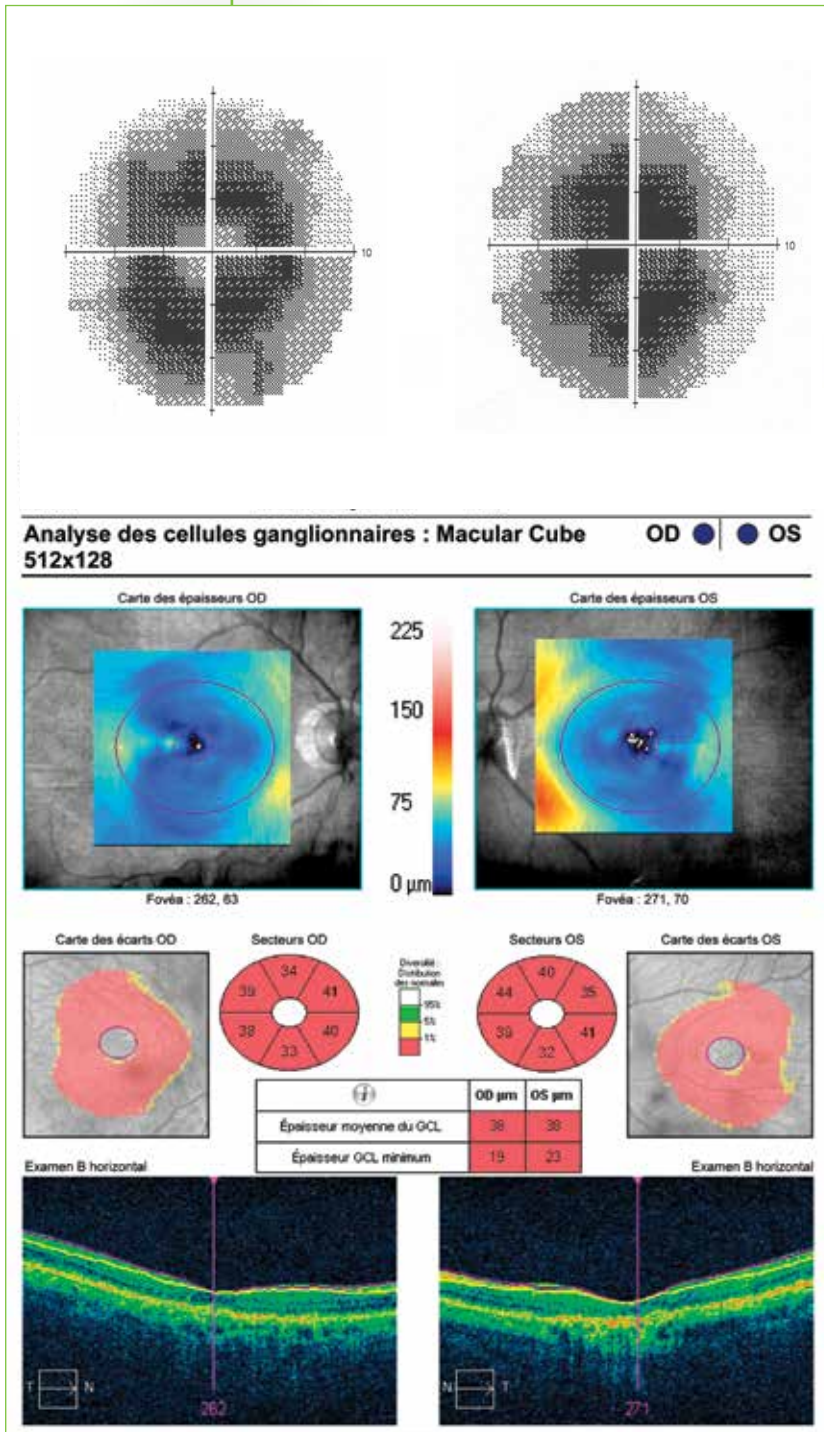


Left eye

OCT and visual field test findings in a 61-year-old patient with optic neuropathy associated with alcohol and nicotine use. The visual fields show bilateral centrocaecal deficit. OCT reveals papillary oedema and apparently normal optic nerves; the RNFL appears normal because the thickness is artificially increased due to oedema.

Figure 68

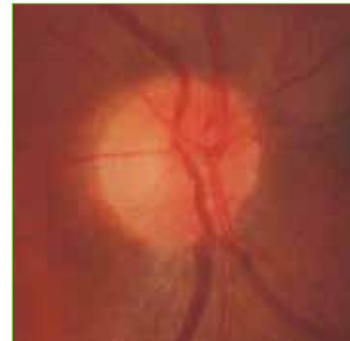
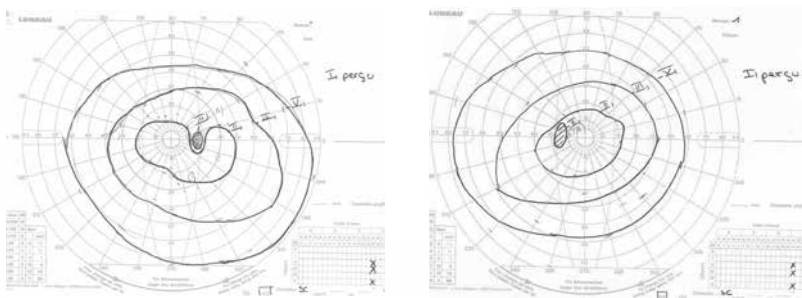
In this situation, there may be a marked contrast on OCT between normal parapapillary optical fibres and major impairment of the ganglion cell complex.



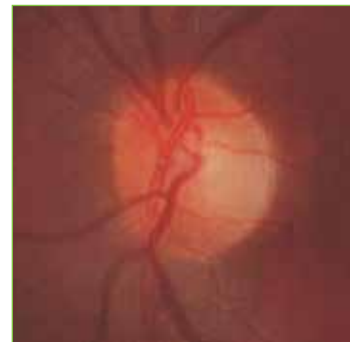Macular cube OCT and central 10° visual fields in the same patient as in Figure 68. The central 10° visual field confirms central impairment, while OCT shows significant bilateral, symmetrical and homogeneous impairment of macular ganglion cells.

Figure 69

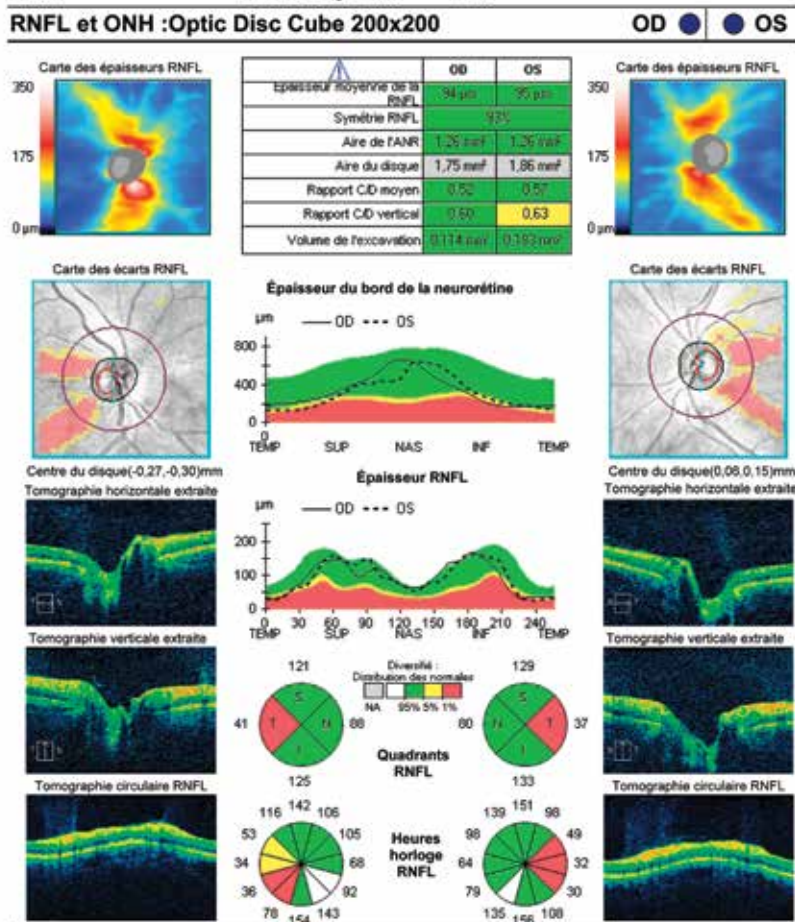
Toxic optic neuropathy with papillary and macular impairment



Right eye



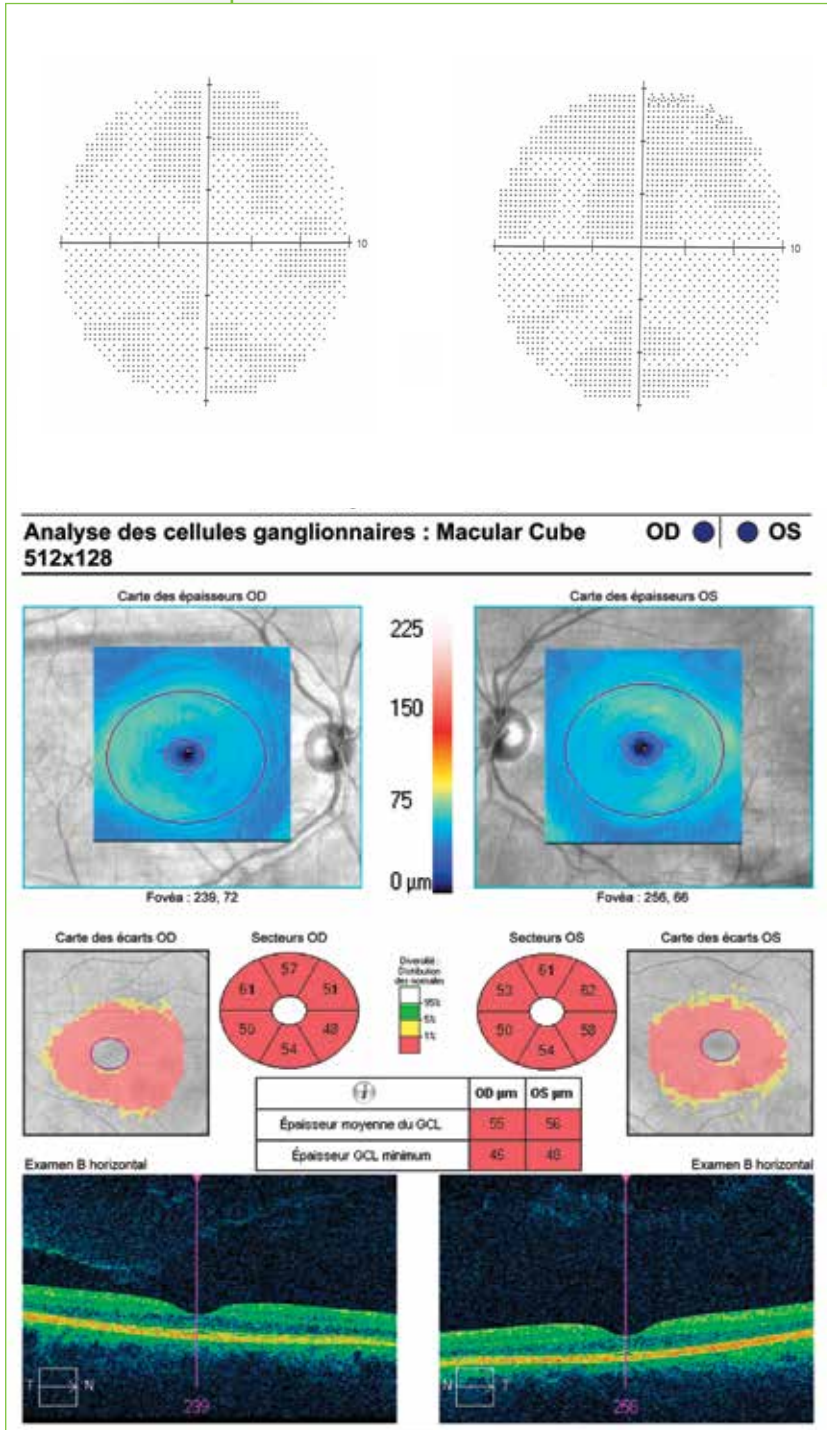
Left eye



OCT and visual field test results from a 42-year-old patient with optic neuropathy associated with alcohol and nicotine. Goldmann's visual fields show distortion of the blind spot on the right and a normal result on the left. OCT reveals bilateral RNFL impairment in the temporal region: the upper and lower sectors are not affected. The optic nerves are normal, and there is no pathological excavation.

Figure 70

In patients with incipient toxic optic neuropathies, impairment may be more evident in the macular ganglion cells, even when visual acuity is preserved (Figures 70 and 71). Such impairment is generally diffuse and symmetrical.

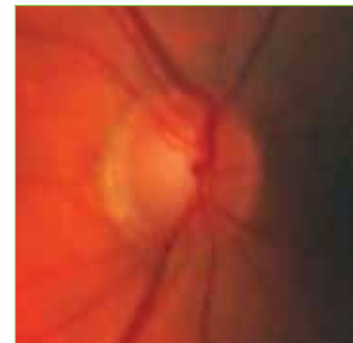
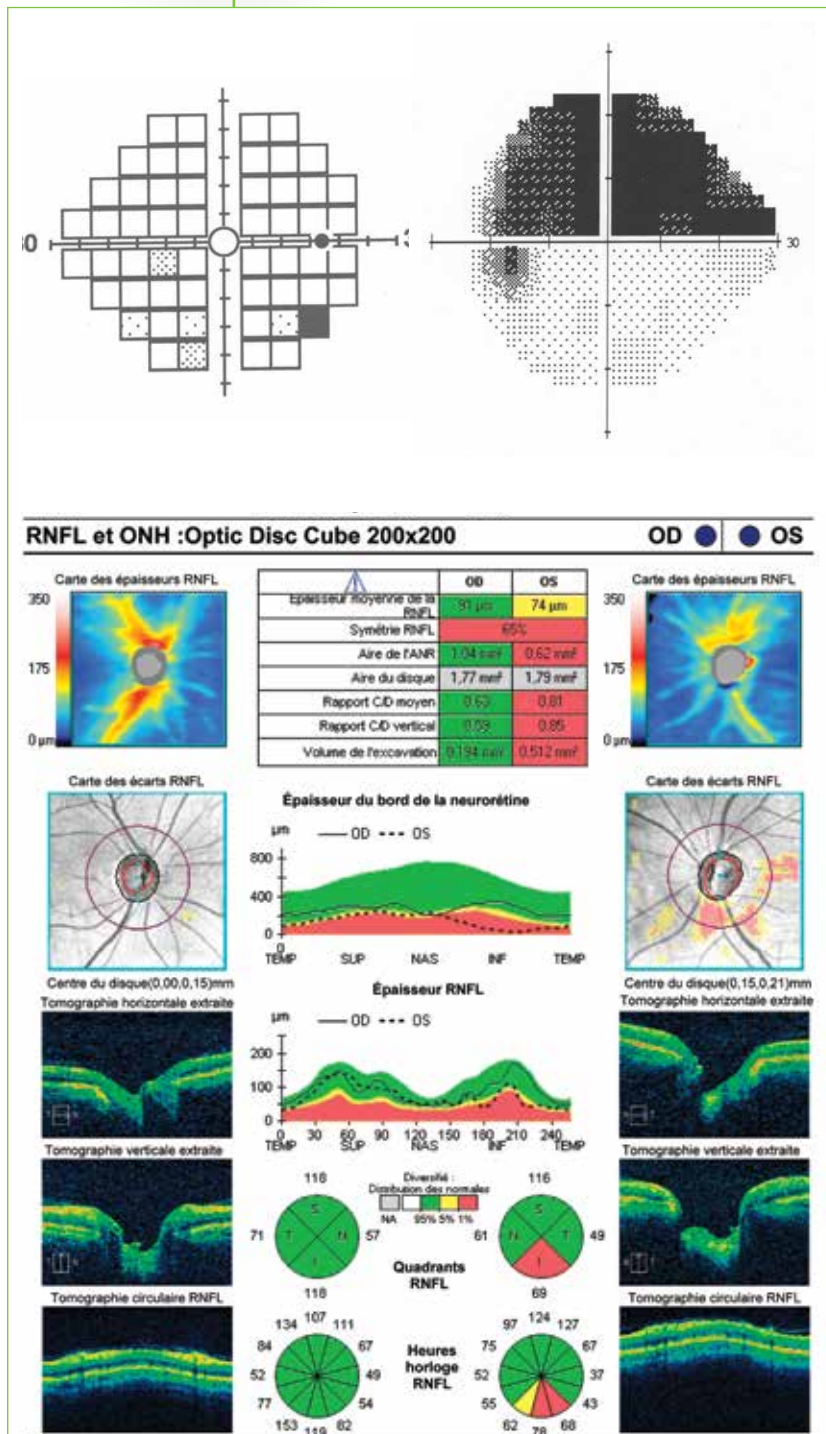


Macular cube OCT and central 10° visual fields in the same patient as in Figure 70. There is a slight diffused deficit of the central 10° visual field present on both sides, while macular OCT shows significant bilateral, symmetrical and homogeneous impairment. This presentation is suggestive of toxic retrobulbar optic neuropathy (RBO).

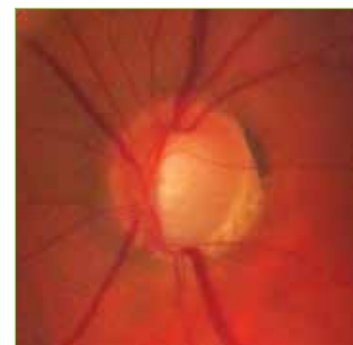Figure 71

Anterior ischaemic neuropathy

It is sometimes difficult, to distinguish between remote sequelae of anterior ischaemic optic neuropathy (AION) and glaucoma on the basis of OCT findings. Impairment of the RNFL is temporal in both cases³³ but the deficit in AION is more altitudinal than in glaucoma, affecting not only the lower temporal sector (7hr for the right eye, 5hr for the left eye), but also affecting the upper quadrant (Figures 72 and 73)³⁴.



Right eye

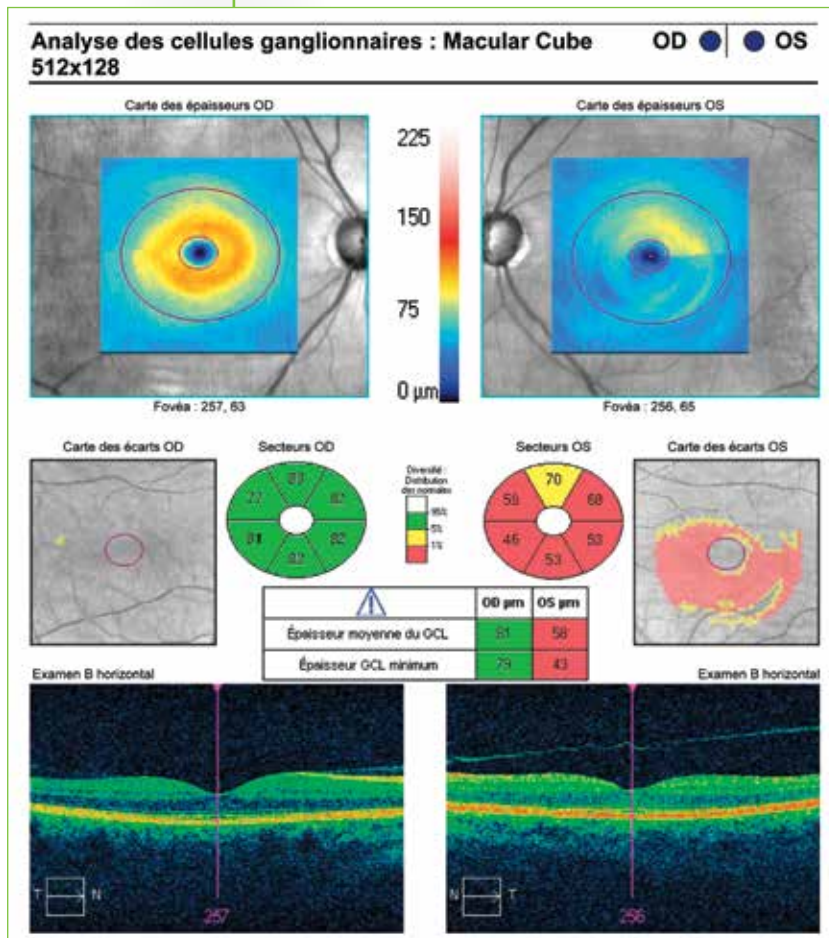


Left eye

OCT and visual field test results from a 63-year-old hypermetropic patient, with a 1-year history of anterior ischaemic optic neuropathy (AION) in the left eye. The visual field of the right eye is normal, while that of the left eye shows a superior altitudinal deficit, which is characteristic of this pathology. OCT findings are consistent with this unilateral impairment, and also show secondary excavation in the left optic nerve.

Figure 72

In addition, the excavation volume is likely to be smaller in AION than in glaucoma³⁵. During the acute phase of AION, papillary oedema causes an initial increase in parapapillary fibre thickness, while the ganglion cell layer is unaffected.



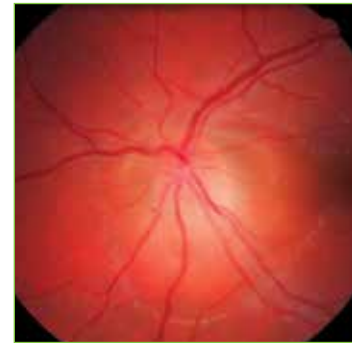
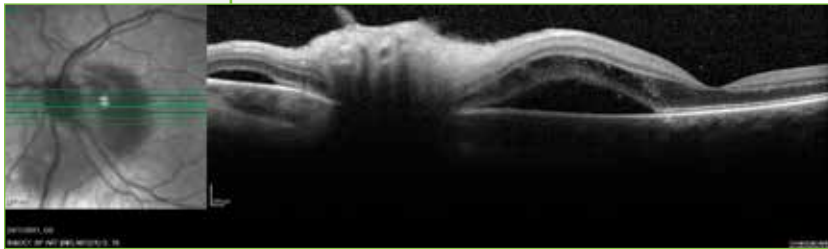Macular cube OCT findings in the same patient as in Figure 72, showing global impairment of the left eye. This presentation is perhaps atypical, because a more altitudinal deficit would be expected in a patient with AION.

Figure 73

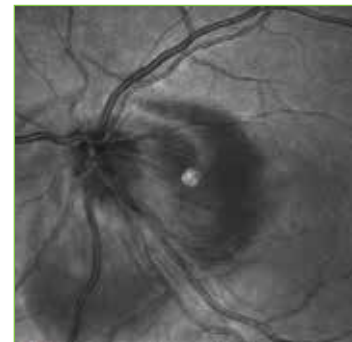
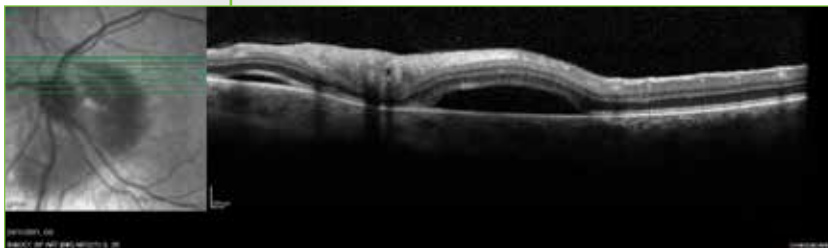
Optic neuropathy and uveopapillitis

Inflammatory optic neuropathies in patients with uveopapillitis initially lead to a marked increase in RNFL thickness, prior to secondary atrophy in about 50% of cases ³⁶.

In this situation, OCT can be used to detect oedema and intra- and subretinal location. An example is shown in Figure 74.



Right eye



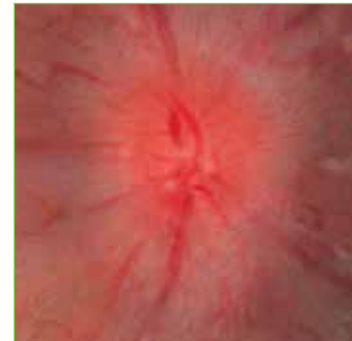
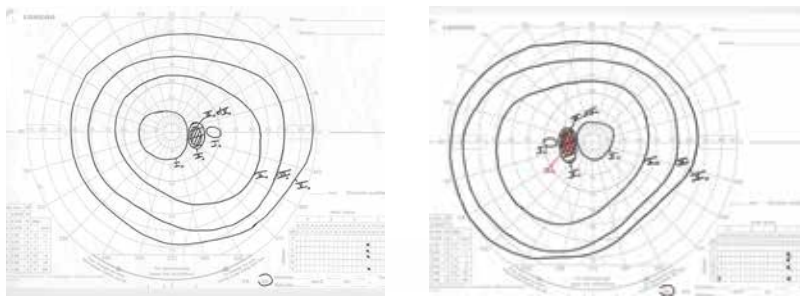
Left eye

Left unilateral uveopapillitis, probably of toxoplasmic origin, in a 19-year-old patient. OCT can determine the severity of papillary and subretinal oedema, and determine the proximity of oedema to the fovea.

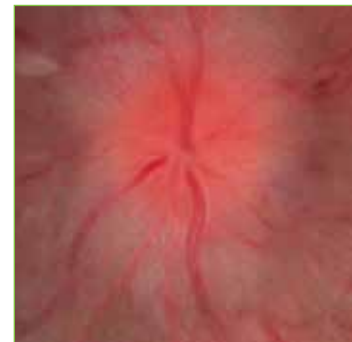Figure 74

Papillary oedema

As we have seen, papillary oedema, of any cause, results in a marked increase in the thickness of the RNFL, which will be reversed as the oedema regresses. The rate of development of sequelae to papillary oedema depends on the cause of oedema, and hence it is important to monitor the time course of changes in the RNFL (Figure 75).

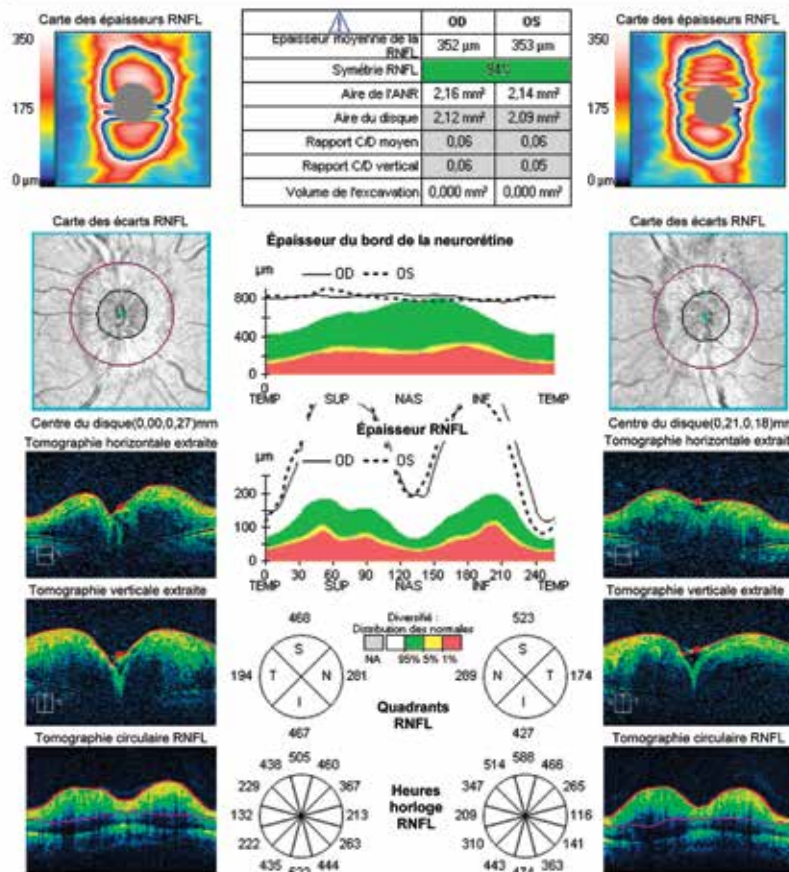


Right eye



Left eye

RNFL et ONH :Optic Disc Cube 200x200

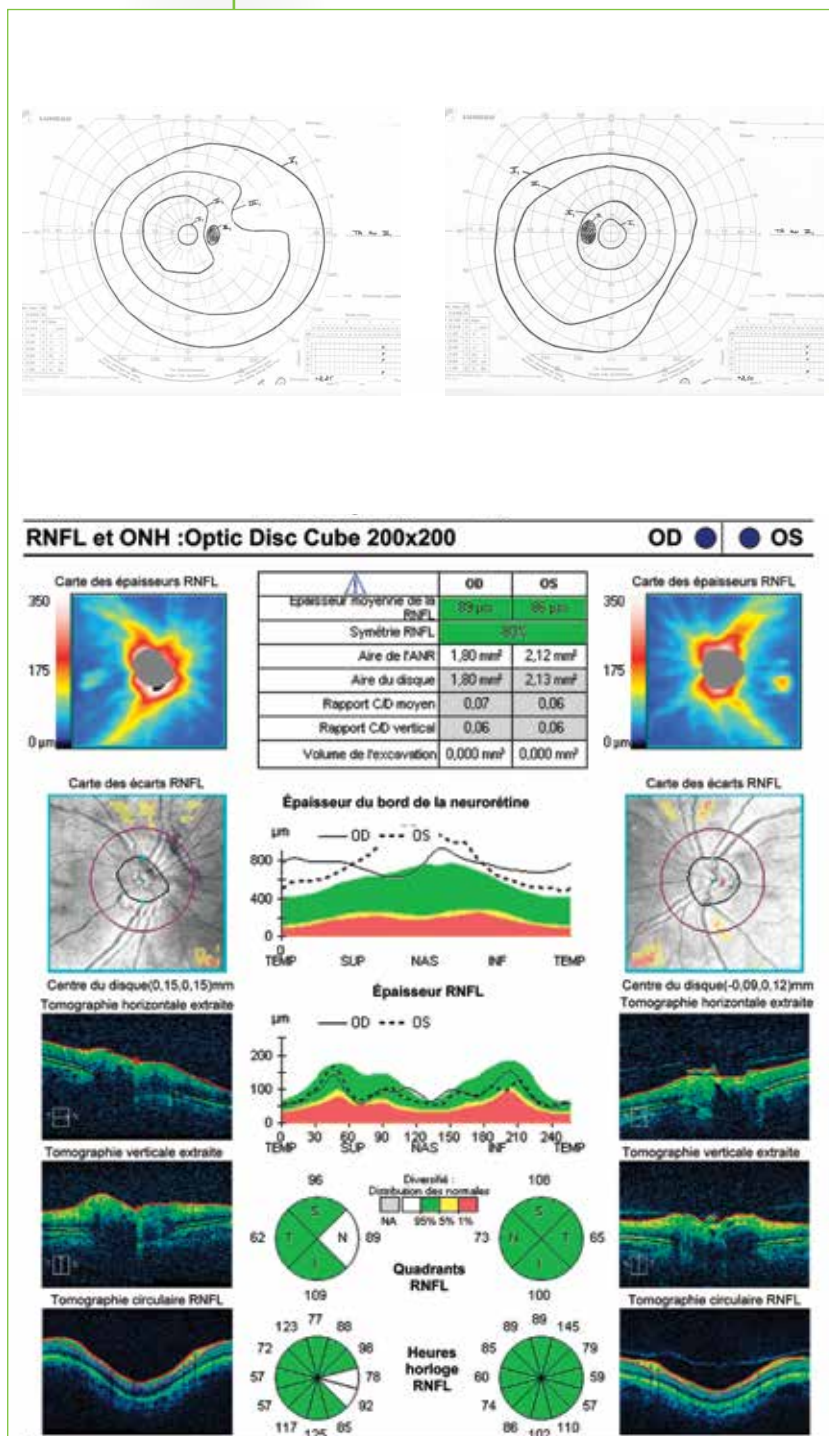


OCT and visual field test findings in a 20-year-old patient with intracranial hypertension due to an expansive intracranial process. OCT reveals increases in the volume of the optic nerve and RNFL thickness; parameters of the RNFL are measured over time to monitor the evolution of papillary oedema.

Figure 75

Isolated papillary oedema without retinal diffusion

In cases of isolated oedema, OCT shows an increase in the volume of the optic nerve, while the RNFL remains normal (Figures 76 and 77). Because the RNFL may appear normal in patients with oedema associated with incipient optic atrophy, long-term assessment is necessary.

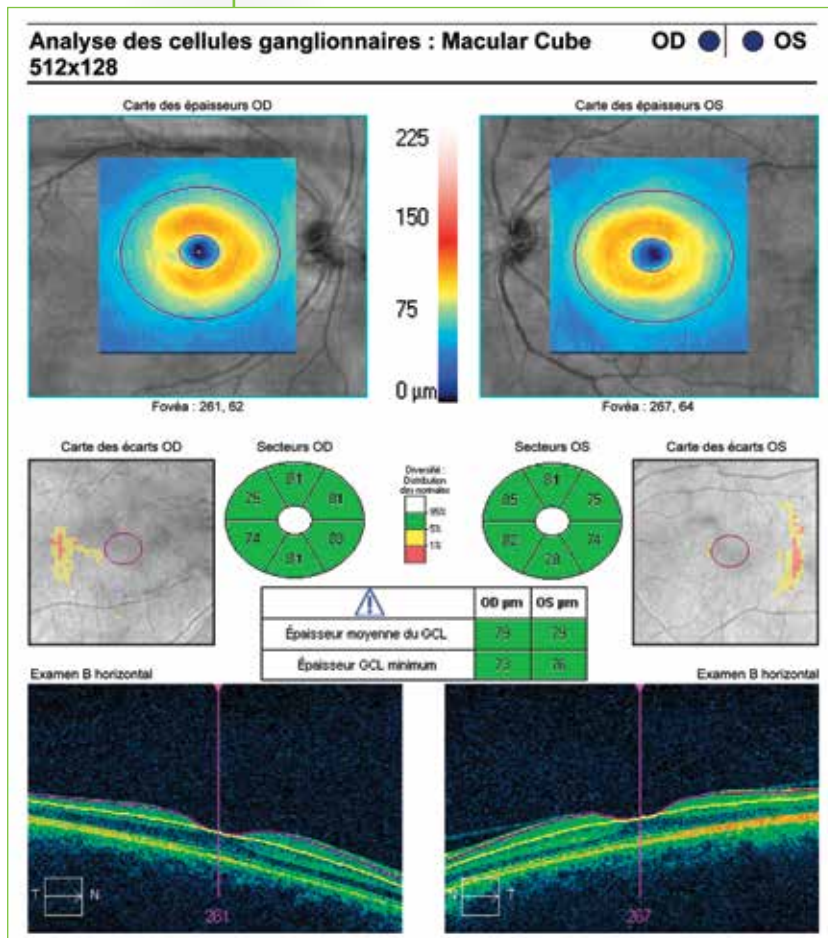


OCT and visual field test findings in a 54-year-old patient with intracranial hypertension.

OCT reveals an increase in the volume of the optical nerve without associated retinal impairment.

Figure 76

An absence of optic fibre impairment indicates a good prognosis in patients with macular oedema, and re-assessment of the acute episode will confirm this.

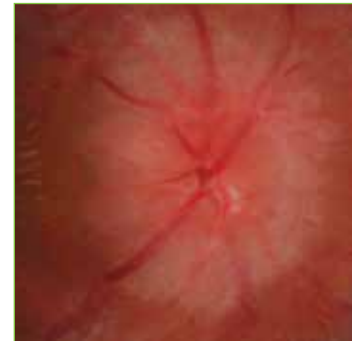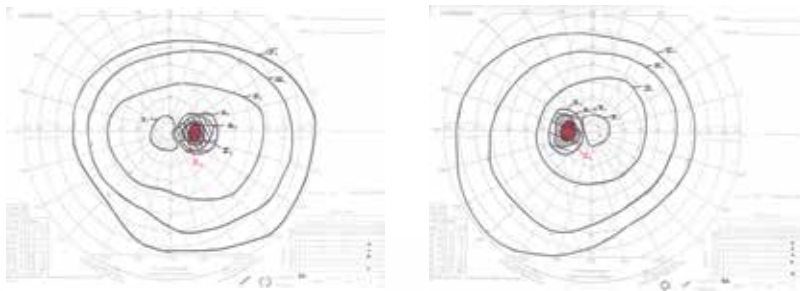


Macular cube OCT in the patient shown in Figure 76. Macular OCT findings are normal.

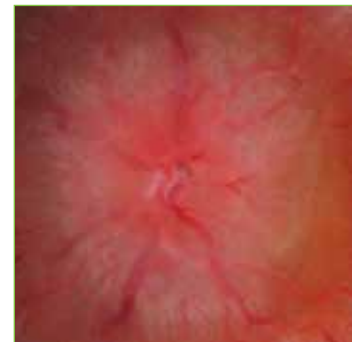Figure 77

Papillary oedema with subretinal oedema

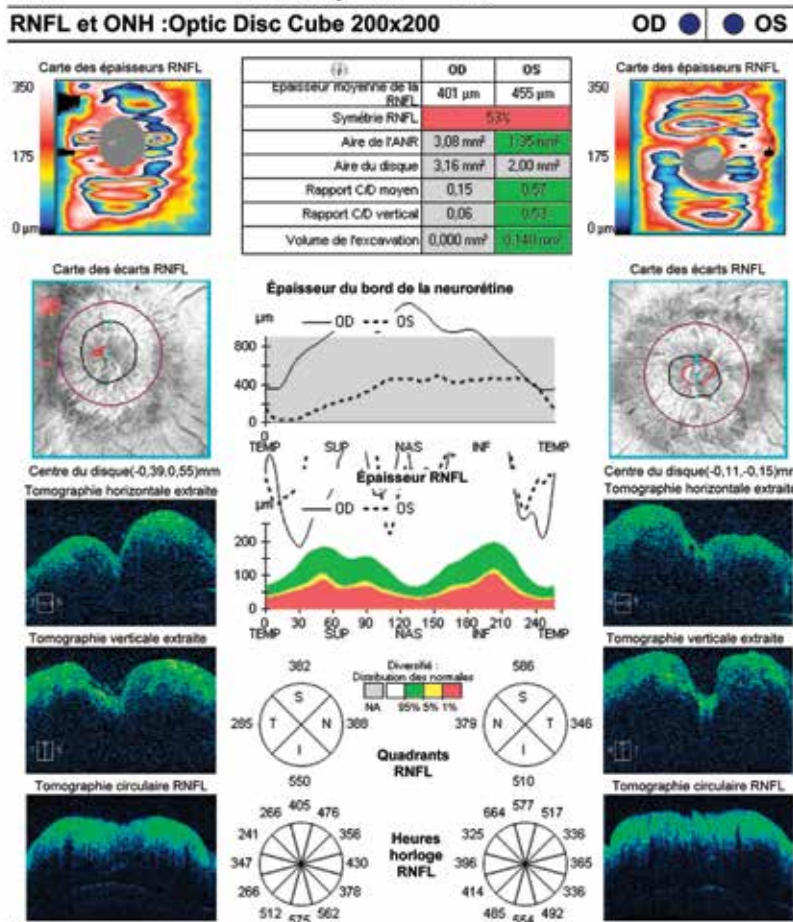
In the absence of subretinal oedema, it can be anticipated that visual function will improve during regression of papillary oedema. By contrast, the presence of subretinal oedema associated with papillary oedema indicates a less favourable prognosis. OCT can readily distinguish between intra- and subretinal oedema in the parapapillary region (Figures 78 and 79).



Right eye

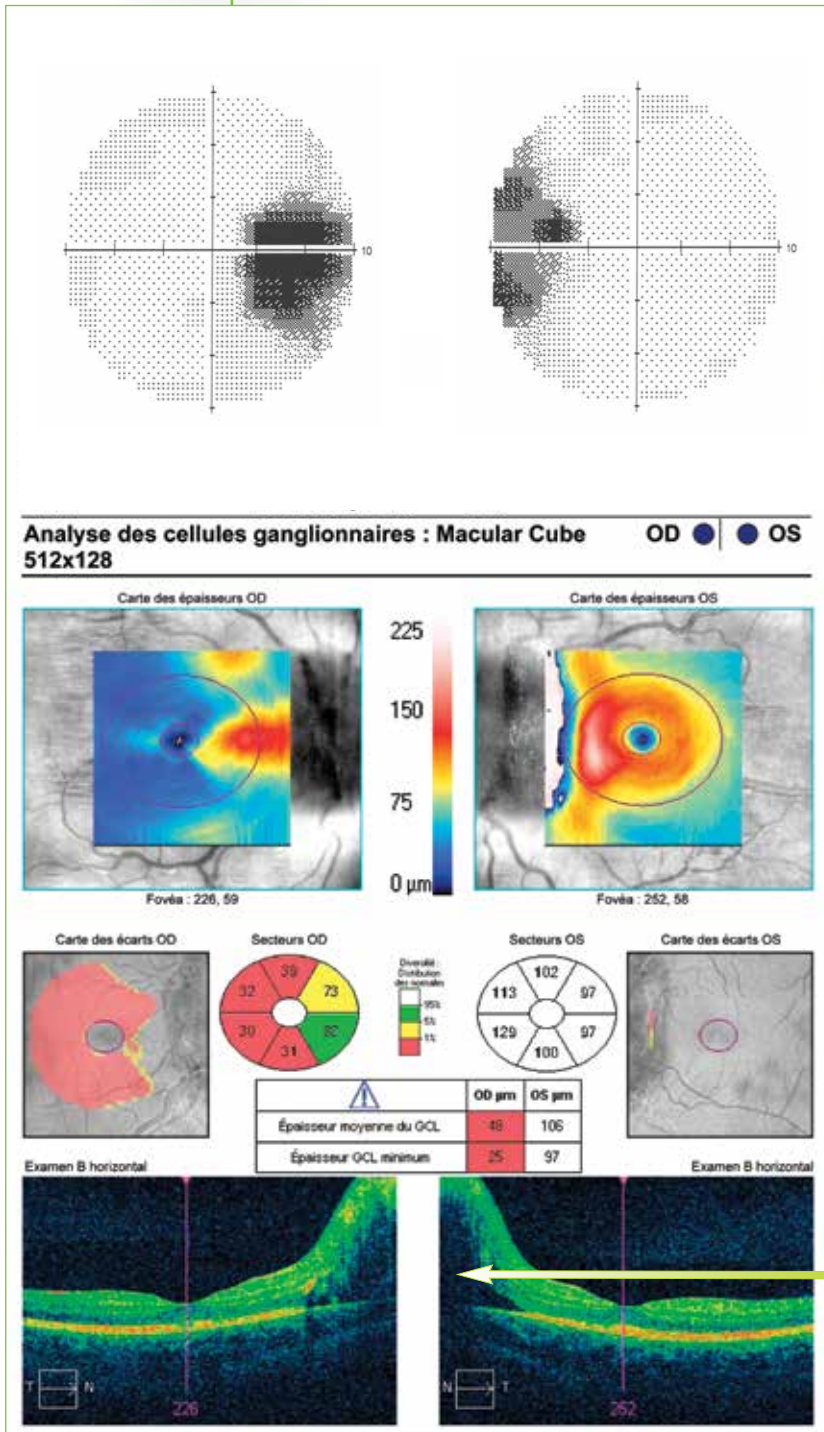


Left eye



OCT and visual field test findings in a 23-year-old patient with decreased visual acuity of unexplained origin. Bilateral papillary oedema is present in the ocular fundus, and the visual fields show enlargement of the blind spot on both sides. OCT reveals an increase in RNFL thickness due to oedema, associated with an absence of optical fibre impairment.

Figure 78

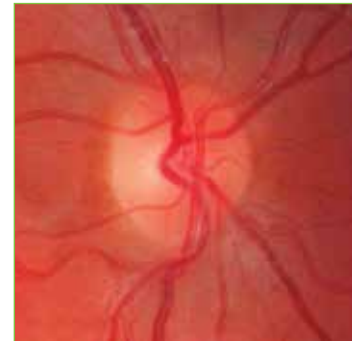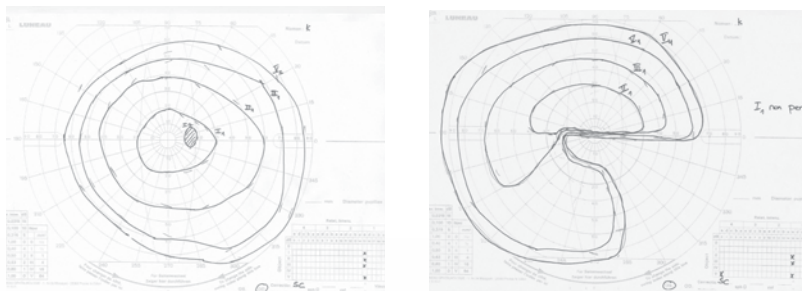


Macular cube OCT and central 10° visual fields in the same patient as in Figure 78. In the macular region, the ganglion cell complex is already altered in the right eye, whereas in the left eye this impairment is hidden by oedema (arrow).

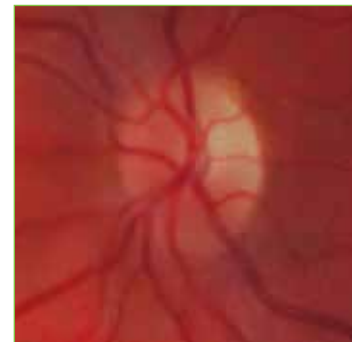Figure 79

Optic nerve compression

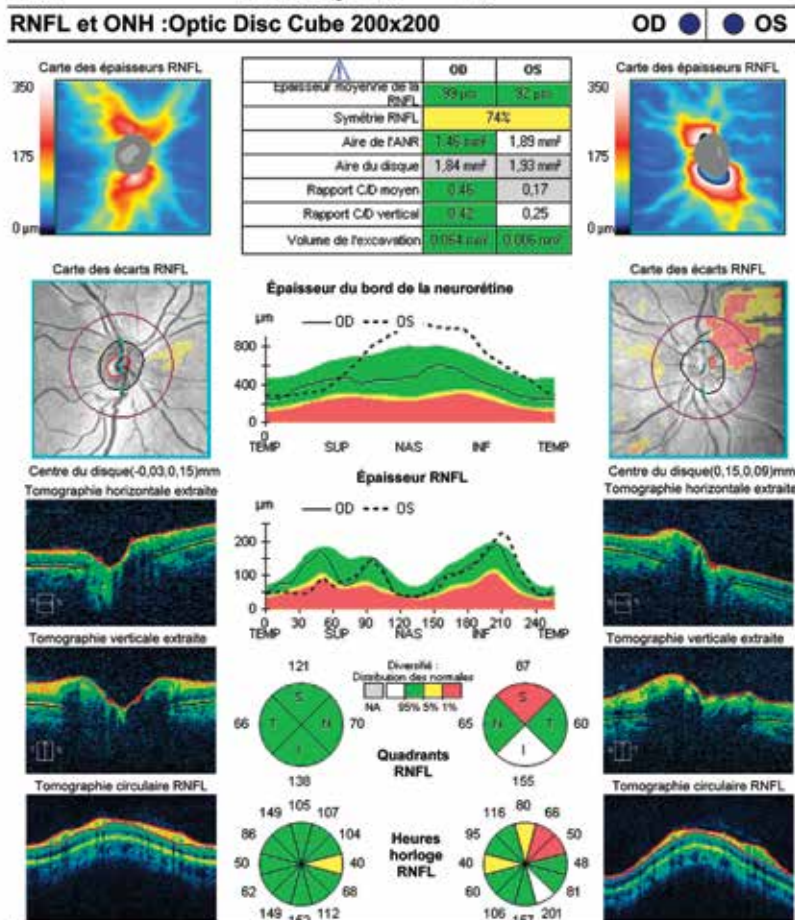
Optic nerve compression is sometimes difficult to identify because atrophy of the optic nerve may be accompanied by secondary excavation. As a result, this condition is sometimes misdiagnosed as glaucoma.



Right eye



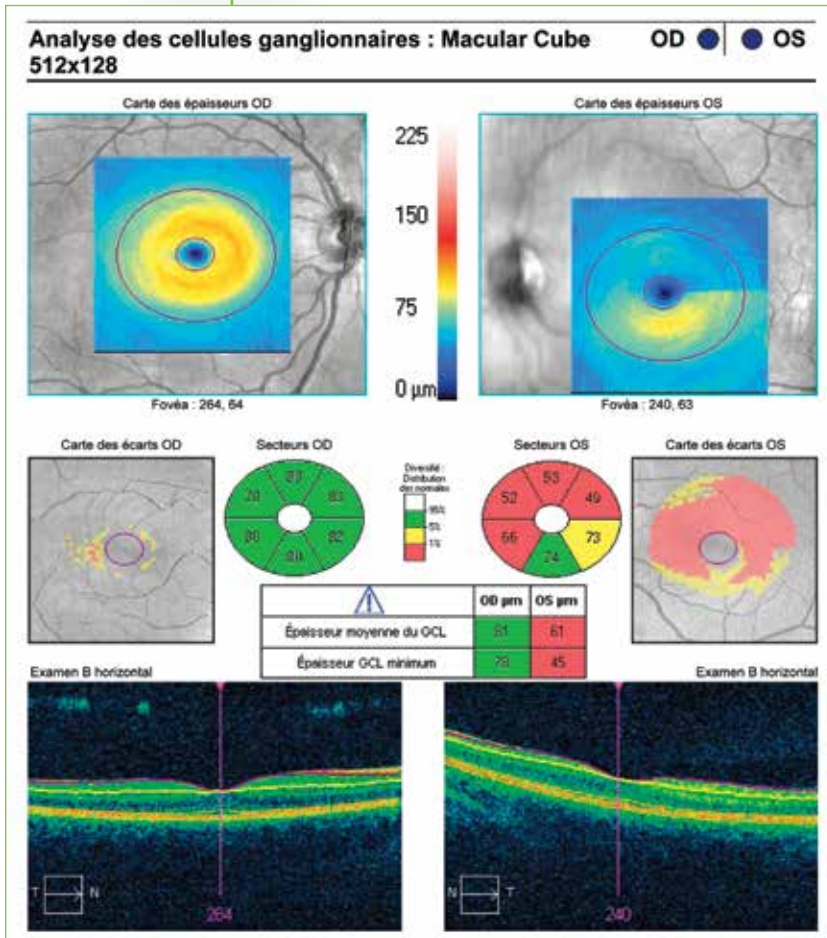
Left eye



OCT and visual field test findings in a 23-year-old patient with glioma in the left optic nerve. The impairment is purely unilateral, reflecting the absence of compression in the other eye. Although there appears to be evidence of excavation of the optic nerve head, this is not confirmed by OCT.

Figure 80

Optic nerve compression is usually unilateral, and hence normal findings in the contralateral eye can help to establish the diagnosis (Figures 80 and 81).

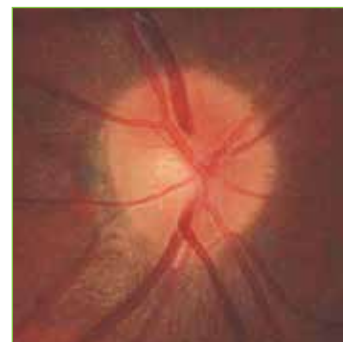
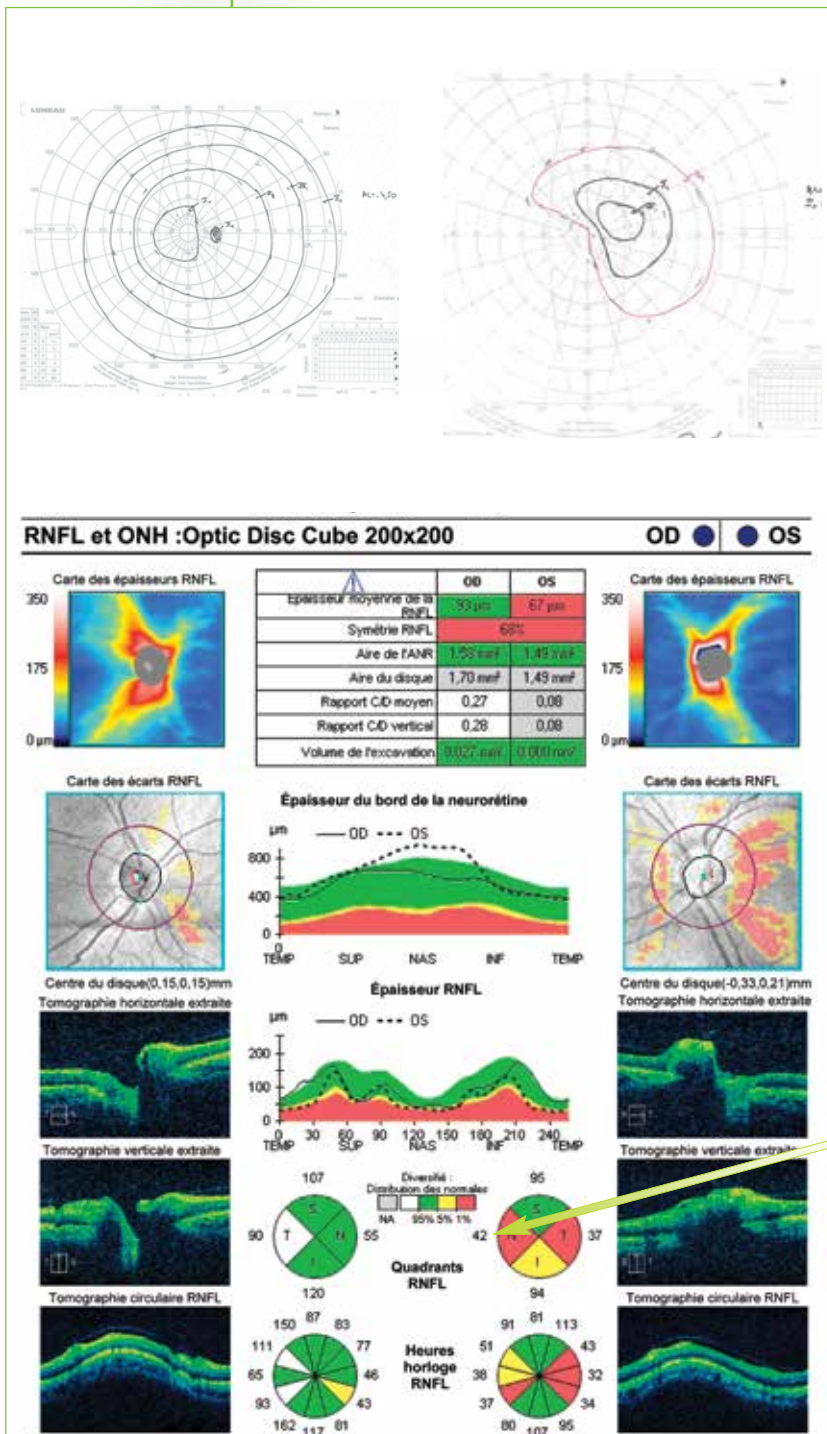


Macular cube OCT from the same patient as in Figure 80, showing diffuse and isolated macular impairment in the left eye.

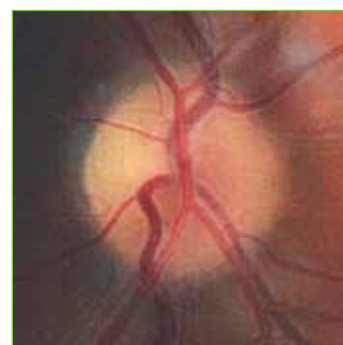Figure 81

Chiasma impairment

OCT changes and visual field loss are seen in patients with chiasma impairment (Figures 82 and 83). A favourable prognostic factor for functional recovery after surgery, is the maintenance of an RNFL thickness of at least 80 μm in the affected zone³⁷, although postoperative improvement is also seen in patients in whom the RNFL is thinner than this. Thus, in compressive neuropathies, the thickness of the RNFL is an indicator of the probability of clinical improvement after surgery: the thicker the fibres preoperatively, the better the likely recovery.



Right eye

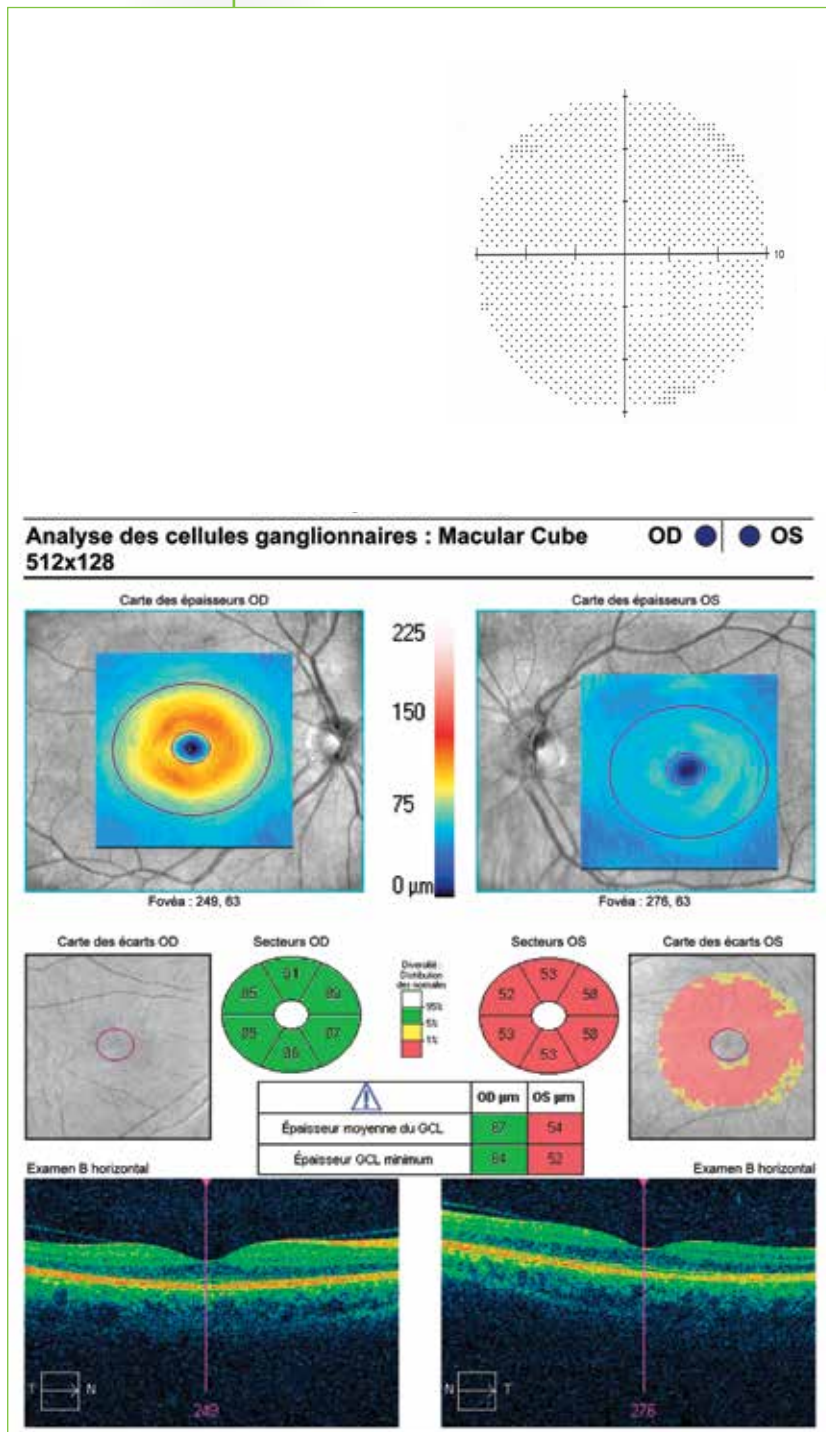


Left eye

OCT and visual field test results in a patient affected by prechiasmatic meningioma mainly compressing the left optic nerve. Visual acuity was less than 1/20th on the left and normal on the right. The optic nerve is normal on the right and slightly pale on the left. OCT of the optic nerve head shows nasal and temporal impairment with a very thin fibre layer at these sites (42 μm and 37 μm , respectively). There is no excavation. While Goldmann's visual field testing appears to show early impairment in the right eye, OCT findings are normal.

Figure 82

Importantly, the RNFL is not always affected during early stages of optic nerve or chiasma compression: in some cases, changes in the visual field are the first signs of impairment. This therefore constitutes one of the rare cases where the absence of RNFL thinning does not indicate optical neuropathy.

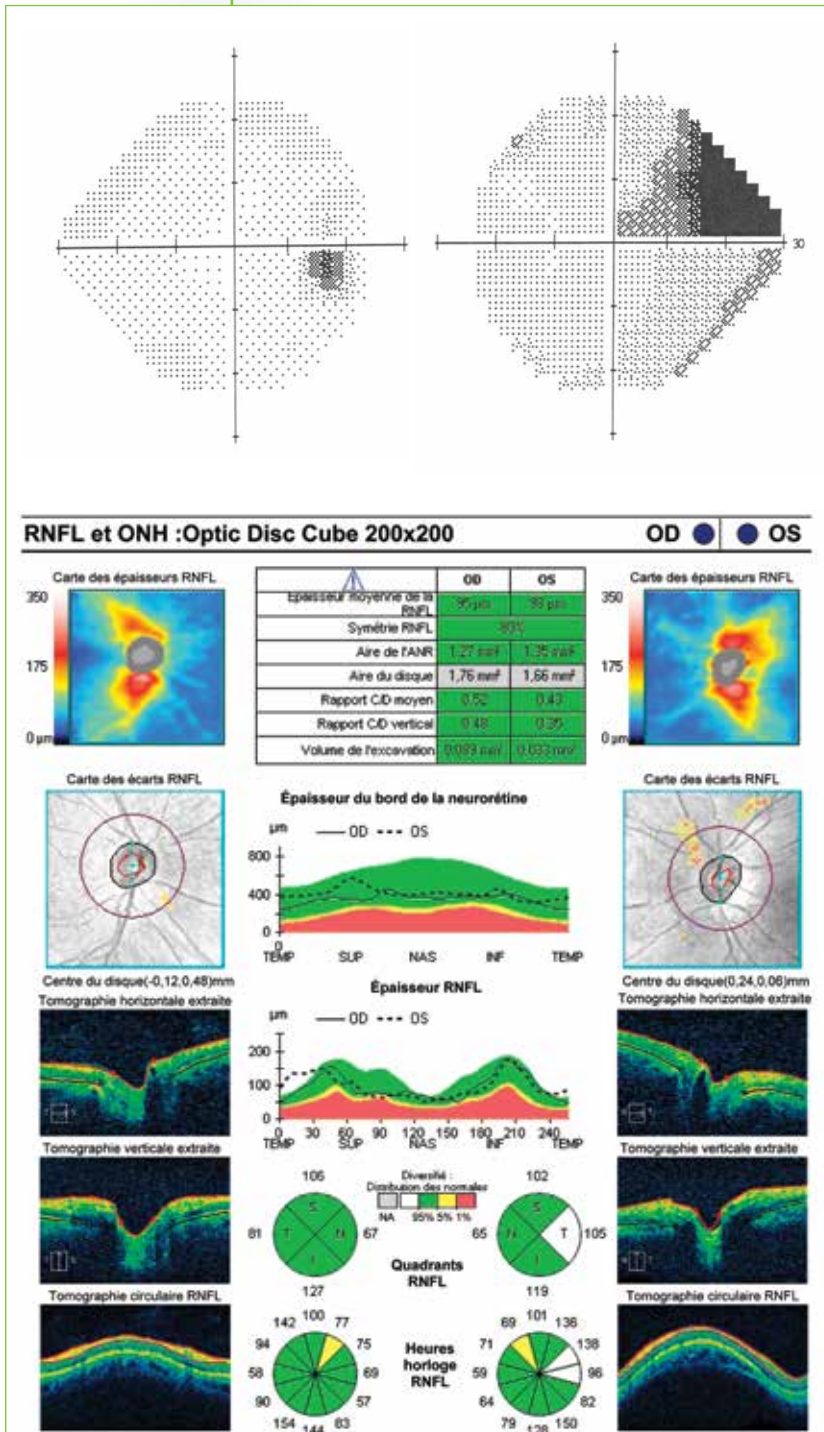


Macular cube OCT in the same patient as in Figure 82. There is diffuse and isolated macular impairment of the left eye; most patients with optic nerve compression show such diffuse impairment.

Figure 83

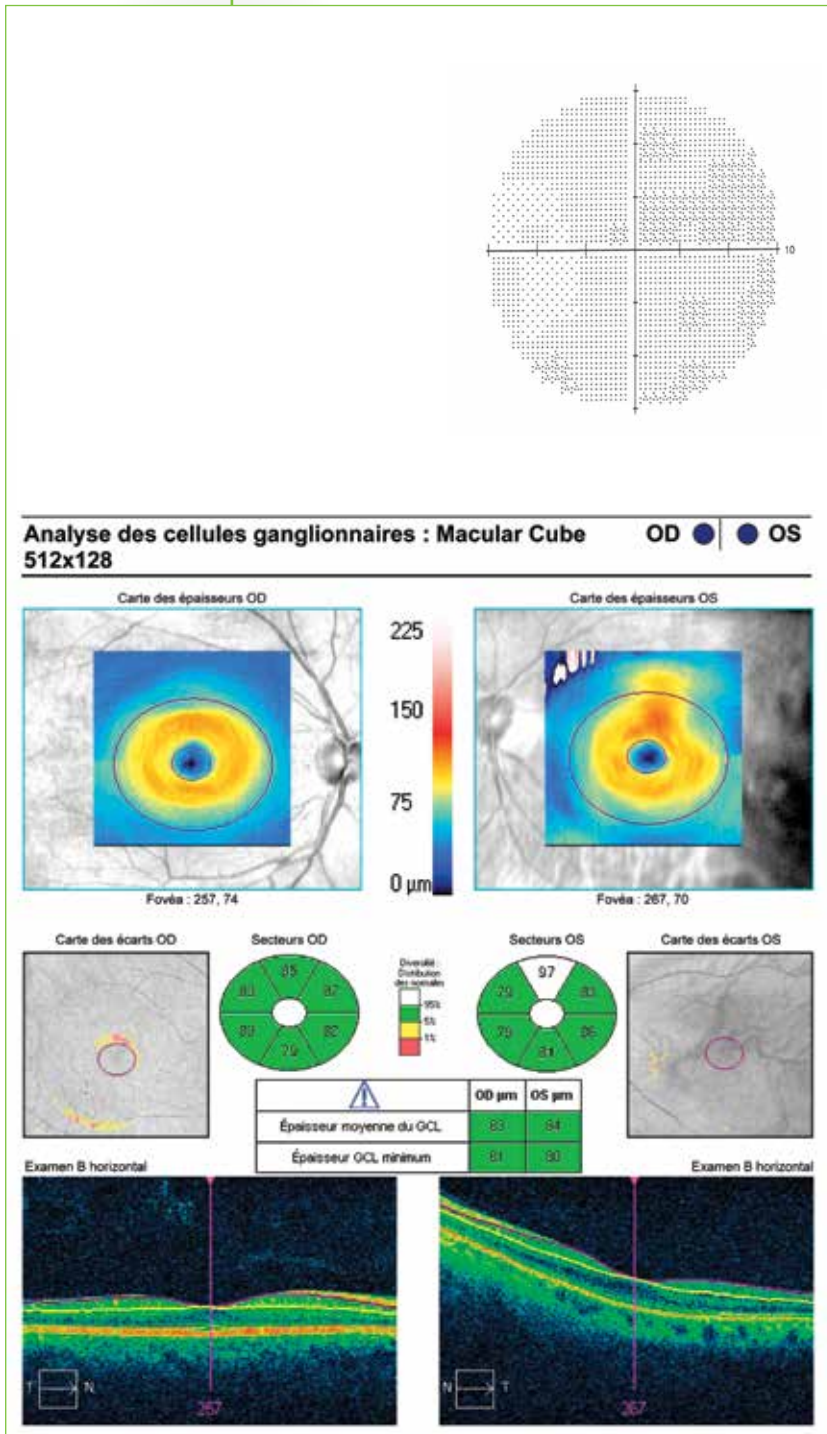
Amblyopia

Amblyopia is characterized by decreased visual acuity in the affected eye. Ganglion cells are present, but non-functional. OCT parameters are only slightly altered (Figures 84 and 85).



OCT and visual field test results in a 48-year-old patient with amblyopia in the left eye (visual acuity 2/10th). Visual field testing shows a nasal deficit of unexplained origin. However, OCT findings are normal, both in the peripapillary region and the optic nerve.

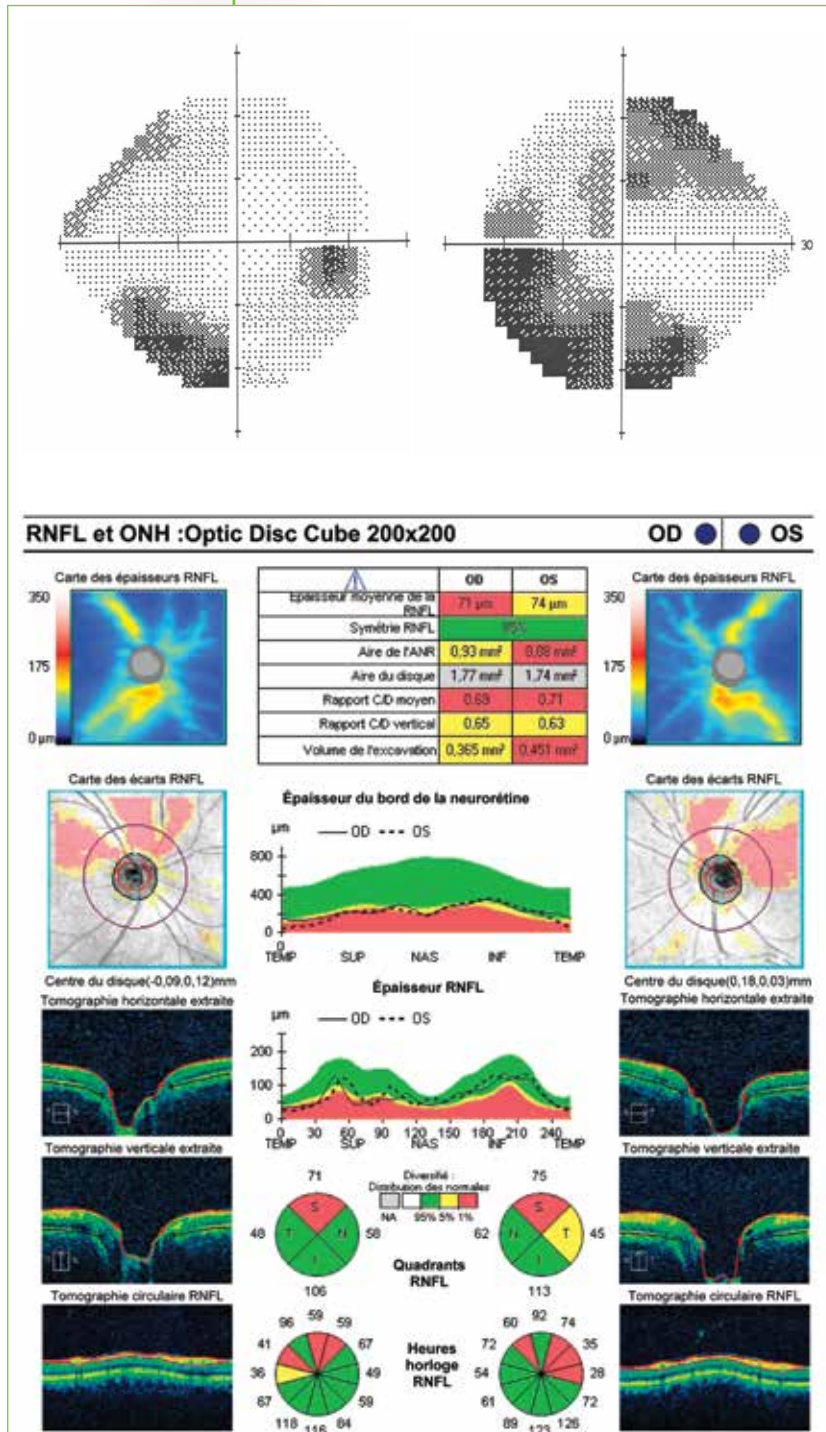
Figure 84



Macular cube OCT and central 10° visual fields in the patient shown in Figure 86. The central visual field of the left eye shows a diffused deficit consistent with a visual acuity of 2/10th. OCT findings are normal.

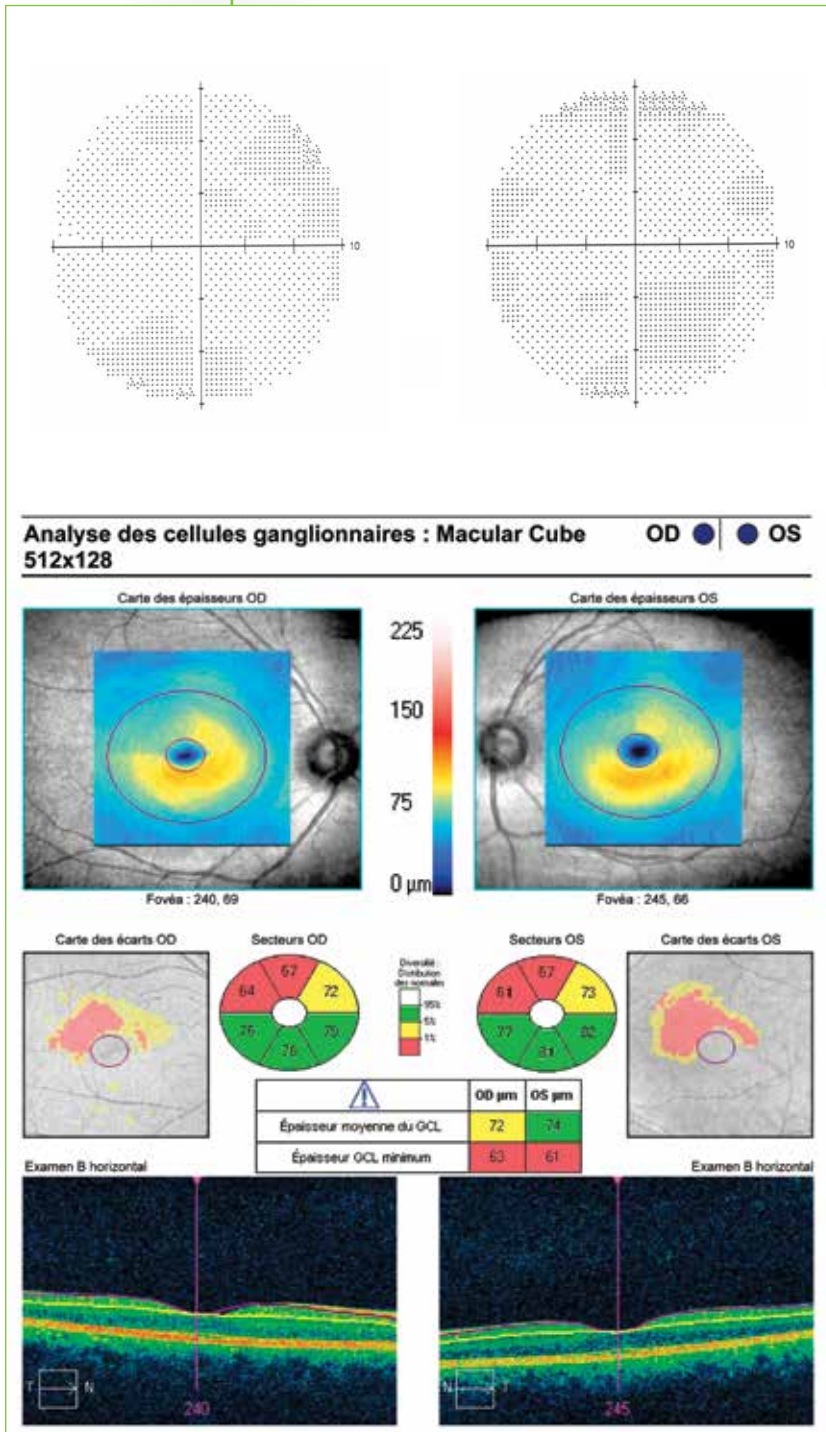
Figure 85

Although it might be expected that decreases in the thickness of the RNFL would be seen only when cell bodies or axons in this layer are directly affected by disease, there is evidence that even isolated lesions in the occipital cortex can manifest as a decrease in RNFL thickness on OCT. This situation was first documented in cases of congenital or perinatal pathologies (Figures 86 and 87), but it is not certain whether it also applies to acquired impairments.



OCT and visual field test results in a 42-year-old patient with sequelae of epilepsy and slight mental retardation associated with perinatal injury. The visual field is irregular with lower homonymous lateral deficit, but the optic nerves are normal. Although the underlying pathology is central in origin, thinning of the RNFL is seen on OCT.

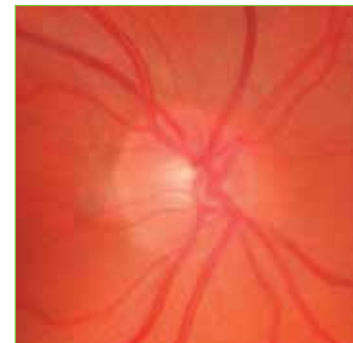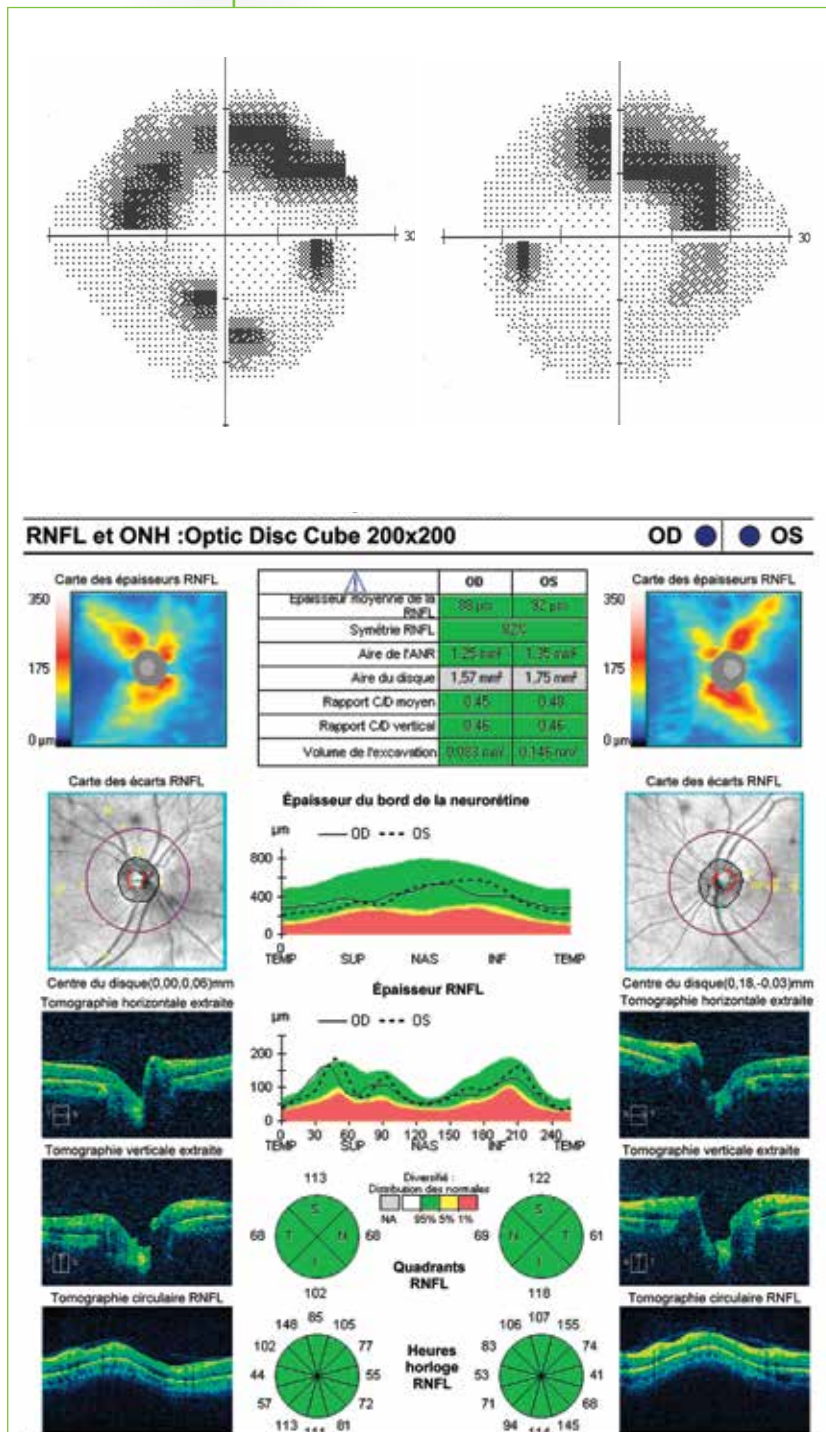
Figure 86



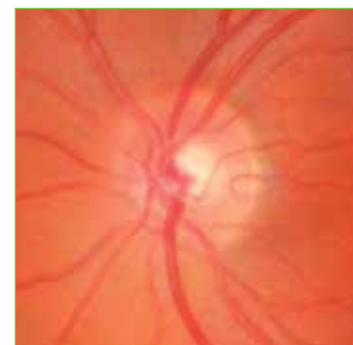Macular cube OCT and central 10° visual fields in the same patient as in Figure 86. The central visual field is irregular, and the macular OCT shows bilateral impairment.

Figure 87

Isolated impairment of the central nervous system in adults is reflected in much greater changes in visual fields than in OCT findings (Figures 88 and 89), although OCT parameters may be affected by trans-synaptic degeneration from the occipital lobe to the optic nerve ³⁸.



Right eye

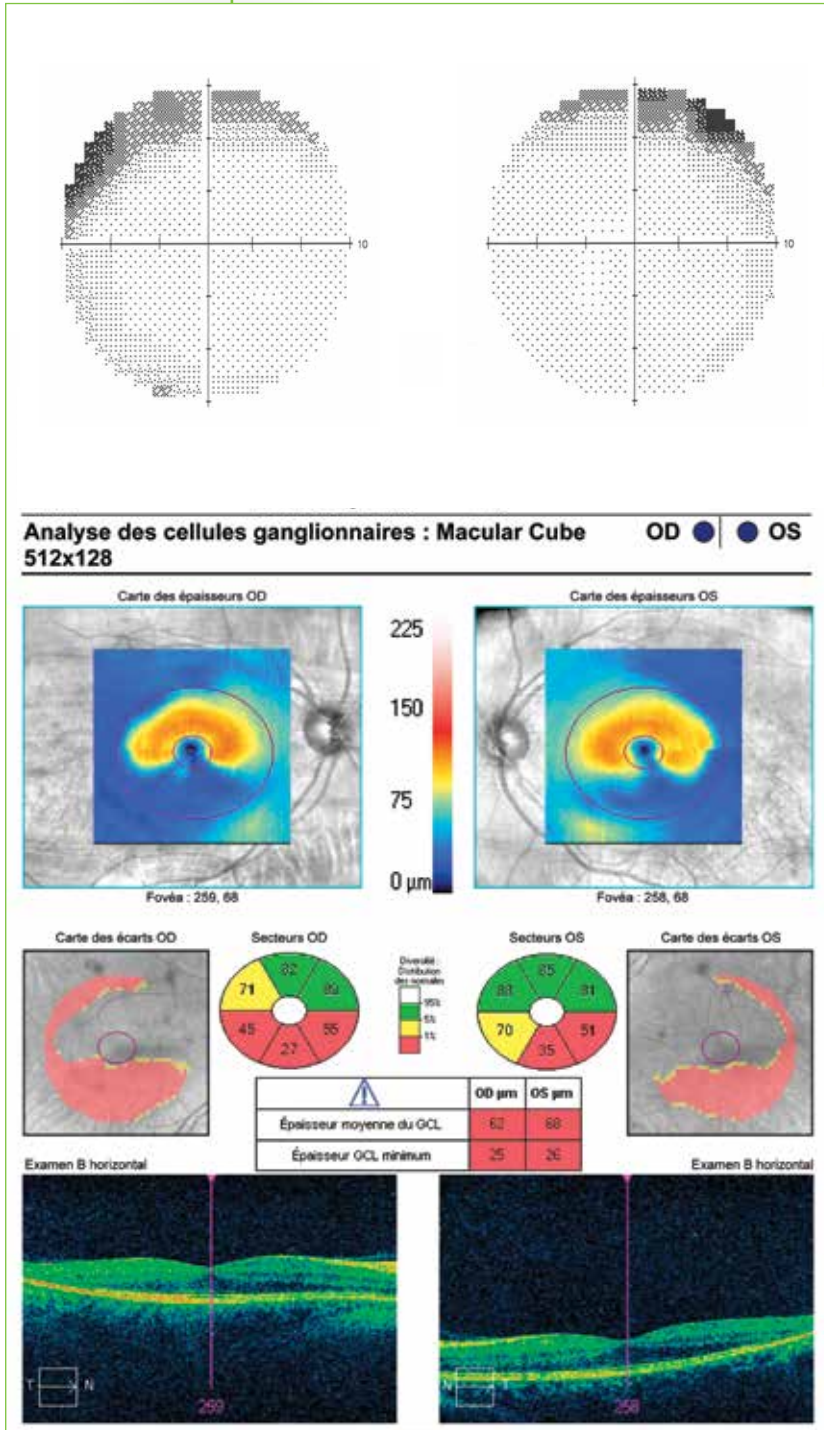


Left eye

OCT and visual field test results in a 49-year-old patient. The visual field tests show an unexplained, relatively symmetrical, bilateral deficit in the upper field. The OCT findings are normal, and the optic nerves also appear clinically normal.

Figure 88

Normal OCT findings in a patient with decreased visual acuity or impairment of the visual field can thus be helpful in confirming a neuro-ophthalmological cause of the symptoms ³⁸.



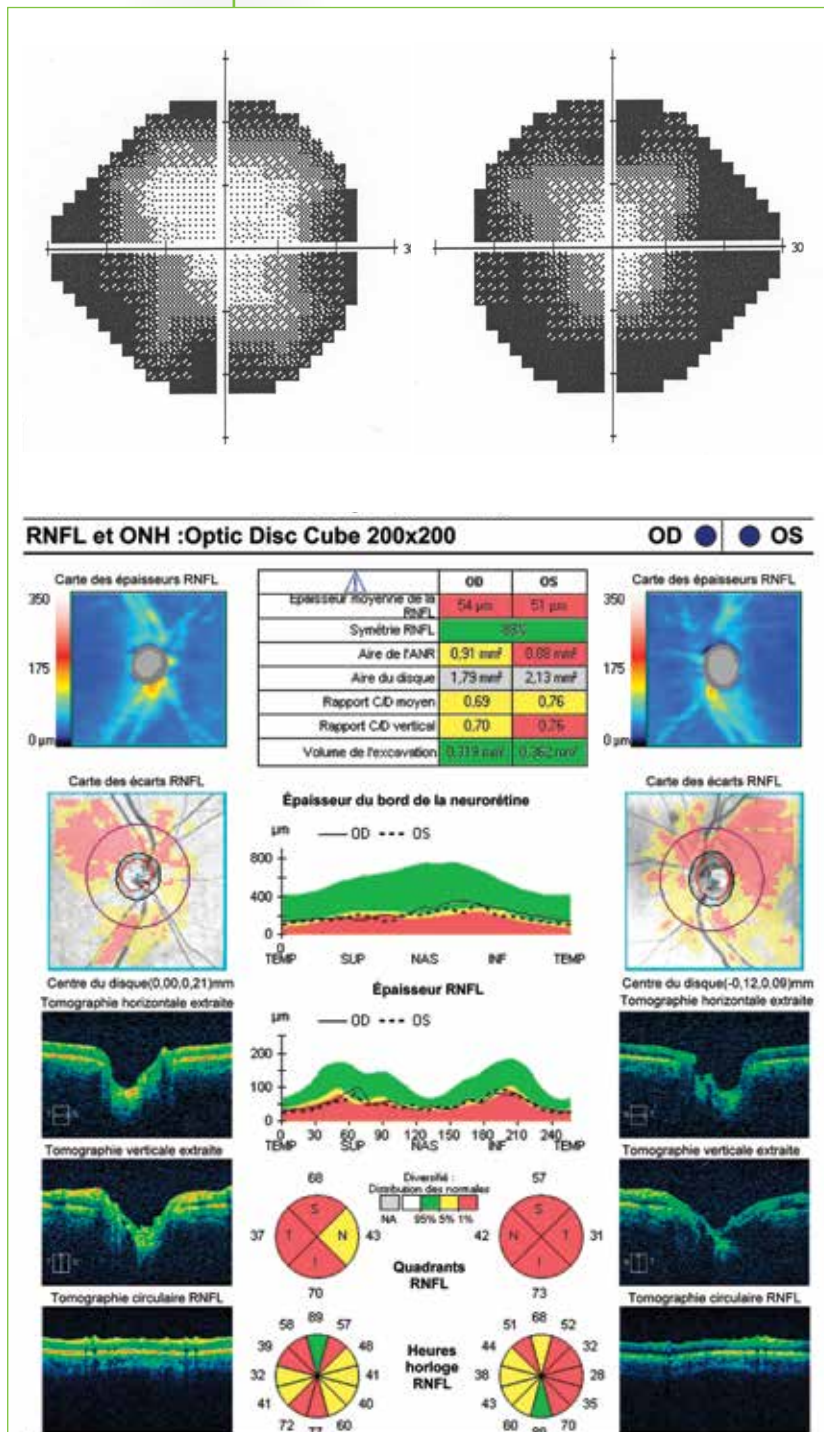
Macular cube OCT and central 10° visual fields in the same patient as in Figure 88. There is minor impairment of the ganglion cell complex, whereas there is a very marked perimetric deficit. The underlying cause of these deficits is probably central in origin.

Figure 89

In many situations it is difficult to establish the organic origin of functional symptoms. Examples of such situations include:

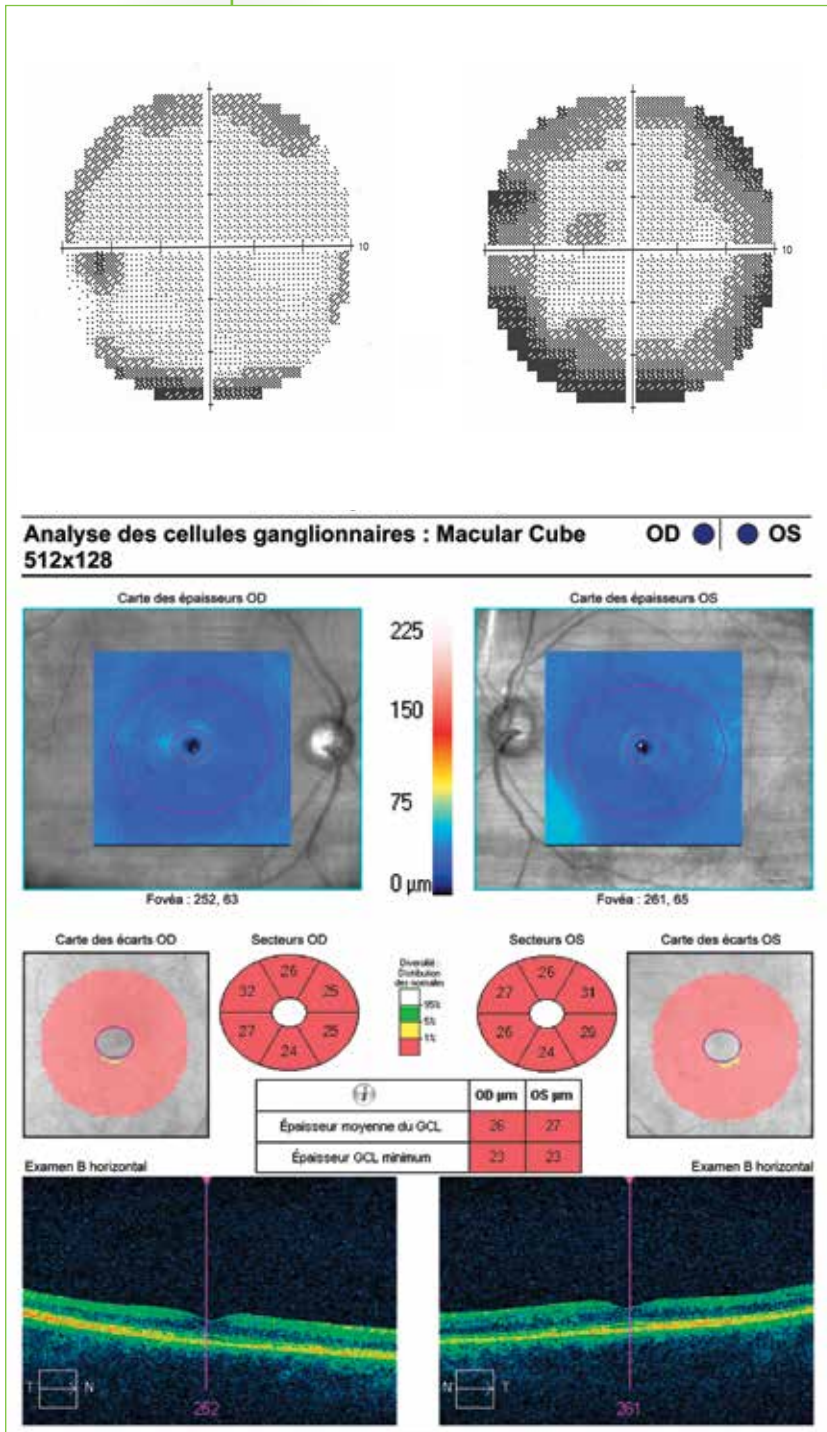
- post-cranial trauma
- perimetric deficits of hysteric origin
- ill-defined pathologies.

In such cases, OCT can be used to determine the organic or non organic nature of the functional deficits (Figures 90 and 91).



OCT and visual field test results in a 60-year-old patient with reduced visual acuity (6/10th) after general anaesthesia. The visual fields show an inexplicable bilateral centrocaecal deficit, while OCT reveals major diffuse impairment of the RNFL, without excavation; the optic nerves appear to be clinically normal. Neuropathy due to low choroidal flow rate may explain these findings.

Figure 90



Macular cube OCT and central 10° visual fields in the same patient as in Figure 90. The ganglion cell complex is significantly impaired, confirming the organic nature of the patient's complaint.

Figure 91

In more general pathologies such as Alzheimer's disease or Parkinson, we also observe a reduction of optical fibres in OCT. In certain cases, this reduction is diffuse and sometimes located in the superior region³⁹.

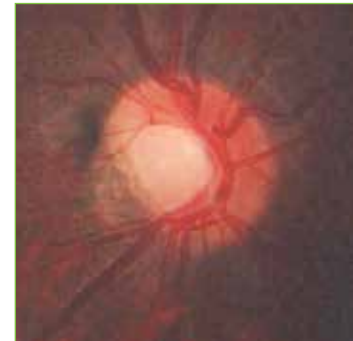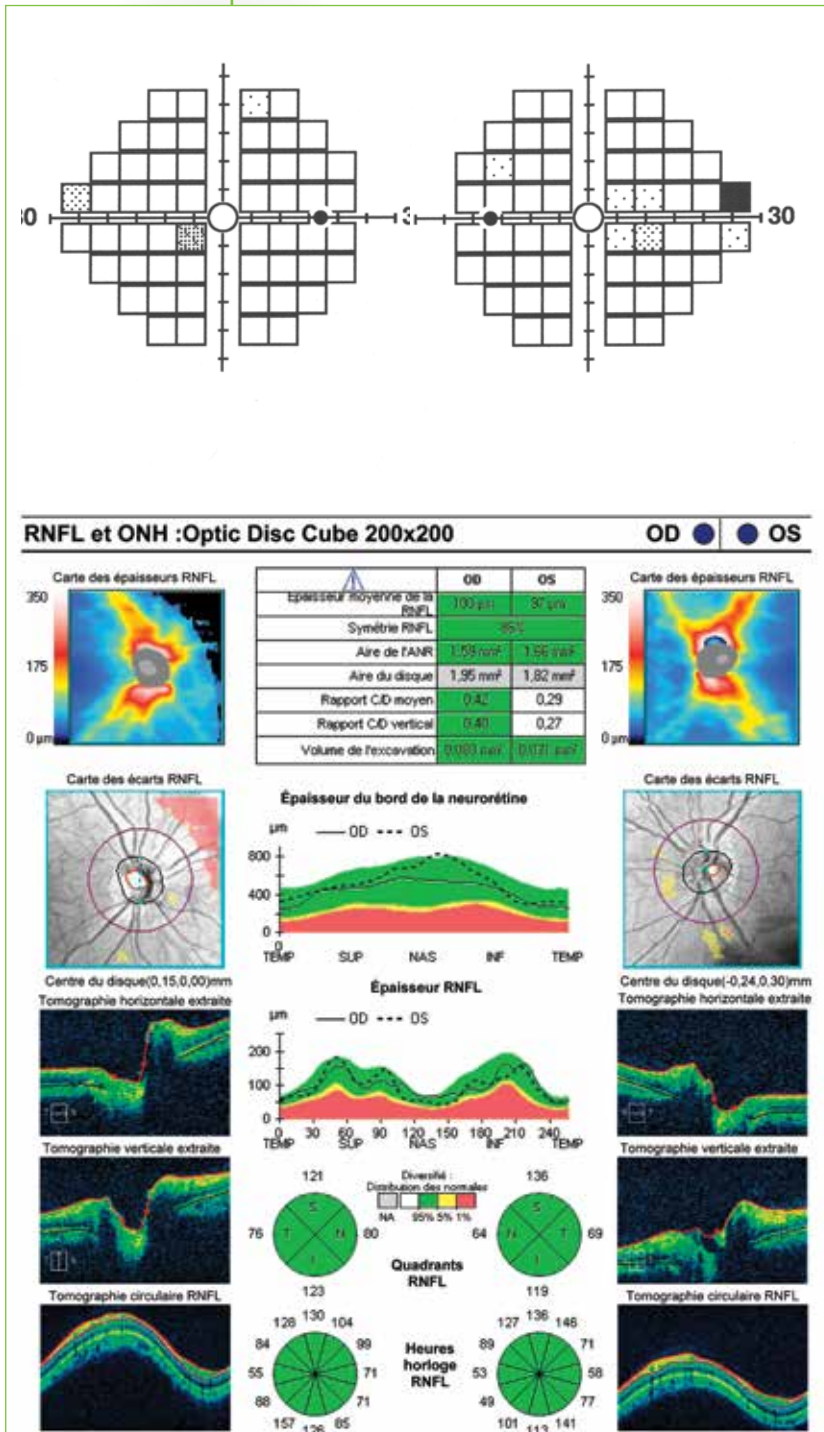
In Alzheimer's disease, a reduction of the RNFL and the macular ganglion cell layer is observed, but this is not directly related with the level of cognitive functions.

In Parkinson's disease, a certain relationship between reduction of the optical fibre layer and the functional repercussions of Parkinson's disease has been found.

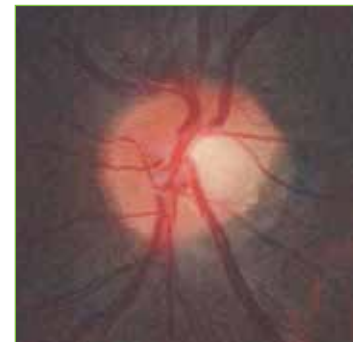Atypical features of the optic nerve that can suggest optic neuropathy in OCT

Numerous atypical features of the optic nerve can lead to changes in papillary OCT parameters. In some cases, faulty measurement techniques can result in incorrect diagnoses. OCT measures excavation based on a reference plane, which is arbitrarily set at 150 μm above the level of the peripapillary pigment epithelium: if the pigment epithelium is not analysed correctly, all the results may be wrong. For this reason, papilla sections, indicating the theoretical start of the excavation with a red point, are displayed, enabling the ophthalmologist to determine whether or not the points are placed coherently.

Moderate myopia does not cause changes in OCT parameters (Figures 92 and 93). In the event of peripapillary atrophy, it should be ensured that the measurement 3.4 mm from the centre of the optic nerve is located outside the atrophic region, in order to obtain good quality measurements.



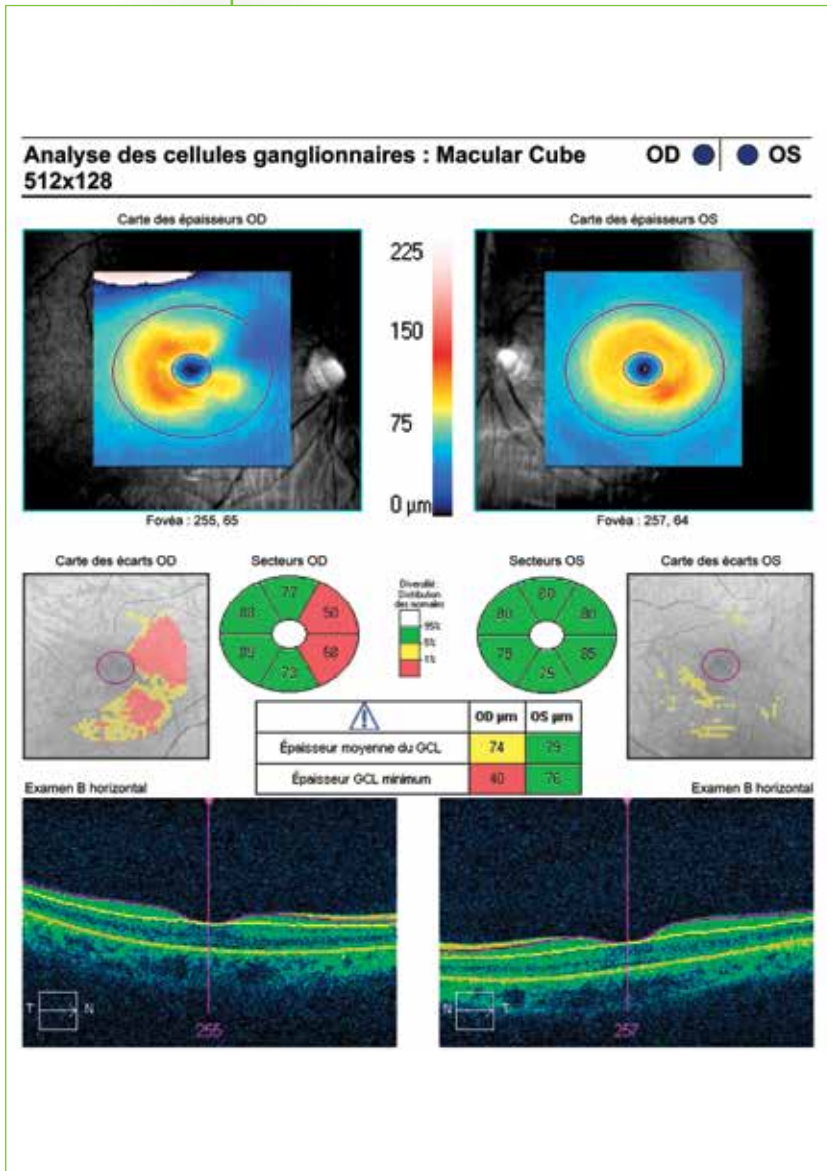
Right eye



Left eye

OCT and visual field test results from a patient with myopia (6 dioptres) and mild lower temporal dysversion. There are irregularities in the matrix visual field test results, but OCT findings are normal.

Figure 92



Macular cube OCT in the patient shown in Figure 92. There are ganglion cell complex abnormalities in the right eye. However, this result indicates only that a pathological process is developing.

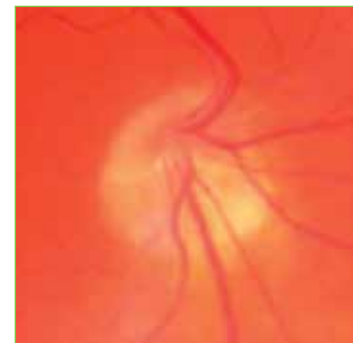
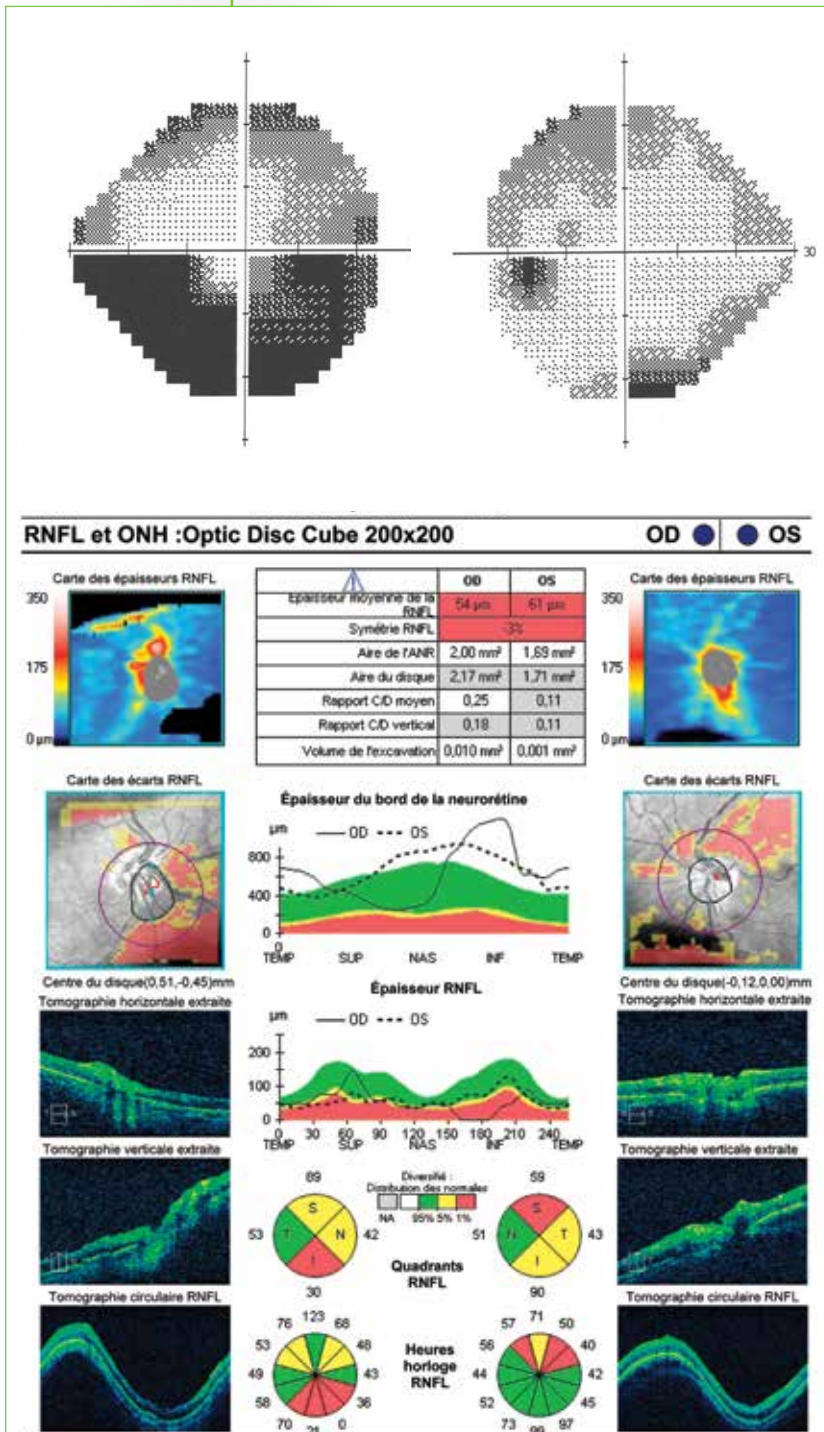
Figure 93

Papillary dysversion

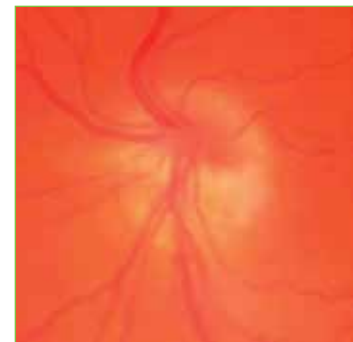Moderate dysversion of the papilla does not lead to changes in OCT parameters, particularly if the temporal axis is involved.

However, in some cases a slight nasal deficit may be observed, a feature that does not suggest glaucoma.

Conversely, more severe impairment, particularly affecting the nasal quadrant, can lead to significant changes in OCT parameters, which may be confused with those seen in glaucoma (Figures 94 and 95).



Right eye

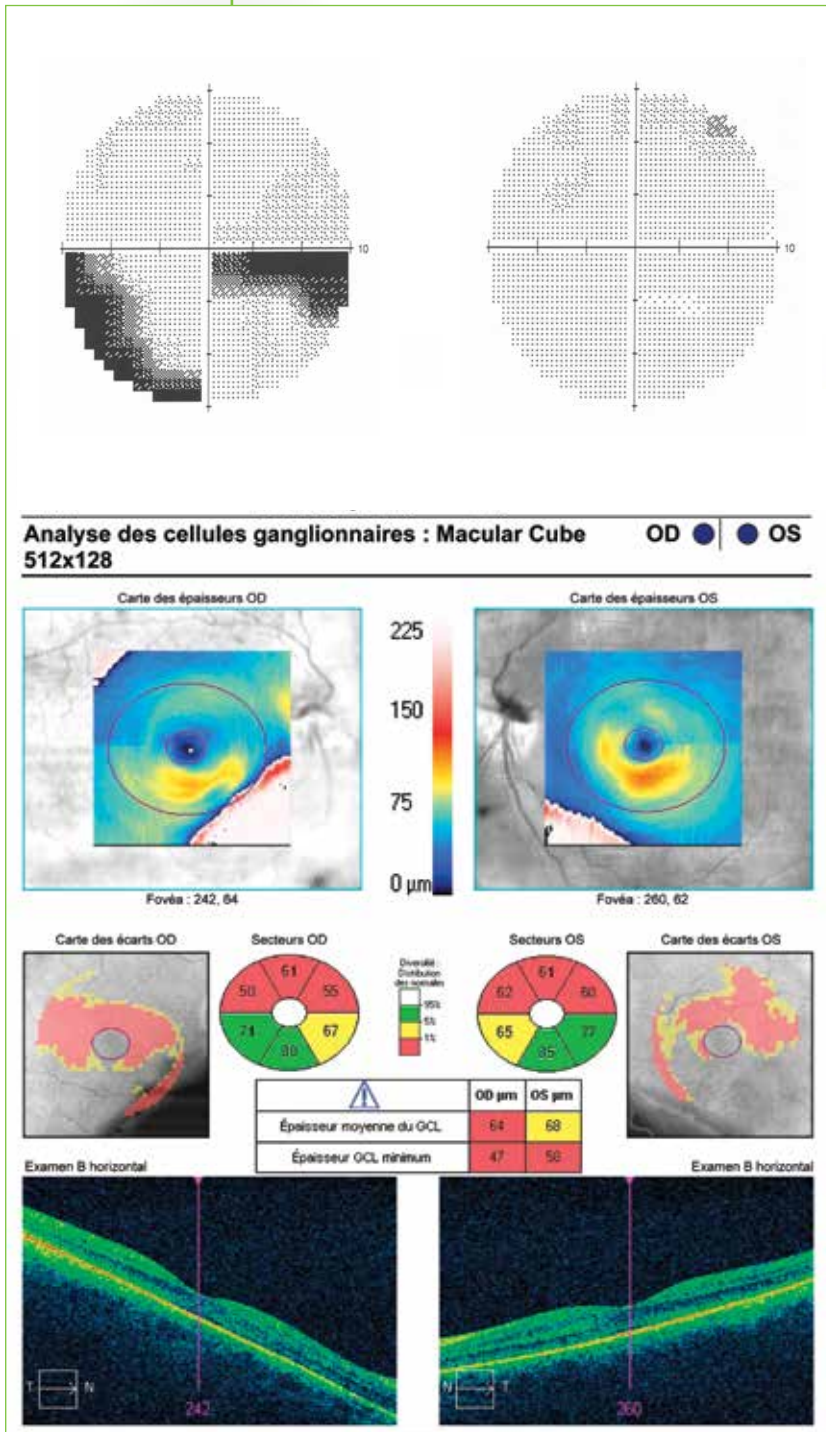


Left eye

OCT and visual field test results in a patient with bilateral dysversion. The visual field is affected mainly on the right, with changes in RNFL thickness suggestive of glaucoma. No excavation is visible on OCT.

Figure 94

The macular ganglion cell complex is easier to evaluate than the RNFL in patients with dysversion, because it is further from the optic nerve. This can reveal the presence of optical fibre impairment (Figure 95).



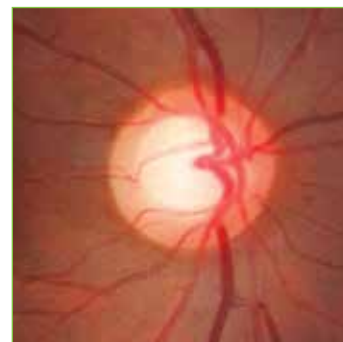
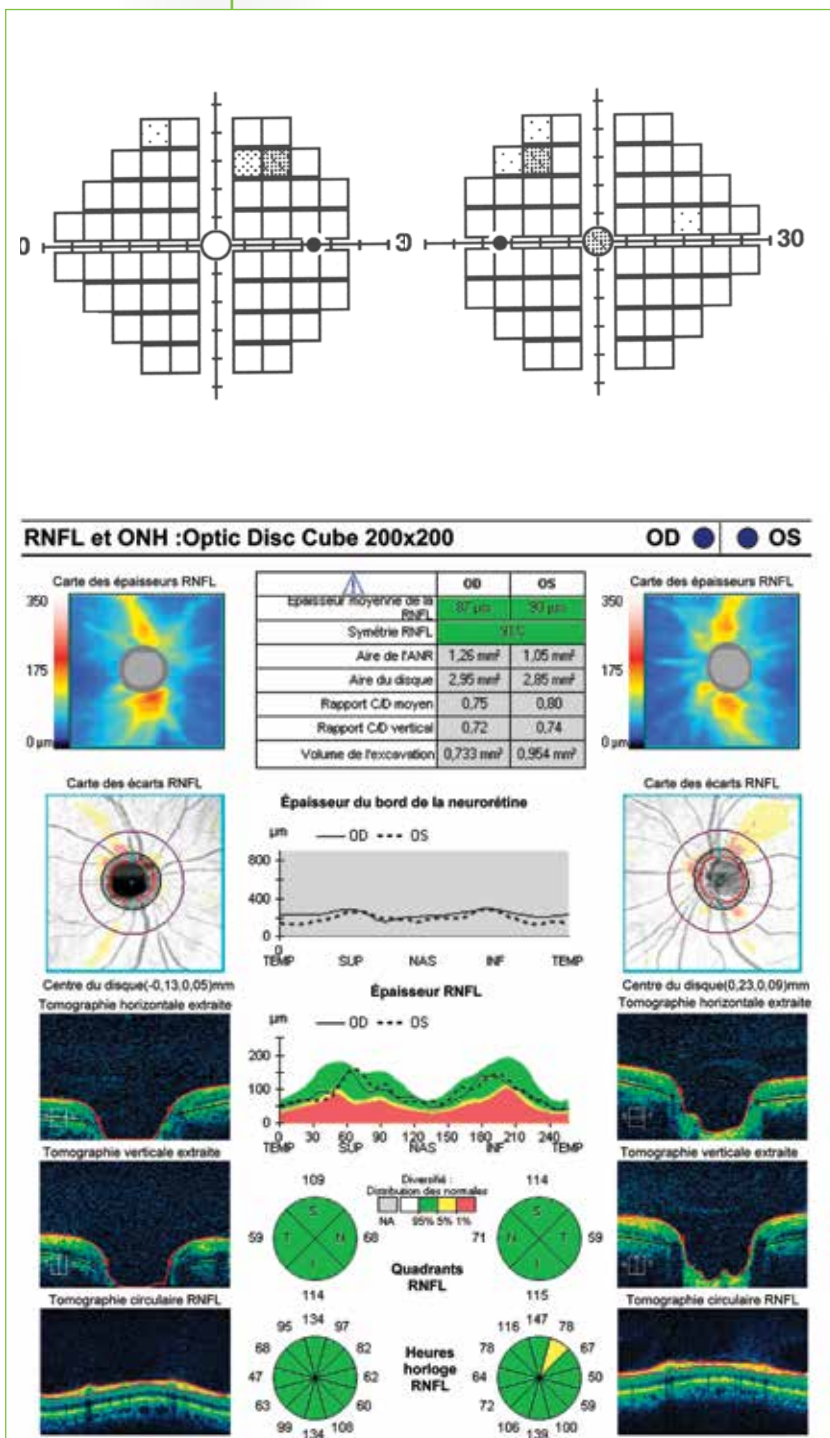
Macular cube OCT and central 10° visual fields in the patient shown in Figure 94. Analysis of the central region confirms the consequences of dysversion, in terms of both perimetry testing and OCT findings.

Figure 95

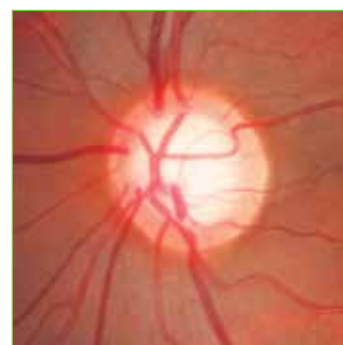Physiological excavation

The large papillae, which are responsible for physiological excavations, are reflected in the preservation of the RNFL and the macular ganglion cell complex on OCT (Figures 96 and 97).

Optic nerve OCT parameters are not usually compared with normative values, because the databases used do not generally include patients with physiological excavation.



Right eye

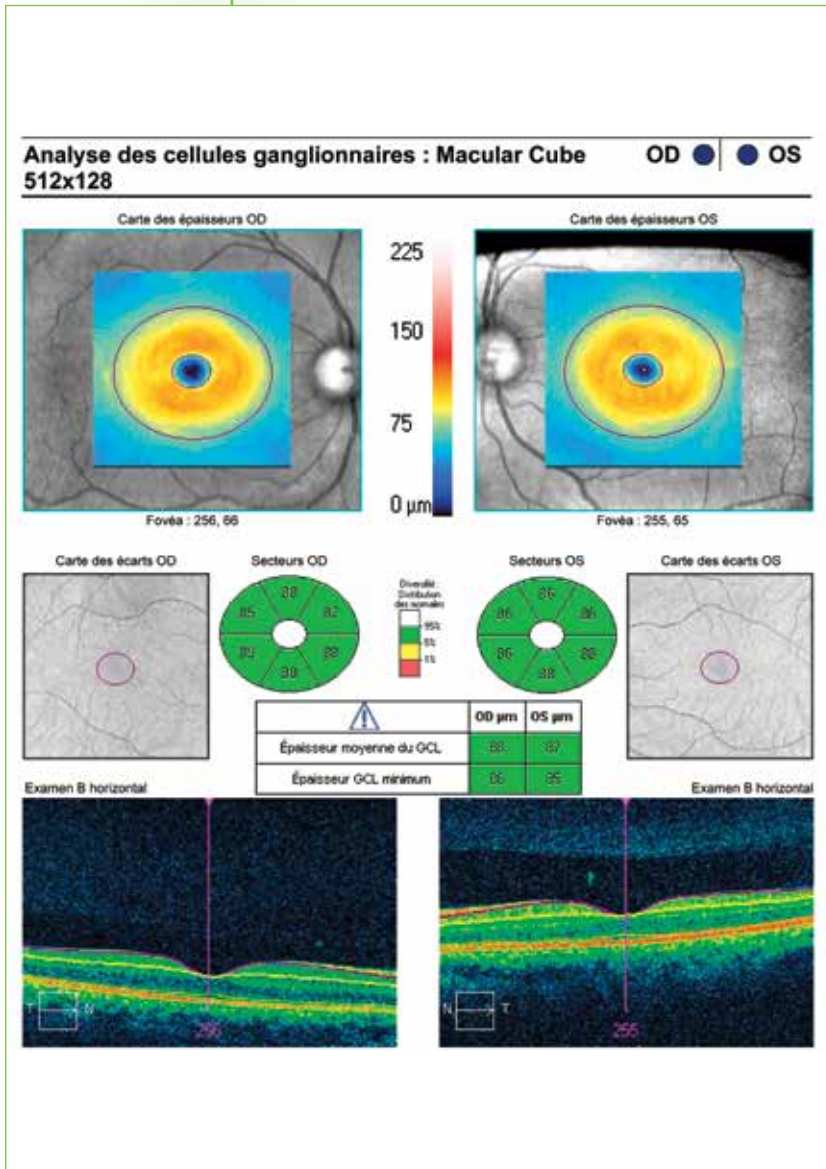


Left eye

OCT and visual field test results in a patient with bilateral physiological excavation. The RNFL is normal. The optic nerve parameters (shown in grey) have not been analysed statistically because the device does not include patients with such large disc areas in its database.

Figure 96

In patients with deep, and possibly physiological, excavation, optical fibre parameters should be considered in the diagnosis to a greater extent than optic nerve parameters.

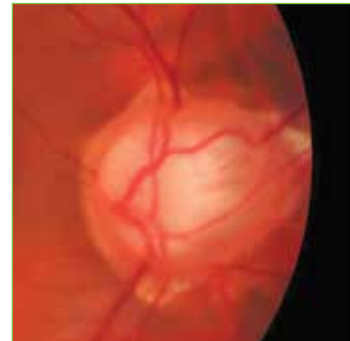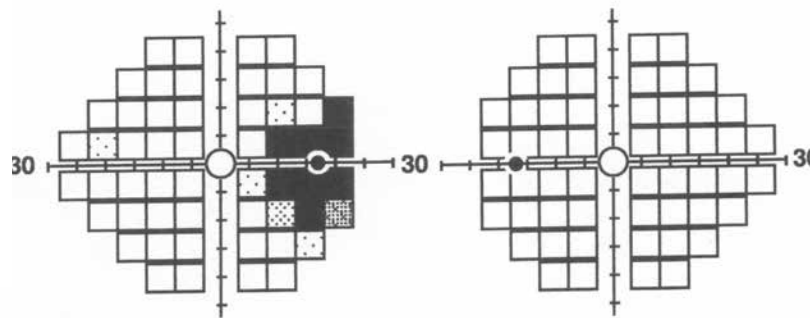


Macular cube OCT from the same patient as in Figure 96. The ganglion cell complex is normal.

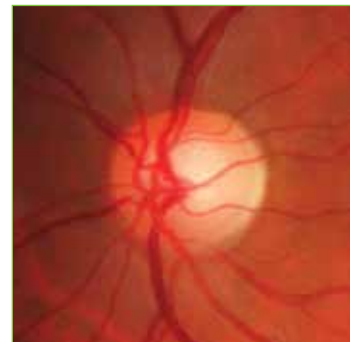Figure 97

Papillary coloboma

In patients with papillary colobomas, the changes seen on OCT affect the opposite side to the coloboma. Thus, the sectors usually affected in glaucoma, particularly the lower temporal region, are not affected if this region is the seat of the coloboma (Figures 98 and 99).



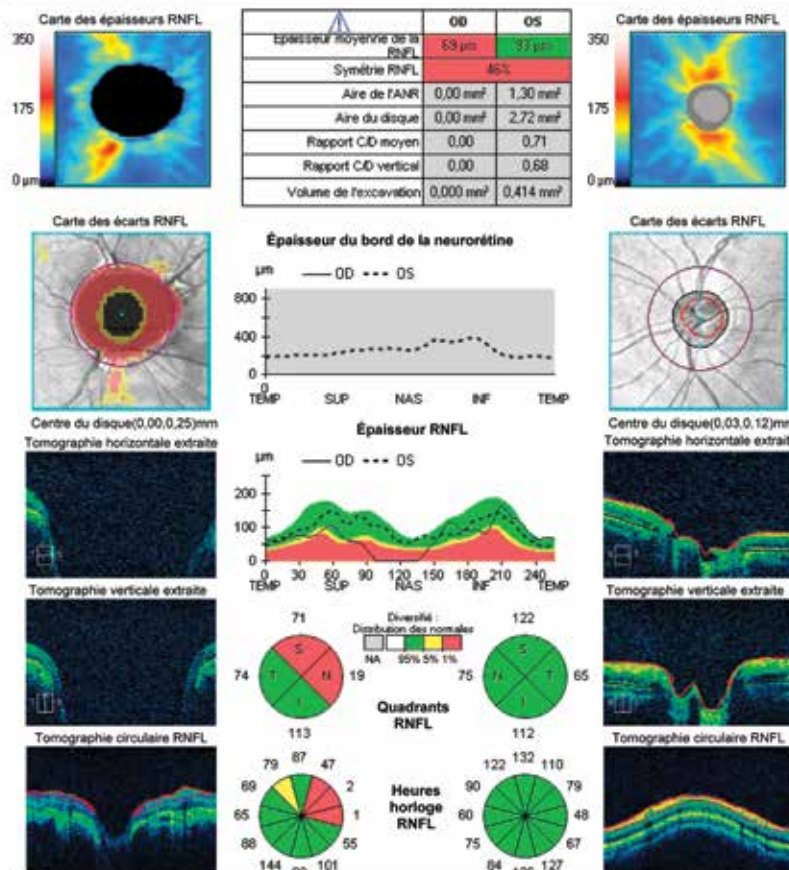
Right eye



Left eye

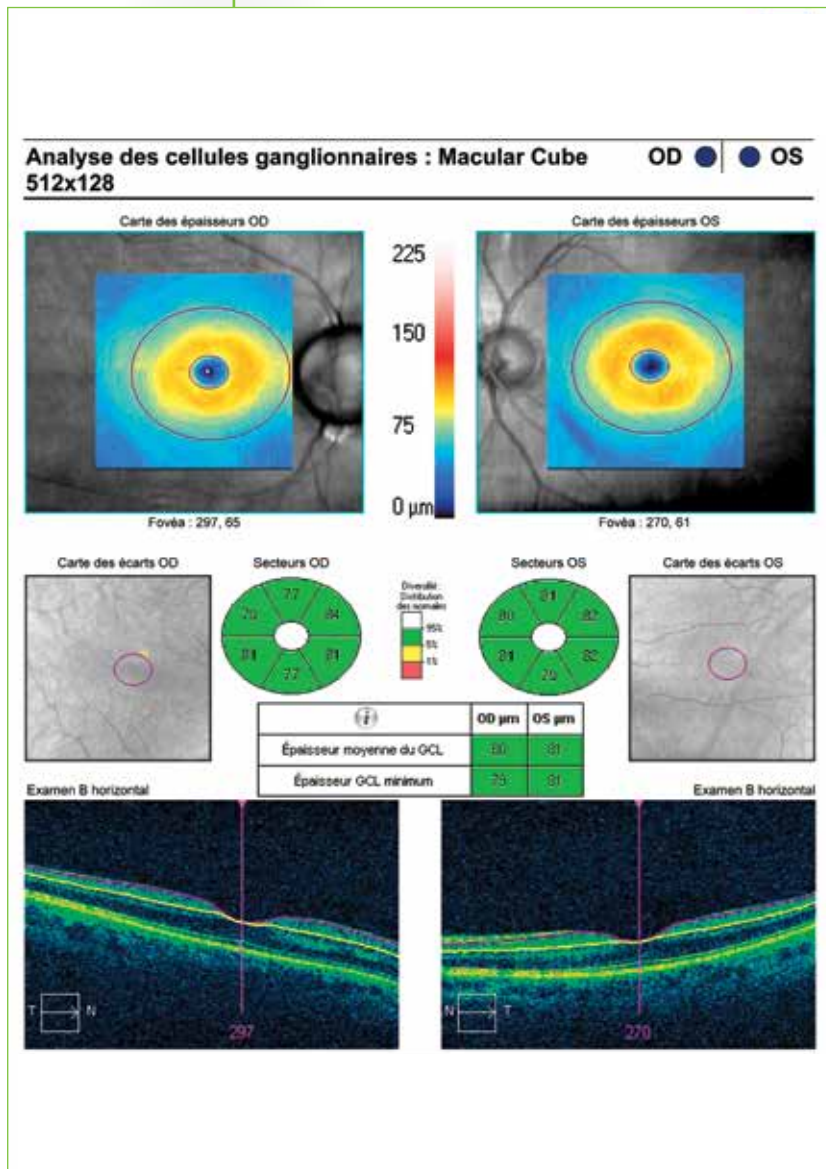
RNFL et ONH :Optic Disc Cube 200x200

OD OS



OCT and visual field test findings in a patient with nasal coloboma of the right papilla. Changes in OCT findings are seen in the side opposite the abnormal region.

Figure 98



Macular cube OCT in the same patient as in Figure 98. The ganglion cell complex is normal.

Figure 99

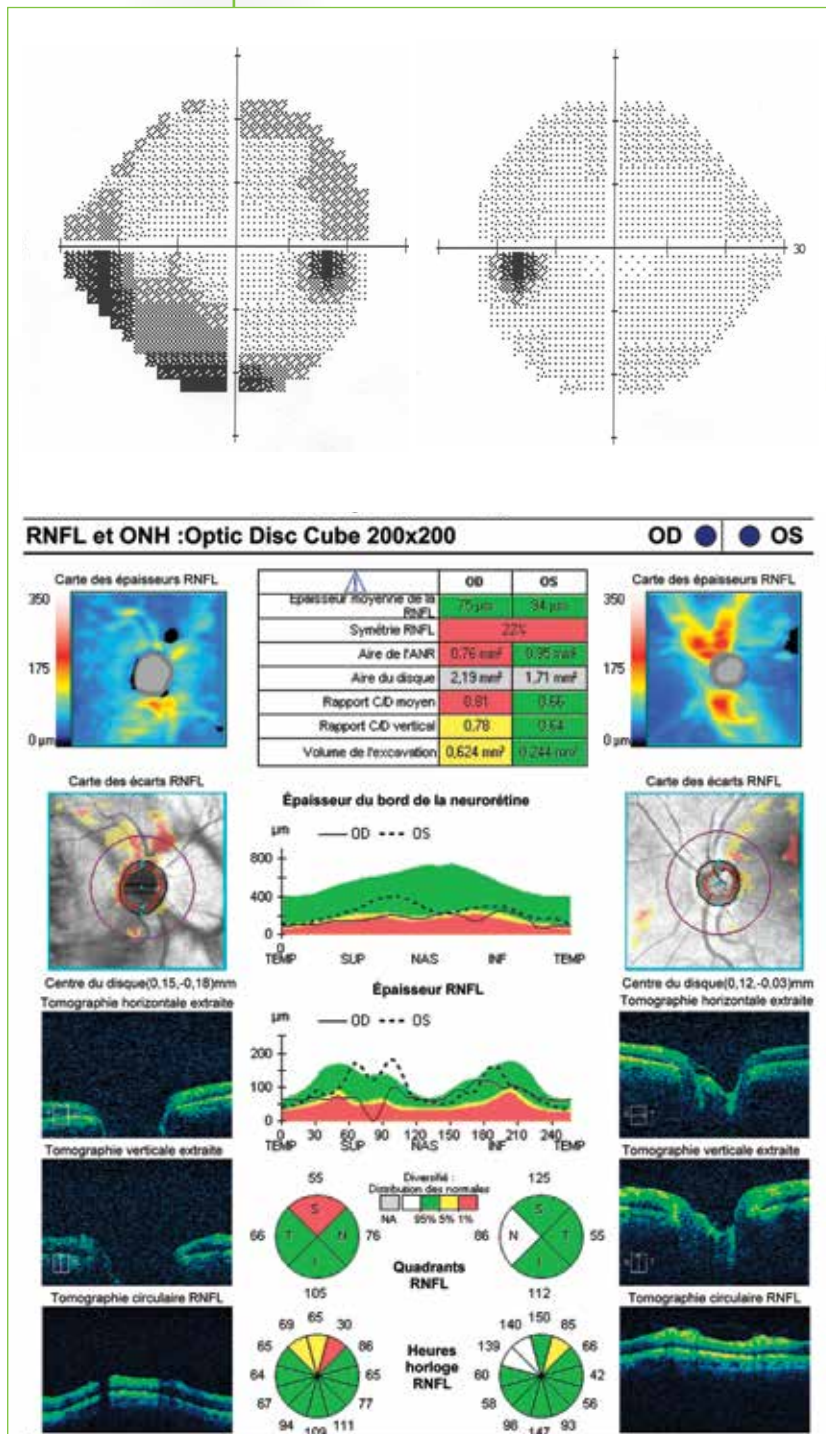
Atypical features of the retina possibly suggesting optical neuropathy

Certain macular or retinal pathologies can affect the optical fibre layer at both the macular and peripapillary levels. As a result, OCT changes in these regions do not necessarily indicate direct impairment of the optic nerve. If the initial retinal impairment mainly affects the macula, only changes in the macular ganglion cell complex may be seen in many cases. By contrast, if the impairment is more extensive, OCT changes in all structures may be seen. Two examples - vein occlusion sequelae and pigmentary retinopathy - are discussed here, but the ophthalmologist should be aware that diverse retinal pathologies may be suggestive of optic neuropathy.

Vein occlusion sequelae

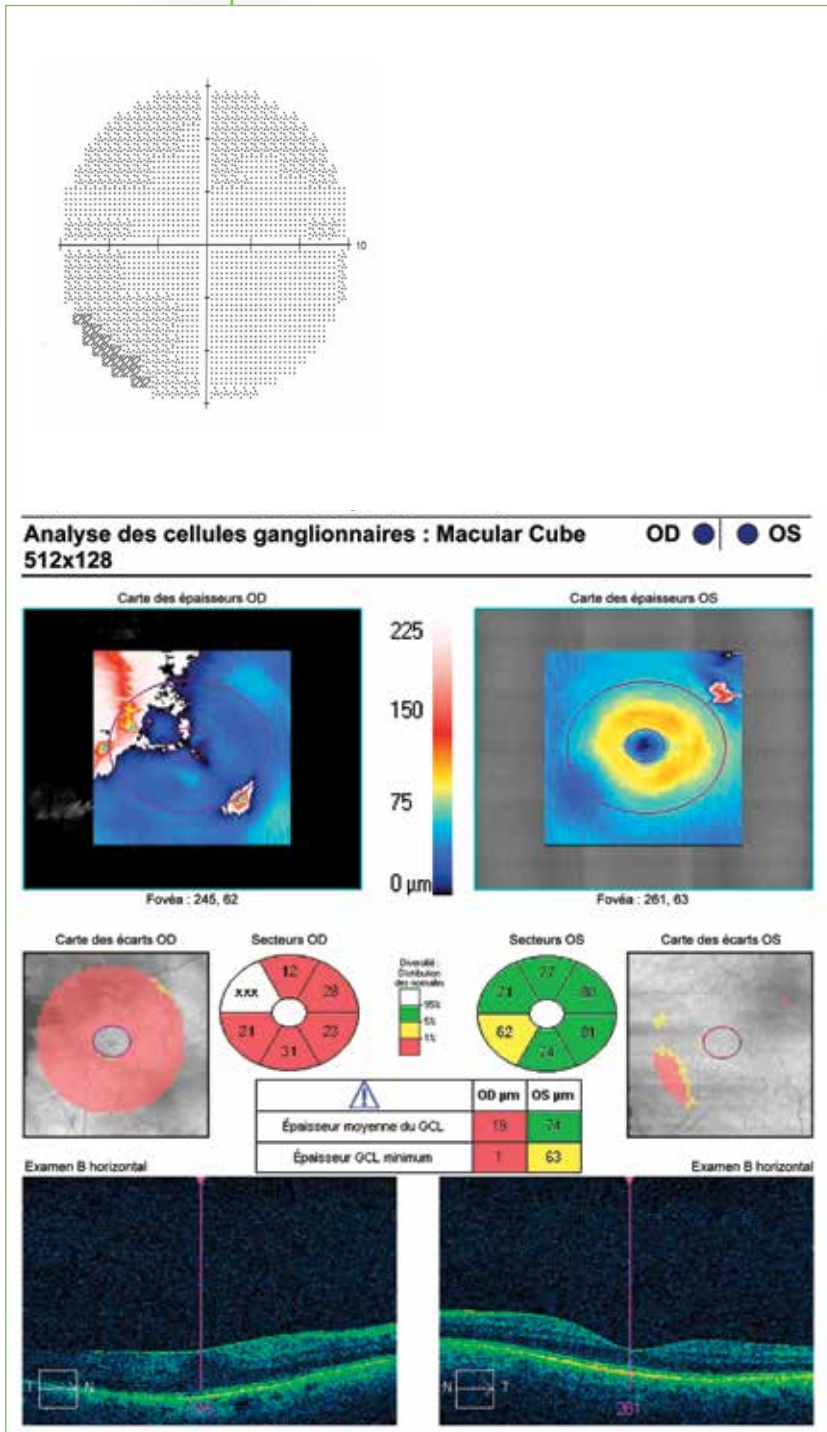
Vein occlusion results in destruction of the ganglion cell layer in addition to impairment of the optic nerve. OCT findings will depend on the clinical context.

Figures 100 and 101 show OCT findings in a patient who had experienced upper temporal branch occlusion in the right eye 3 years before examination.



OCT and visual field test results in a 72-year-old male patient who experienced upper temporal branch occlusion in the right eye 3 years previously. Corresponding impairments are seen on OCT and visual field testing.

Figure 100

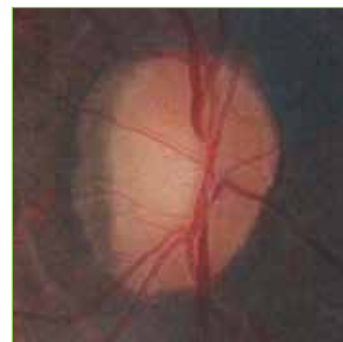
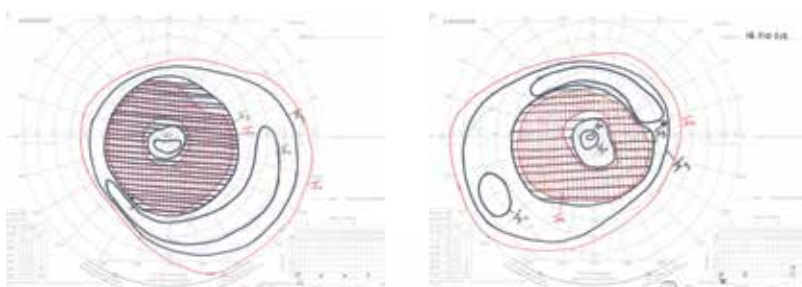


Macular cube OCT and central 10° visual fields in the same patient as in Figure 100. There is diffuse and unilateral impairment of the macular ganglion cell complex.

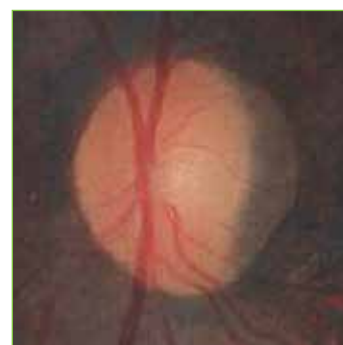Figure 101

Pigmentary retinopathy

Impairment of the macular ganglion cell complex is very common in patients with retinal pathologies. It may also be present when the initial impairment is not in the RNFL, for example, in patients pigmentary retinopathy (Figures 102 and 103).

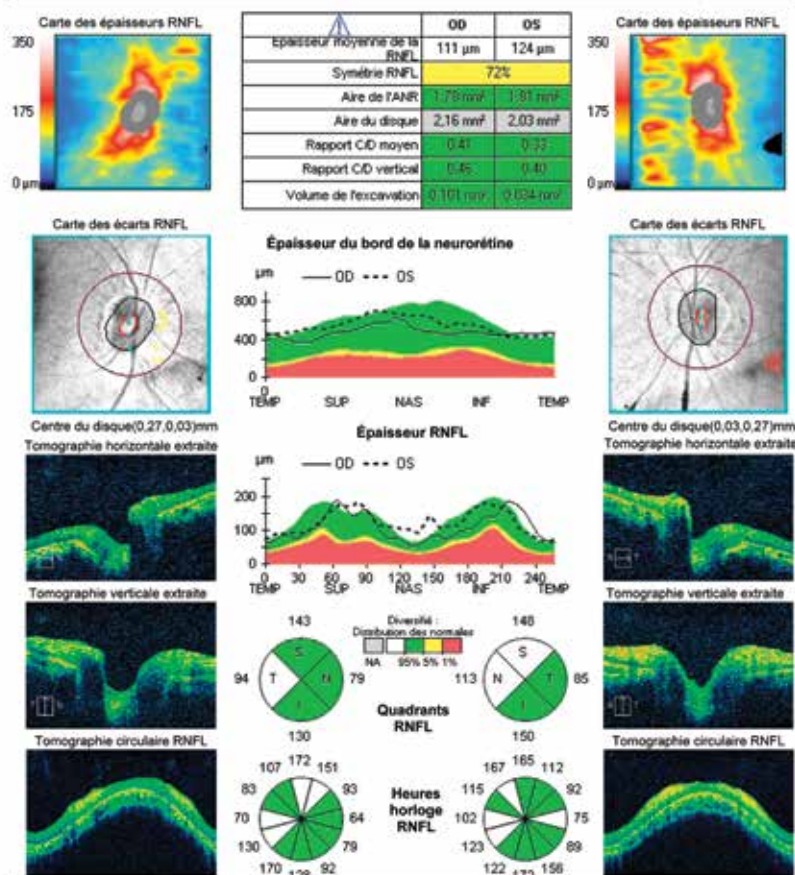


Right eye



Left eye

RNFL et ONH :Optic Disc Cube 200x200

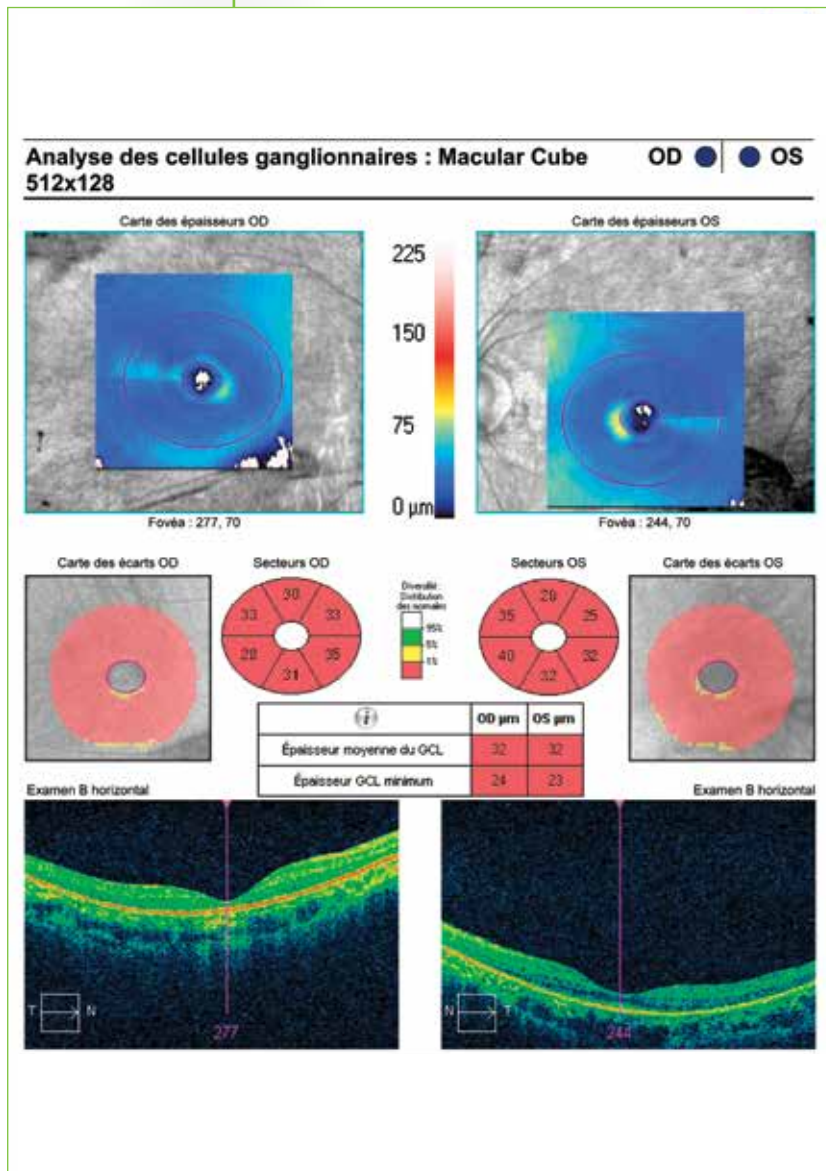


OCT and visual field test results in a 23-year- male patient with pigmentary retinopathy. Goldmann's visual field testing shows severe bilateral pericentral impairment, but the peripapillary RNFL thickness remains within normal limits

Figure 102

All other sources of macular injury can lead to impairment of the macular ganglion cell complex, including:

- epiretinal membrane
- age-related macular degeneration
- macular oedema of any origin
- acquired or constitutional maculopathies.



Macular cube OCT in the patient shown in Figure 102. There is diffuse and bilateral impairment of the macular ganglion cell complex.

Figure 103

OCT is developing constantly: in the last year, more than 300 articles on “Optic nerve and OCT” have been published in international journals, underlining the innovative character of this technology and its diverse applications in ophthalmology.

This accumulating experience has raised a number of questions. For example, should OCT be used as a basic examination in the context of glaucoma monitoring, or simply to supplement visual field testing and ocular pressure measurement? Can we ignore visual field testing, a restrictive examination that is poorly accepted by many patients? What should be done if OCT findings worsen significantly without changes in the visual field? Conversely, what should be done if the visual field deteriorates but this is not confirmed on OCT? At present, it seems reasonable to conclude that OCT has become a key examination in the investigation of glaucoma, but that it cannot replace visual field testing (particularly automated perimetry testing).

Similar questions are being asked about other optic neuropathies. Should OCT eventually replace visual field testing? And what should be done if OCT reveals signs of impairment in the absence of clinical signs?

OCT is still developing in terms of image precision and quality, and at the same time the technology is being extended to the investigation of new structures, such as the cribriform plate. Other developments are possible, in particular the ability to analyse both layer thickness and content, can be foreseen. This would be very useful, for example in counting the number of residual ganglion cells in patients with optic nerve diseases while excluding the support cells responsible for the persistence of this layer even after total destruction of the visual fibres.

Similarly, long wavelength (≥ 1000 nm) laser beams, such as those used in swept source-OCT, can be used to study structures beyond the pigmented epithelium of the retina, albeit at the cost of poorer image quality. This approach would allow visualization of the choroid and the region beyond the cribriform plate of the papilla. In the future, these technologies will provide an understanding of complex pathologies that involve both modification of peripapillary cladding structures and cribriform plate impairment.

- 1 Kara N, Altinkaynak H, Yuksel K, Kurt T, Demirok A. Effects of posterior capsular opacification on the evaluation of retinal nerve fiber layer as measured by stratus optical coherence tomography. *Can J Ophthalmol*, 47, 176-180, 2012.
- 2 Madrid-Costa D, Isla Paradelo., Ruiz J. Effect of multizone refractive multifocal contact lenses on the Cirrus HD OCT retinal measurements. *Clin Exp Optom*, 54, 212-216, 2012.
- 3 Kim NR, Lim H, Kim JH, Rho SS, Seong GJ, Kim CY. Factors associated with false positives in retinal nerve fiber layer color codes from spectral-domain optical coherence tomography. *Ophthalmology*, 118, 1774-1778, 2011.
- 4 Huang D, Chopra V, Lu AT, Tan O, Francis B, Varma R. Advanced Imaging for Glaucoma Study-AIGS Group. Does optic nerve head size variation affect circumpapillary retinal nerve fiber layer thickness measurement by optical coherence tomography? *Invest Ophthalmol Vis Sci*, 53, 4990-4997, 2012.
- 5 Shoji T, Nagaoka Y, Sato H, Chihara E. Impact of high myopia on the performance of SD-OCT parameters to detect glaucoma. *Graefes Arch Clin Exp Ophthalmol*, 136, 1843-1849, 2012.
- 6 Klamann MK, Grünert A, Maier AK, Gonnermann J, Joussem AM, Huber KK. Comparison of functional and morphological diagnostics in glaucoma patients and healthy subjects. *Ophthalmic Res*, 49, 192-198, 2013.
- 7 Mwanza JC, Oakley JD, Budenz DL, Anderson DR. Ability of Cirrus HD-OCT Optic nerve head parameters to discriminate normal from glaucomatous eyes. *Ophthalmology*, 118, 241-248, 2011.
- 8 Lisboa R, Leite MT, Zangwill LM, Tafreshi A, Weinreb RN, Medeiros FA. Diagnosing preperimetric glaucoma with Spectral Domain OCT. *Ophthalmology*, 119, 2161-2269, 2012.
- 9 Mwanza JC, Sayyad FR, Budenz DL. Choroidal Thickness in Unilateral Advanced Glaucoma. *Ophthalmol Vis Sci*, 53, 5880-5892, 2012.
- 10 Chang RT, Knight OJ, Budenz D. Sensitivity and specificity of time domain *versus* Spectral Domain OCT in diagnosing early to moderate glaucoma. *Ophthalmology*, 116, 2294-2299, 2009.
- 11 Kim CY, Jung JW, Lee SY, Kim NR. Agreement of retinal nerve fiber layer color codes between Stratus and Cirrus OCT according to glaucoma severity. *Invest Ophthalmol Vis Sci*, 53, 3193-3200, 2012.
- 12 Firat PG, Doganay S, Demirel EE, Colak C. Comparison of ganglion cell and retinal nerve fiber layer thickness in primary open angle glaucoma and normal tension glaucoma with Spectral Domain OCT. *Graefes Arch Clin Exp Ophthalmol*, 8, 225-228, 2012.
- 13 Lee JW, Lai JS, Yick DW, Yuen CY. Prospective study on retinal nerve fibre layer changes after acute episode of phacomorphic angle closure. *Int. Ophthalmol*, 32, 577-582, 2012.
- 14 Chen YC, Huang G, Kasuga T, Porco T, Hung PT, Lee R, Lin SC. Comparison of optic nerve head topography and retinal nerve fiber layer in eyes with narrow angles *versus* eyes from a normal open angle cohort - a pilot study. *Curr Eye Res*, 37, 592-598, 2012.
- 15 Leung CLS, Yu M, Weinreb R, Lai G. *et al*, Retinal nerve fiber layer imaging with Spectral Domain OCT. *Ophthalmology*, 119, 1858-1866, 2012.
- 16 Leung CK, Cheung CY, Weinreb RN, Qiu K, Liu S, Li H, Xu G, Fan N, Pang CP, Tse KK, Lam DS. Evaluation of retinal nerve fiber layer progression in glaucoma: a study on optical coherence tomography guided progression analysis. *Invest Ophthalmol Vis Sci*, 51:217-222, 2010.
- 17 Leung CLS, Yu M, Weinreb R, Lai G. *et al*, Retinal Nerve fiber layer imaging with Spectral Domain OCT. *Ophthalmology*, 119, 1858-1866, 2012.
- 18 Meideros FA, Zangwill L, Alencar LM, Bowd, C, Sample P, Suzanna R, Weinreb R. Detection of glaucoma progression with Stratus OCT retinal nerve fiber layer, optic nerve head and macular thickness measurements. *Invest Ophthalmol Vis Sci*, 50, 5741-5748, 2009.
- 19 Raghu N, Pandav SS, Kaushik S, Ichhpujani P, Gupta A. Effect of trabeculectomy on RNFL thickness and optic disc parameters using optical coherence tomography. *Eye (Lond)*, 26, 1131-1137, 2012.
- 20 Kanamori A, Nakamura M, Tomioka M, *et al*. Agreement among three types of Spectral Domain OCT instruments in measuring parapapillary retinal nerve fiber layer thickness. *Br J Ophthalmol*, 96, 832-837, 2012.
- 21 Park SC, Kiuimer S, Teng CC, Tello C, Liebmann JM, Ritch R. Horizontal central ridge of the lamina cribrosa and regional differences in laminar insertion in healthy subjects. *Invest Ophthalmol Visc Sic*, 53, 1610-1616, 2012.
- 22 Reiss AS, O'Leary N, Stanfield MJ, Shuba LM, Nicoleta MT, Chauhan BC. Laminar displacement and prelaminar tissue thickness change after glaucoma surgery imaged with optical coherence tomography. *Invest Ophthalmol Vis Sci*, 53, 5819-5826, 2012.
- 23 Park SC, de Moraes CG, Teng CC, Tello C, Liebmann JM, Ritch R. EDI-OCT of deep optic nerve complex structures in glaucoma. *Ophthalmology* 119, 3-9, 2012.
- 24 Mwanza JC, Sayyad FR, Budenz DL. Choroidal Thickness in Unilateral Advanced Glaucoma. *Ophthalmol Vis Sci*, 53, 5880-5892, 2012.
- 25 Fénolland JR, Giraud JM, May F, Mouinga A, Seck S, Renard JP. EDI-OCT et glaucome à angle ouvert : une étude préliminaire. *J Fr Ophtalmol*, 34, 313-317, 2011.
- 26 Garcia T, Tourbah A, Setrouk E, Ducasse A, Arndt C. OCT en neuro-ophtalmologie. *J. Fr Ophtalmol* 35, 454-466, 2012.

- 27 Galetta KM, Calabresi PA, Frohman E, Balcer LJ. Optical Coherence Tomography (OCT): Imaging the visual pathway as a model for neurodegeneration. *Neurotherapeutics*, 8, 117-132, 2011.
- 28 Trip SA, Schlottmann PG, Jones SJ *et al.* Retinal nerve fiber layer axonal loss and visual dysfunction in optic neuritis. *Ann Neurol* 58, 383-391, 2005.
- 29 Lamirel C, Newman NJ, Bioussé V. OCT in optic neuritis and multiple sclerosis. *Rev Neurol (Paris)*, 166, 978-986, 2010.
- 30 Burkholder BM, Osborne B, Loguidice MJ *et al.* Macular volume determined by OCT as a measure of neuronal loss in multiple sclerosis. *Arch Neurol*, 66, 1366-1372, 2009.
- 31 Oberwahrenbrock T, Schippling S, Ringelstein M. *et al.* Retinal damage in multiple sclerosis disease subtypes measured by high resolution OCT. *Mult Scler Int*, 5305, 2012.
- 32 Pineles SL, Wilson CA, Balcer LJ *et al.* Combined optic neuropathy and myelopathy secondary to copper deficiency. *Surv Ophthalmol* 55, 386-392, 2010.
- 33 Pasol J. Neuro-ophthalmic disease and optical coherence tomography: glaucoma look-alikes. *Curr Opin Ophthalmol* 22:124-32, 2011.
- 34 Aggarwal D, Tan O, Huang D, Sadun AA. Patterns of ganglion cell complex and nerve fiber layer loss in nonarteritic ischemic optic neuropathy by Fourier-domain optical coherence tomography. *Invest Ophthalmol Vis Sci*, 53, 4539-4545, 2012.
- 35 Suh MH, Kim SH, Park KH, Kim SJ, Kim TW, Hwang SS, Kim DM. Comparison of the correlations between optic disc rim area and retinal nerve fiber layer thickness in glaucoma and nonarteritic anterior ischemic optic neuropathy. *Am J Ophthalmol*, 151, 277-286, 2011.
- 36 Contreras I, Noval S, Rebolledo G. *et al.* Follow-up of non arteritic anterior ischemic optic neuropathy with OCT. *Ophthalmology*, 114, 2338-2344, 2007.
- 37 Moura FC, Costa-Cunha LV, Malta RF, Monteiro ML. Relationship between field sensitivity loss and quadrant macular thickness measured with Stratus OCT in patients with chiasmal syndrome. *Arq Bras Oftalmol*, 73, 409-413, 2010.
- 38 Jindahra P, Petrie A, Plant GT. The time course of retrograde tans-synaptic degeneration following occipital lobe damage in humans. *Brain*, 135, 534-541, 2012.
- 39 Iseri PK, Atlina O, Tokay T, Yüsel N. Relationship between cognitive impairment and retinal morphological and visual function abnormalities in Alzheimer disease. *J Neuro-Ophthalmol*, 26, 18-24, 2006.

Edition

Published by:
Laboratoire Théa
12, rue Louis Blériot
63000 Clermont-Ferrand - France
Tel: 04 73 98 14 36

Carl Zeiss Meditec France SAS
100, route de Versailles - France
78160 Marly-le-Roi
Tel: 01 34 80 21 00